

A Comparative Study between the Outcome of Laparoscopic Repair and Open Repair of Paediatric Inguinal Hernia

Tahmina Hossain^{1*}
Sharifuzzaman²
Kaniz Hasina¹
Ashraf Ul Huq¹

¹Department of Paediatric Surgery
Dhaka Medical College Hospital
Dhaka, Bangladesh

²Thana Health Complex, Monirampur
Jessore, Bangladesh

Abstract

Purpose: Inguinal hernia is one of the commonest conditions in paediatric surgical practice that requires surgical repair. Open repair is a conventional procedure. With the advance of minimally invasive surgery, laparoscopic repair of childhood inguinal hernia has been attempted. Now many centres practice it routinely. From different studies, reported advantages are excellent visual exposure, minimal dissection, and thus fewer trauma to the inguinal canal and its content, detection, and repair of contralateral hernia (if present) in same setting, less post-operative pain, early recovery, and better cosmesis. To date, despite increased interest in laparoscopic repair, there is no published study focusing on paediatric inguinal hernia in Bangladesh. So the present study is designed to assess the above mentioned clinical benefits of this method and to compare the laparoscopic repair and open repair of paediatric inguinal hernia. **Materials and Methods:** This prospective comparative interventional study was carried out in the Department of Paediatric Surgery, DMCH, Dhaka, during the period of May 2009 to June 2012. Total 60 patients were included in this study. Among them 30 patients in Group-L were repaired by laparoscopic procedure and another 30 patients in Group-O were repaired by open procedure. Both groups were followed-up for 3 months. The early post-operative complications were almost same and there was no recurrence in any groups. **Results:** It was found that laparoscopic repair is superior to open repair with regards to early pain relief and cosmesis. Moreover, on laparoscopy, detection of contralateral hernia or contralateral patent processus vaginalis and repair is possible in the same setting. **Conclusions:** Laparoscopic repair is superior with regard to early pain relief and cosmesis, but needs to be evaluated on wider group of patients and long period of follow-up.

Key words: Inguinal hernia; Laparoscopic hernia repair; Inguinal hernia in children.

INTRODUCTION

Inguinal hernia (IH) is one of the commonest conditions faced in paediatric surgical practice. The hallmark of an inguinal hernia in a child is a groin bulge, extending towards the top of scrotum, which is visible most frequently during periods of increased intra-abdominal pressure e.g., crying, straining etc. A true IH will not resolve spontaneously, so surgical closure is always indicated.

Modern hernia surgery began in the 19th century when an accurate understanding of the anatomy of the inguinal canal became available. In 1912, Turner

Correspondence to:

Dr. Tahmina Hossain
Assitant Professor
Department of Paediatric Surgery
Dhaka Medical College Hospital
Dhaka 1000
Bangladesh
Cell: +88-01711533684
E-mail: tahminahrahman@yahoo.com

documented that high ligation of sac was the only procedure necessary in most children.¹

Owing to advances in paediatric laparoscopic instrumentation and increased experience with the technique of laparoscopy, a number of centre routinely perform laparoscopic inguinal hernia repair in children. Now this procedure is more feasible, less invasive, and less painful. Moreover an advantage of this procedure is that, it allows detection and repair of the contralateral hernia in same setting.^{2,3}

In our study we planned to find out the outcome of laparoscopic repair of inguinal hernia in terms of pain relief and cosmesis, in the paediatric age group.

MATERIALS AND METHODS

This was a prospective, comparative, interventional study carried out in the Department of Paediatric Surgery of Dhaka Medical College Hospital from May 2009 to June 2012 (36 months).

Our hypothesis was “the outcome of laparoscopic repair of paediatric inguinal hernia is superior to open repair.” General objective was to compare the outcome of laparoscopic repair and open repair of paediatric inguinal hernia. Specific objectives were to detect and compare the amount of analgesics for post operative pain and wound appearance score of post operative scar in laparoscopic and open repair of paediatric inguinal hernia; to find out the advantage of detecting and repairing the contra lateral hernia in same setting in laparoscopic procedure.

Ethical clearance was taken from the ethical committee of Dhaka Medical College. Sixty patients with indirect inguinal hernia, from 2 to 14 years of age, were included for this study and informed written consents were obtained from their parents or legal guardians after proper counseling. Patients with recurrent hernia or history of previous abdominal surgery were not included in the study population. Patients with odd numbers were selected for laparoscopic repair (Group-L) and those with even numbers were selected for open repair (Group-O). Data was collected from preoperative interview and clinical examination, per operative and post operative hospital records and post operative interview during follow up. All were recorded in structured data sheet. Statistical analysis was performed using the Statistical Package for Social Science (SPSS) version 15.0. A descriptive analysis was performed for clinical features. Numerical data were analyzed by using t-test and categorical data were expressed as % and compared between groups by chi-square (χ^2) test. P-value < 0.05 was considered significant. The respective data

were presented in appropriate table as required. The two variables used were—pain relief (determined by amount of analgesics used) and cosmesis (determined by VAS).

Some investigations were done for pre anaesthetic check up of the patients: Blood for TC, DC, Hb%; BT, CT (in selected cases); X-ray chest PA view.

Operative Procedure

Both laparoscopic and open repair were performed under general anaesthesia.

In Group-L (**laparoscopic repair**): After completing all the surgical rituals, a 5-mm umbilical port was made by open procedure and pneumoperitoneum was created with inflation of Carbon dioxide keeping the pressure within 8–10 mm Hg. A 30° telescope with camera was then introduced into the abdominal cavity through this port and the patency of processus vaginalis through internal inguinal ring of affected side was detected. Under direct vision of the telescope two 5 mm working ports were introduced through left and right lower abdomen. Needle holder and Maryland forceps were introduced through these ports. A 3-0 vicryl with cutting body needle was then introduced into the abdominal cavity directly piercing the abdominal wall. After reducing the sac content (if present) with the help of forceps, purse-string suture around the internal ring was applied by manipulating the working instruments. Intracorporeal knot was made and patent processus vaginalis was closed by tightening the knot (Figures 1 & 2). Further reinforcing knots were also given. Contralateral side was inspected for patency of the processus vaginalis and if present, was repaired in the same procedure described above. All ports were then removed, gas was squeezed out, port wounds were closed by subcuticular

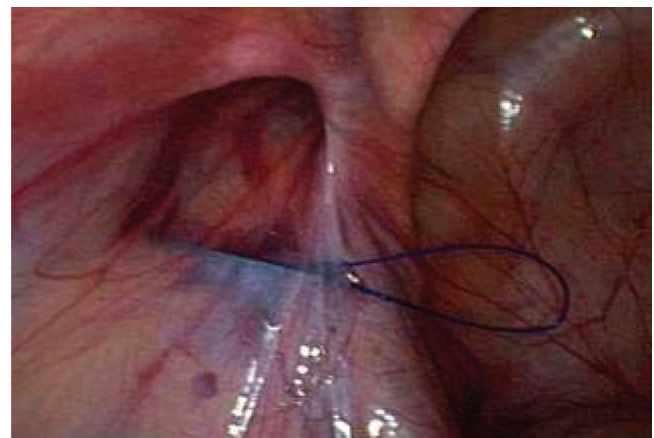


Figure 1: Commencement of purse-string suture during laparoscopic repair.

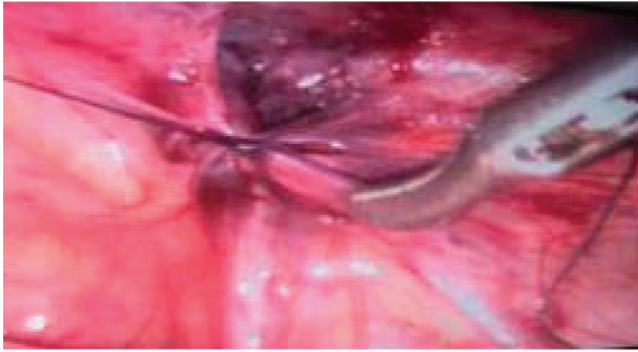


Figure 2: Intracorporeal closure of hernia sac at deep inguinal ring.

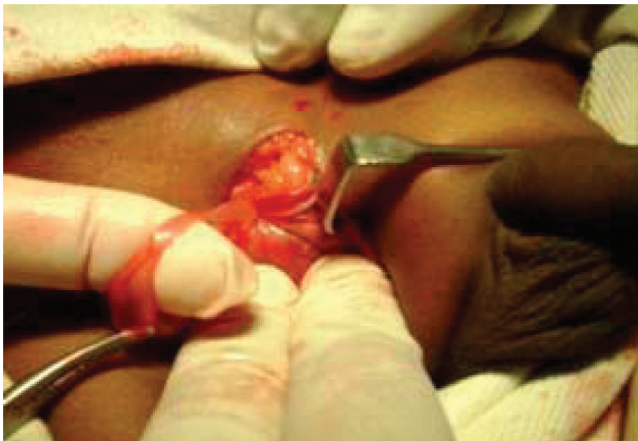

Figure 3a: Dissection of hernia sac during open procedure.

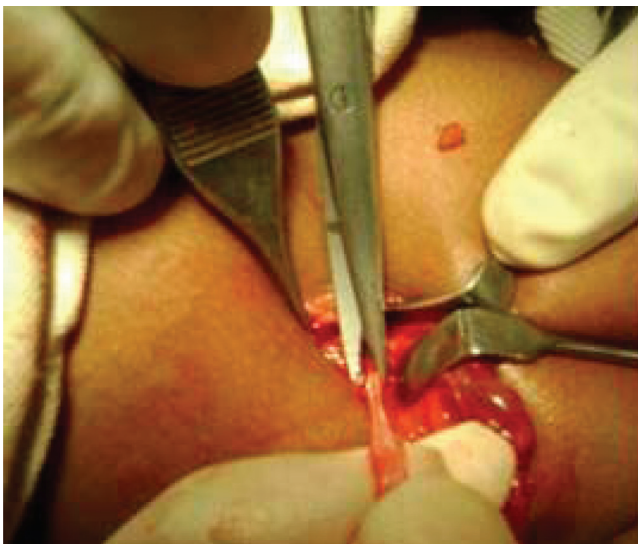

Figure 3b: Excision of hernia sac.

suture with 3-0 or 4-0 vicryl. Sterile dressings were then applied.

In Group-O, (**Open repair**): After painting and draping of lower abdominal wall, a lower abdominal skin crease incision was made on the affected side, started just lateral to the pubic tubercle. After dissecting fascia of Camper, fascia of Scarpa and external oblique aponeurosis from superficial to deep direction, the cremasteric muscle and fascia was swiped out by blunt dissection with forceps. Hernial sac was identified anteromedial to the spermatic cord. It was carefully separated from testicular vessels and vas deferens (in case of male) by blunt dissection. The sac was dissected proximally up to internal inguinal ring indicated by appearance of extra peritoneal fat (Figure 3a). High ligation of neck of the sac was done at the level of the internal ring with 3-0 or 4-0 vicryl and was excised distal to the knot (Figure 3b). Redundant portion of sac was excised out if it was small enough or it was left in place if it was big. Inadvertent dissection of big distal portion of sac may result in scrotal hematoma. The wound was closed in layers. Skin was closed by subcuticular suture with 3-0 or 4-0 vicryl. Sterile dressing was applied.

All the cases, both open and laparoscopic repair, were performed as day care surgery and the patients were allowed to go home 4–6 hours after the procedure when he/she became well oriented and stable. Patients were followed up at 1st week, 1st month, 2nd month, and 3rd month.

RESULTS

Total 60 patients of indirect inguinal hernia were divided in 2 groups:

- Group-L, (Laparoscopic repair, odd number), (n = 30).
- Group-O, (Open repair, even number) (n = 30).

During this study period in the present series following observations were noted, which are tabulated in the following tables.

Majority of the patients were 5–10 years of age in both groups.

Total 53 patients of this series were male and 7 were female, among them in Group-L, out of 30 patients 26 were male and the rest were female, in Group-O out of 30 patients 27 were male and the rest were female.

In group-L, among 30 patients right-sided hernia were 21, left-sided hernia were 5 and 4 were bilateral. These bilateral hernias were started to repair as right sided disease, but laparoscopy detected the contra lateral sides and repaired.

Table 1: Age distribution of patients

Age (years)	Group O		Group L		P value ^a
	Open repair (n = 30)	(%)	Laparoscopic repair (n = 30)	(%)	
≤5	10	33.3	5	16.7	0.139 ^{ns}
5–10	17	56.7	17	(56.7)	
>10	3	10.0	8	(26.7)	
					P value^b
Mean ± SD	6.93 ± 2.92		8.42 ± 3.07		0.060 ^{ns}
Range	2.0–13.0		2.5–14.0		

^aChi-square test; ^bUnpaired student's 't' test; ns = Not significant.

Table 2: Sex distribution in two groups of patients

Sex	Group-L		Group-O		Total	
	n	%	n	%	n	%
Male	26	86.67	27	90	53	88.33
Female	4	13.33	3	10	7	11.67
Total	30	100	30	100	60	100

Table 3: Side distribution in two groups of patients

	Group-L		Group-O		Total	
	n	%	n	%	n	%
Right	21	70	19	63.33	40	66.67
Left	5	16.67	8	26.67	13	21.66
Bilateral	4	13.33	3	10	7	11.67
Total	30	100	30	100	60	100

In group-O, among 30 patients right-sided hernia were 19, left-sided hernia were 9 and bilateral were 2.

Patients with CHEOPS ≥ 4 were given specified doses of Diclofenac Sodium, 1.5 mg/kg/dose per rectal.

Patients required less doses of analgesics for post operative pain control after having laparoscopic repair.

Patients who had undergone laparoscopic repair had better cosmetic result.

DISCUSSION

This was a study of paediatric hernia repair to compare laparoscopic with open methods by conducting a prospective study at a single institution. Multi centre studies entail a certain failure rate because of the bias of the surgeon and variations in the level of surgical expertise across centres,⁵ whereas single-centre trials have the advantages of clearly

Table 4: Comparison of mean operative time between the study subjects

Operative time (min)	Open repair	Laparoscopic repair	P value
Unilateral inguinal hernia	(n = 27)	(n = 26)	
Mean ± SD	35.07 ± 5.14	46.92 ± 4.23	0.0001***
Range	25.0–45.0	40.0–55.0	
Bilateral inguinal hernia	(n = 3)	(n = 4)	
Mean ± SD	70.00 ± 5.00	63.00 ± 2.45	0.055 ^{ns}
Range	65.0–75.0	60.0–65.0	

ns = Not significant; *** = Significant at p < 0.001

Table 5: Children's Hospital-of-Eastern Ontario Pain Score (CHEOPS)⁴

	0	1	2
Crying	None	Moaning/Crying	Screaming
Facial expression	Smiling	Composed	Grimace
Verbal expression	Positive	None/ other complaints	Complaints of pain
Torso	Neutral	Shifting/tense/ upright	Restrained
Legs	Neutral	Squirming/kicking/ draw-up	Restrained

defined procedures and uniform postoperative care and analgesia.⁶ The study on 60 patients was adequate to show a statistical difference.

For laparoscopic repair of inguinal hernia, laparoscopic suturing and knot tying are becoming integral part of the

Table 6: Comparison of mean doses of Diclofenac Sodium

	Open repair (n = 30)	Laparoscopic repair (n = 30)	P value
Mean \pm SD	4.30 \pm 0.70	2.43 \pm 0.94	0.0001***
Range	3.0–6.0	1.0–4.0	

Unpaired Student's 't' test; *** = Significant at $p < 0.00$

Table 7: Comparison of mean wound appearance score (VAS: Visual Analog Score) between the study groups

VAS	Open repair (n = 30)	Laparoscopic repair (n = 30)	P value
Mean \pm SD	75.67 \pm 6.12	90.00 \pm 5.25	0.0001***
Range	65.0–85.0	80.0–100.0	

Unpaired student's 't' test; *** = Significant at $p < 0.001$

Table 8: Comparison of Complications in two study groups

Complications	Group-O (n = 30)	Group-L (n = 30)
Port site hematoma	0	2
Stitch abscess	2	1
Skin sensitivity to dressing	1	2
Post operative vomiting	2	1
Transient hydrocele	1	1

There were minimum post operative complications in both groups. No recurrence noted in either group during study period.

skill that any laparoscopic surgeon must acquire. Intracorporeal suturing and knot tying for closure of the inguinal hernia may need a long learning curve.⁷

For paediatric hernias, high ligation of the hernia sac is all that is required for correction.⁸ In normal situations, recurrence after an open procedure may be attributed to a failure to ligate the sac high enough at the internal ring, injury to the floor of the inguinal canal due to operative trauma, failure to close the internal ring in girls, or postoperative wound infection and hematoma.⁹ Our laparoscopic tech-

nique for the repair of IH has proven to be a safe method, when performed carefully it can prevent or avoid all these possible causes of recurrence.³ No recurrences were found in any of our group L patients after a mean follow-up period of 3 months. Our group O had no recurrences either.

The three-port technique of the LR enables the repair of bilateral hernias. Insertion of the three ports takes some extra time, so for cases of unilateral hernia, group L had a longer operative time than the group O. However, comparatively less time was required for repairing bilateral hernia in group L, as no extra time for instrumental setting was required.

Laparoscopic hernia repair resolves the question of whether contralateral exploration is necessary in children with IH.¹⁰ The rate of contralateral patent processus vaginalis repair in our patients was 13.33%. One may argue that not all cases of patent processus vaginalis will develop into hernias. Open repaired patient presenting with unilateral hernias were found on follow-up to have developed contralateral hernias. Because these patients had been treated with open technique, rather than laparoscopically, there was no knowledge or treatment of the contralateral side. The number of contralateral hernias in this group may increase further with time because paediatric inguinal hernia is the result of a patent process vaginalis. Though the rate of detecting contralateral patent processus vaginalis was significantly low ($p < 0.001$) in this study conducted with a small sample, in a large sample study it would be significant and be established as an excellent advantage of this procedure.

Objective behavioural and physiological parameter scoring systems, CHEOPS (Children's Hospital-of-Eastern Ontario Pain Score) 4 was used in the present study. Patients with CHEOPS ≥ 4 were given specified doses of Diclofenac Sodium, 1.5 mg/kg/dose per rectally, and the dose was repeated every 8 hours, if necessary. Group L required significantly less amount of analgesics than group O, indicating that laparoscopic repair was less painful. The parents' assessments also indicated that the children recovered faster in the group L.

The scoring system for wound appearance used in this study was Visual Analog Scale (VAS). Parents of the patients were explained and demonstrated about worst possible scar and almost normal skin and were asked to score 0 and 100, respectively, for these two extreme and other possible scores for wound appearance in between these. Most of the parents of the patients in the group L gave excellent scores to their children's wound cosmesis according to Visual Analog Scale; this percentage was significantly higher than that for the group O patients.

Wound complications were minimal in both groups.

All the cases were operated as day care surgery without any difficulty.

Limitations

1. Operative cost of laparoscopic repair of hernia is much more due to costly instrumental set up, so people of low socio-economic class of developing country like Bangladesh could hardly afford it.

2. Special expertise is required for laparoscopic repair. So, lack of adequate manpower in surgical team was a problem (e.g., increased operative time, increased rate of post operative complications etc.)

3. It was difficult for the patients of remote areas to come for follow-up in regular interval. So, duration of follow-up became short and sometimes not up to the mark.

CONCLUSION

In paediatric patients with IH, the outcome of laparoscopic repair is superior to open repair with regard to postoperative pain, recovery, and cosmesis. Laparoscopic hernia repair also enables the detection of contralateral hernias so that they can be repaired in the same operative setting but needs to be evaluated on wider group of patients and longer follow-up.

References

1. Scott A, Engum JL, Grosfeld MD. Hernias in children. 6th ed. Operative pediatric surgery. Oxford University Press: Edward Arnold Publishers; 2006. p. 237–57.
2. Cheung TT, Chan KL. Laparoscopic inguinal hernia repair in children. *Ann Coll Surg.* 2003;7(7):94–6.
3. Chan KL, Tam PKH. A safe laparoscopic technique for the repair of inguinal hernias in boys. *J Am Coll Surg.* 2003;196:987–9.
4. McGrath PJ, Johnson G, Goodman JT. CHEOPS: a behavioral scale for rating postoperative pain in children. *Pain Res Ther.* 1985;9:395–402.
5. Ehrlich PF, Newman KD, Haase GM, Lobe TE, Wiener ES, Holcomb GW. Lessons learned from a failed multi-institutional randomized controlled study. *J Pediatr Surg.* 2002;37:431–6.
6. Majeed AW, Troy G, Nicholl JP. Randomised, prospective, single-blind comparison of laparoscopic versus small incision cholecystectomy. *Lancet.* 1996;347:989–94.
7. Shalaby R, Ahmed D. Needlescopic inguinal hernia repair in children. *Pediatr Surg Int.* 2002;18:153–6.
8. Skoog SJ, Conlin MJ. Pediatric hernias and hydroceles. *Urol Clin North Am.* 1995;22:119–30.
9. Grosfeld JL, Minnick K, Shedd F, West KW, Rescoria FJ, Vane DW. Inguinal hernia in children: factors affecting recurrence in 62 cases. *J Pediatr Surg.* 1991;26:283–7.
10. Surana R, Puri P. Is contralateral exploration necessary in infants with unilateral inguinal hernia? *Indian Journal of Pediatric Surgery.* 1993; 28:1026–7.