

'Invasion of Meningioma Cell in Bony Hyperostosis- an Observational Study of 34 Cases'

A. M. REJAUS SATTER¹, K. A. TALHA², FARZANA RASHID³, FARHANA SELINA⁴, MD. MAMUN KHAN⁵, A T M MOSHAREF HOSSAIN⁶, ABDUL KADER SHAIKH⁷.

Abstract:

Background: Meningiomas are usually globular encapsulated tumors. They are extra axial tumors attached to dura and compress the underlying brain without invading it. Abnormalities of bone are frequently encountered in Meningiomas. Hyperostosis or endosostosis are certainly more common than destruction of bone. Aims and Objective: Aim of study was to observe the percentage of tumour cell invasion in to the hyperostosis part of intracranial meningiomas. **Materials and methods:** This is an observational analytic study. Sample size was 34. Place of study was department of Neurosurgery of Square Hospitals Ltd. All the patients with the histological diagnosis of meningioma were included in to this study. **Result:** Female patients were predominant. Highest number of patients was from 41 to 50 years age group. Convexity meningiomas were commonest (35%) followed by parasagittal meningiomas. According to histopathological subtype meningothelial was commonest (56%) followed by psammomatous. About one fourth meningioma patients (26.47%) presented with hyperostosis. Among the hyperostosis patients in 44.44% patient's cause of hyperostosis was due to tumour cell invasion into hyperostosis part. **Conclusion:** Tumour cell invasion is one of the causes of hyperostosis in intracranial meningiomas which was responsible in more than one third cases in this study.

Key words: Hyperostosis, tumour cell invasion, meningioma.

Introduction:

Meningiomas are usually globular encapsulated tumors. They are extra axial tumors attached to dura and compress the underlying brain without invading it. Even though invasion of dura and dural sinuses are common in meningiomas, they are usually separated from the pia mater. Meningiomas are defined as neoplasm composed of meningothelial cells originating from arachnoid cap cells¹.

Meningiomas can occur in any age groups. Its incidence increases with age and occur mainly in middle age and old age. The peak incidence is around 45 years. In adult meningiomas shows female predominance at a ratio of male : female = 1 : 1.4¹.

Abnormalities of bone are frequently encountered in Meningiomas. But it is very difficult to appreciate the exact frequency of bony reaction and / or invasion, because very few series mention this particular aspect. Hyperostosis or endosostosis are certainly more common than destruction of bone, and were found in 25% of Cushing cases². Sosman and Putnam reported Roentgenological "osteomatous change" in 49% of their cases³.

An extensive Hyperostosis can occur with a small Meningeal tumor, a fact already pointed by Cushing, who separated hyperostosing 'en plaque' Meningiomas from bone alterations accompanying 'global' or 'en mass' Meningiomas.

-
1. Specialist, Neurosurgery, Square Hospitals Ltd.
 2. Consultant, Neurosurgery, Square Hospitals Ltd.
 3. Asst. Registrar, ICMH, Dhaka
 4. Specialist Anesthesiology, Square Hospitals Ltd.
 5. Clinical staff, Neurosurgery, Square Hospitals Ltd.
 6. Professor of Neurosurgery, BSMMU
 7. Asst. Prof. Neurology, BSMMU

Several theories have been put forward by Patrick J. Derome & A. Visot of department of Neurosurgery of FOCH hospital, Suresnes Cedex, France to explain bone formation and/or destruction. Slight movement of sagittal suture and bregma, including a stimulating effect on the cells of pachymeninges, explain the frequency of hyperostosing en mass meningiomas in the parasagittal area⁴. In vascular theory, a disturbance of circulation in the bone, subsequent to presence of meningioma, is responsible for hyperostosis⁵. Phemister and others suggested that the meningioma irritates the periosteum, leading to osteoblastic proliferation which leads to hyperostosis⁶. Finally, Freedman and Forster demonstrated that “the tumor cells themselves take an active part in the production of the hyperostosis is rather than acting only as relative foreign bodies to stimulate bone growth; tumor cells of meningiomas can produce fibroblasts, osteoblast and osteoclasts or act as the latter two without apparent morphological alteration⁷.”

Diagnosis of a hyperostosing meningioma is easily made by computerized tomography (CT) scan of brain (Fig.-1) and magnetic resonance imaging (MRI) of brain. Plain X-rays, tomography and CT scan allow the surgeon to determine the boundaries of bone involvement with relative accuracy.

Materials and methods:

This is an observational analytic study titled ‘invasion of meningioma cell in bony hyperostosis- an observational study of 34 cases’. Study place was neurosurgery department of Square Hospitals Ltd. Total number of cases were 34 (N=34). All the patients with the histological diagnosis of meningioma were included in to this study. Patients who didn’t consented to be included or histological diagnosis other than meningioma were not included. Study period was May 2007 to April 2010.

Aim of this study was to observe the percentage of tumour cell invasion in the bony hyperostosis in intracranial meningioma patients.

After confirmation of diagnosis as meningioma, patient’s data were collected by questionnaire. Meningioma was confirmed by histopathology report and hyperostosis of bone was confirmed by CT

scan of brain and intra-operative findings. Hyperostosis area of bone was drilled out and was sent for histopathology to confirm presence of meningioma cell in it.

All questionnaires were collected at the end of data collection and were tabulated according to different parameters. Study results were also compared with those of other studies.

Results:

This is an observational analytic study titled ‘invasion of meningioma cell in bony hyperostosis- an observational study of 34 cases’. Total number of cases was 34. Data were tabulated according to different parameters.

Table-I
Distribution according to sex (N=34)

Sex	No. of case	percentage	Ratio
Male	13	38%	1 : 1.6
Female	21	62%	

Table-I shows the distribution according to sex. Most of patients were female. They were 62% of total cases. Male is to female ratio was 1 : 1.6

Table-II
Distribution according to age group (N=34)

Age frequency (years)	No. of case	Percentage
< 20	00	00%
21- 30	01	2.9%
31-40	09	26.5%
41-50	12	35%
51-60	07	21%
>60	05	14.7%

Table-II demonstrates the distribution patients according to age group. Highest number of patients was from 41 to 50 years age group. They were 35% of all patients. Near about one fourth patients were from 31 to 40 years age group. Next common was 51 to 60 years age group followed by more than 60 years age group. There was only one patient in 21 to 30 years age group.

Table- III
Distribution according to location (N=34)

Location of meningioma	No. of case	percentage
Convexity	12	35%
Parasagittal	08	21.5%
Sphenoid wing	05	14.7%
Tentorial	01	2.9%
Petroclival	02	5.8%
Suprasellar	02	5.8%
Olfactory groove	03	8.8%
Falcine	01	2.9%

Table-III presents distribution of all patients according to the location of meningiomas. More than one third patients were operated for convexity meningiomas. Second highest was parasagittal meningiomas which was 21.5% of all meningiomas. Number of sphenoid wing meningiomas was 5. Other locations were tentorial, petroclival, suprasellar, olfactory groove and falcine.

Table-IV
Distribution according to histopathology subtype (N=34)

Histological subtype	No. of case	percentage
Meningiothelimatous	19	56%
Psammomatous	05	14.7%
Atypical	04	11.7%
Angiomatous	04	11.7%
Transitional	01	2.9%
Malignant	01	2.9%

Table-IV illustrates the distribution of all meningiomas according to their histopathological subtypes. More than half (56%) meningiomas were of meningiothelimatous subtype. Psammomatous subtype was 14.7%. Number of atypical and angiomatous subtypes was same and they were 11.7% of total cases. Transitional and malignant subtypes had only 1 case in each group.

Table-V
Distribution according to hyperostosis and tumour cell invasion

Number of case	No. of hyperostosis	Percentage of hyperostosis	Number of cases of tumour cell invasion	Percentage of cases of tumour cell invasion
34	09	26.47 %	04	44.44 %

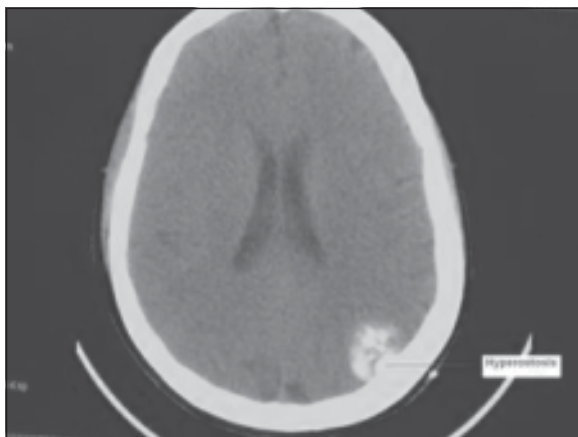


Fig.-1: CT scan shows meningioma with bony hyperostosis.jpg

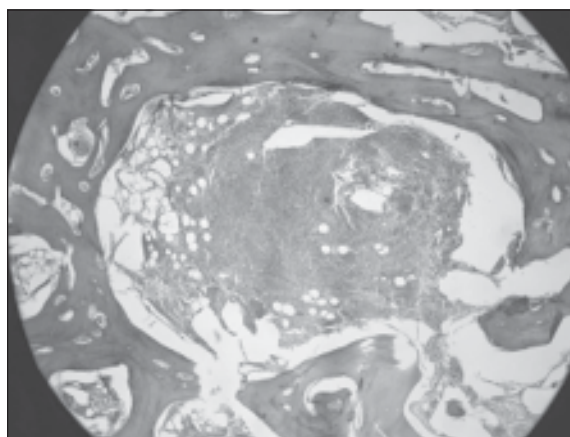


Fig.-2: Histopathological slide shows meningioma cell inva.jpg

Table-V shows the distribution of all 34 patients according to bony hyperostosis and tumour cell invasion in the hyperostosis area. About one quarter (26.47%) meningioma presented with bony hyperostosis. Among 9 hyperostosis patients tumour cell invasion was observed in 4 cases. That means 44.44% of bony hyperostosis was due to tumour cell invasion.

Discussions:

This study was performed to observe the percentage of tumour cell invasion into hyperostosis part of intracranial meningioma. Total number of cases was 34.

Bony reaction is a very important clinical presentation for intracranial meningiomas. Sosman and Putnam found 49% hyperostosis cases in their series³. Cushing and Eisenhardt found 25% hyperostosis cases in their series⁶. Their study was performed in pre-CT scan time, so confirmation of hyperostosis was done only by X-ray and intra-operative findings. According to the study of Balasubramaniam et al they had 17.3% of cases presented with bony reaction⁸. In our series hyperostosis was confirmed in 26.47% of cases. Diagnosis of hyperostosis was made on the basis of CT scan, intra-operative findings and histopathology, but due to early diagnosis of meningioma and short waiting time for surgery number of hyperostosis cases may be less than other studies. More than one fourth intracranial meningioma patients presented with hyperostosis.

Study on relationship between bony reaction and age group are very few in number. Guthrie et al distributed hyperostosis cases according to age group⁹. He found that in adult cases 44% of cases were presented with hyperostosis. In our study, all patients were adult to old age group and there was no pediatric age group patient and percentage of patients presenting with hyperostosis was 26.47%.

Pieper et al reported their study on 51 patients with hyperostosis. They found tumour cell invasion in 69% of cases. That means histological examination of the resected bone showed tumor invasion in 35 patients⁵. In our study tumour cell invasion in hyperostosis was observed in 44.44% cases.

There are three types of meningiomas according to malignancy grades: benign (WHO grade I), atypical (WHO grade II), and anaplastic (malignant; WHO grade III) meningiomas. About 80% of all meningiomas are slow-growing tumours of WHO grade I. Any histological variant is compatible with WHO grade I, except for the chordoid, clear-cell, papillary, and rhabdoid meningiomas, which are consistently associated with more aggressive clinical features. The histological variants most commonly diagnosed in pathology specimens are meningothelial, fibrous, and transitional meningioma. Atypical meningiomas constitute 15–20% of meningiomas. Atypical, clear cell and choroid meningiomas are under WHO grade II. Anaplastic meningiomas account for 1–3% of all

meningioma cases. Apart from anaplastic meningiomas rhabdoid and papillary meningiomas are also malignant meningiomas under WHO grade III¹⁰.

According to the study of Jellinger et al meningothelial and transitional forms constituted 71.5% of intracranial tumors, fibroblastic forms 7.5% and highly vascularized meningiomas 5.2% of the intracranial tumors, while true “angioblastic” meningiomas (hemangioblastomas and hemangiopericytomas) amounted 3.1% of the intracranial meningiomas, 1.2% were “atypical” (so-called malignant) meningiomas¹¹. According to this study meningothelial and transitional forms constituted 58.9% of all meningiomas. Angiomatous and atypical subtypes were confirmed in 11.7 % cases respectively.

When the results of this study were compared with those of other studies a fair similarity was observed. There were few limitations of this study; study sample was not very large and comparison was done by significant test.

Conclusion:

In summary it can be said that tumour cell invasion is one of the cause of hyperostosis in intracranial meningiomas which was responsible in more than one third cases in this study.

References:

1. Chau SM, Miles JM. The pathology of meningiomas. In: Al- Mefty O, ed. Meningiomas. New York: Raven Press, 1991: 37 – 56.
2. Cushing H, Eisenhardt L. Meningiomas, their classification, regional behavior, life history and surgical end result. In: Thomas CC, ed. Meningioma. Illinois: Springfield, 1938: 785.
3. Sosman MC, Putnam TJ. Roentgenological aspects of brain tumors– meningiomas. Am J Roentgenol 1925; 13: 1- 12.
4. Patrick J, Visot DA. Bony reaction and invasion in meningiomas. Meningiomas 1991; 169-178.
5. Pieper DR, Al-Mefty O, Hanada Y, Buechner D. Hyperostosis associated with meningioma of the cranial base: secondary changes or tumor invasion. Neurosurgery 1999; 44(4): 742-6.
6. Phemister DB. The nature of cranial hyperostosis overlying endothelioma of meninges. Arch Surg 1923; 6: 554 – 72.
7. Freedman H, Forster F. Bone formation and destruction in hyperostoses associated with meningiomas. J Neuropathol Exp Neurol 1948; 7: 69 – 80.
8. Balasubramaniam V, Ramamurthi B. Meningioma. Neurol 1970; 18: 1: 81 - 8.
9. Guthrie BL, Ebersold MJ, Scheithauer BW. Neoplasms of the intracranial meninges. In: Youmans JR, ed. Neurological Surgery, ed 3. Philadelphia: WB Saunders, 1990: 3250–3315.
10. Kleihues P, Burger P C, Scheitauer B W: The new WHO classification of brain tumours. Brain Pathol 1993; 3: 255-68.
11. Jellinger K, Slowik F. Histological subtypes and prognostic problems in meningiomas. J Neurol 1975; 208(4):279-98.