

Aorto-bi-Femoral Bypass for Aorto-Iliac Occlusive Disease: Recent Experience at the National Institute of Cardiovascular Diseases (NICVD)

AHM Bashar¹, GMM Hossain¹, E Hakim¹, NC Mondol¹, MN Sabah¹, MF Hossain¹, NK Dey¹, S Samad¹, AA Mamun¹, K Haroon¹, MF Islam¹, AK Khan², S Ferdous², M Rahman², AK Beg² & SAN Alam¹

¹Department of Vascular Surgery, NICVD, Dhaka; ²Department of Anesthesiology, NICVD, Dhaka, Bangladesh

Abstract:

Keywords:

Aorto-Iliac
Occlusive Disease,
Aorto-bi-Femoral
Bypass.

Background & Objectives: Aorto-bi-femoral bypass is one of the most important surgical strategies in vascular surgical practice. The procedure is employed in surgical revascularization for both stenotic and aneurysmal diseases involving the aorto-iliac segment. The present study was carried out to analyze our recent experiences with this procedure for aorto-iliac occlusive diseases (AIOD) at the National Institute of Cardiovascular Diseases (NICVD).

Materials and Methods: Over a period of 3 years (April 2008 to March 2011), a total of 47 patients underwent aorto-bi-femoral or aorto-bisiliac bypass grafting for AIOD using a Y-graft prosthesis. The mean age of the patients was 46.4 years (range 25-75 years). Thirty eight of the patients were male and the remaining 9 were female. A retroperitoneal approach was used in 27 patients. In the remaining 20 patients, the operation was done using a transperitoneal approach. A Gelatin-coated Dacron Y-graft prosthesis was used in 43 (5 of which were silver-coated prosthesis) patients while PTFE (Polytetrafluoroethylene) prosthesis was used in the remaining 4 patients. The operation was carried out under epidural anesthesia with sedation in most cases.

Results: The operation was well-tolerated in all patients. There was no intraoperative mortality in this series. Two patients died in the immediate post-operative period- one due to myocardial infarction and the other due to acute renal shut-down leading to renal failure accounting for a mortality rate of 4.3%. Wound infection and lymphorrhoea at the groin incision site were the two main immediate post-operative complications. There was no incidence of graft infection in this series. Twelve patients were available for post-operative follow-up up to 2 years. Out of them, 5 patients returned with occluded grafts 8-23 months after the operation. Three of these patients underwent graft excision with re-do Y-graft bypass. The remaining two were treated with extra-anatomic bypass (Axillo-bifemoral).

Conclusions: Aorto-bi-femoral bypass is an effective surgical strategy for occlusive diseases involving the abdominal aorta and the iliac arteries. The procedure is well-tolerated with a low incidence of early post-procedural complications and graft failure. However, poor adherence of the patients to follow-up remains a significant obstacle for evaluating the long-term outcome of this procedure.

(*Cardiovasc. j.* 2011; 4(1): 26-31)

Introduction:

Although the advent of interventional treatments has brought a paradigm shift in the management approach to aorto-iliac occlusive diseases (AIOD),^{1,2} conventional surgical revascularization still occupies an important place in this patient subgroup. Among the surgical strategies adopted to revascularize the occluded aorto-iliac segment, aorto-bi-femoral bypass with Y-graft is considered the 'gold standard'.^{3,4} The approach is generally advocated in patients having lesions that are considered unsuitable for Percutaneous Transluminal Angioplasty (PTA).

Such lesions include bilateral, multifocal long segment stenosis or occlusion. Symptomatic patients with this type of lesions benefit from open surgical revascularization. However, the results of aorto-bi-femoral bypass with Y-graft have been variable. Many of these patients are 'arteriopath' and therefore, have a generalized atherosclerotic process with cardiovascular and cerebrovascular manifestations. The presence of other risk factors and comorbidities like diabetes mellitus, hypertension, and cigarette smoking often contribute to major post-operative complications in

Address correspondence: Dr Abul Hasan Muhammad Bashar, Department of Vascular Surgery, National Institute of Cardiovascular Diseases (NICVD), Dhaka, Bangladesh. E-mail: ahmbashar@yahoo.com.

the form of graft failure and cardiovascular and cerebrovascular events. While there have been a lot of reports from developed countries describing the surgical experience with aorto-bifemoral bypass,³⁻⁶ contributions from developing countries have been rather few. We undertook this study to analyze our recent experiences with this procedure.

Materials and Methods:

Over a period of 3 years (April 2008 to March 2011), a total of 47 patients underwent aorto-bi-femoral or aorto-bisiliac bypass grafting for aorto-iliac occlusive disease at the National Institute of Cardiovascular Diseases (NICVD), Dhaka using a Y-graft prosthesis. The mean age of these patients was 46.4 years (range 25-75 years). Thirty eight of the patients were male and the remaining 9 were female. Various clinical presentations of the patients are summarized in Table-I. Risk factors and co-morbid conditions found in these patients are listed in Table-II.

Table-I

Clinical presentations of the patients of this series

Clinical Features	Number of Patients
Intermittent claudication	21
Ischemic rest pain	13
Ulcer/gangrene	18
Thigh/buttock claudication	24
Impotence	9
Amputation	7

Table-II

Various risk factors/co-morbid conditions in the patients of this series

Risk Factors/co-morbidities	Number of Patients
Hypertension	35
Diabetes Mellitus	23
Dyslipidemia	32
Smoking	38
Renal Insufficiency/ Chronic Kidney Disease (CKD)	5
Coronary Artery Disease (CAD)	19
Carotid artery disease/ Cerebrovascular Accidents (CVA)	4
Obesity	11

Diagnostic Work-up: Most patients in this series presented at the vascular out-patient department of NICVD with symptoms suggestive of AIOD as listed in Table 1. Some were referred by cardiologists. After a thorough clinical examination, the ABI was measured. Then a Duplex ultrasound scan of the lower limb arterial system was done with analyses of Doppler spectral pattern as well as luminal characteristics of the arteries. The patient was then prepared for peripheral arteriogram which included a coronary angiogram (CAG) for patients with evidence of ischemic heart disease (IHD) or those aged 40 years or more. The angiogram was then reviewed by vascular surgeons in presence of a cardiologist. Lesions suitable for interventional treatment were set aside for PTA, while those judged too complicated for intervention were prepared for surgery. Forty five patients in the present series had an infra-renal aortic occlusion (Figure 1). The remaining 2 patients had juxta-renal lesion.

Preoperative Work-up: Routine preoperative work-up included a complete blood count with hemoglobin percentage and ESR, C-reactive protein, blood sugar, serum bilirubin, liver transaminases, blood urea and serum creatinine, serum electrolyte, fasting lipid profile in a fasting state, and a baseline prothrombin time with International Normalized Ratio (INR). Patients were also screened for major hepatitis viruses and sexually transmitted diseases. In addition to the above, pus from any ulcer or gangrene was sent for culture and sensitivity. In diabetic patients, optimum glycemic control was achieved before surgery with addition of soluble insulin whenever necessary. Surgery was deferred in patients showing growth of organism in their ulcer or gangrene. In patients having co-existent significant coronary artery disease, a cardiologist was consulted. Whenever coronary revascularization was deemed necessary, it preceded peripheral revascularization by at least 3 months, except in one patient who had undergone Percutaneous Transluminal Coronary Angioplasty (PTCA) 2 weeks before the aorto-bifemoral bypass.

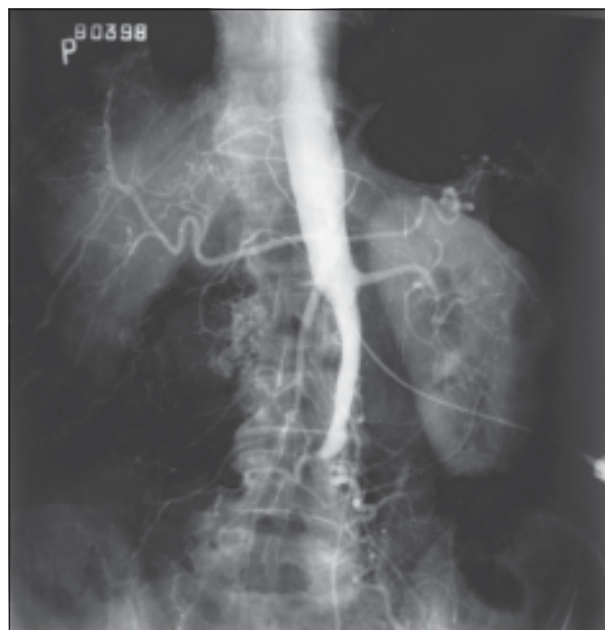

Fig.-1: Aorto-iliac occlusive disease on angiogram

Surgical Procedure: The operations were carried out under high epidural anesthesia on most occasions with sedation by Propofol. The abdominal aorta was approached through a retroperitoneal approach in 27 patients and through a transperitoneal approach in the remaining 20. Careful dissection was carried out around the abdominal aorta between the origins of renal arteries and the inferior mesenteric artery (IMA). In 2 patients with juxta-renal aortic occlusion, control of the suprarenal aorta and the renal arteries was ensured. Having taken proximal control of the aorta, a longitudinal aortotomy was done. Endarterectomy was performed to establish flow from the proximal aorta. An aortic clamp was then placed and proximal anastomosis between the abdominal aorta and the graft was done in an end-to-side fashion in 37 patients and end-to-end fashion in the remaining 10. The limbs of the graft were then carefully tunneled to the groin where oblique incisions were placed to expose the femoral arteries. Finally, the distal anastomoses were done between the limbs of the prosthesis and the common femoral arteries (Figure 2). In 2 of the 9 patients complaining of impotence, the occluded or stenosed left internal iliac arteries were endarterectomized and anastomosed to the left iliac limb of the graft. A Gelatin-coated Dacron Y-graft prosthesis was used in 43 (5 of which were silver-coated prosthesis) patients while PTFE

(Polytetrafluoroethylene) prosthesis was used in the remaining 4 patients.

In 8 patients, concomitant distal bypass was done. Amputations for any non-viable portion of the limb were always carried out. This included disarticulation of one or more toes and Syme's procedure.

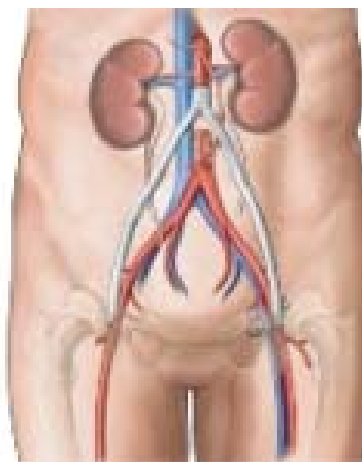


Fig.-2: Schematic diagram showing completed aorto-bifemoral bypass grafting for aorto-iliac occlusive disease.

Results:

All operations in the present series were completed uneventfully. Mean operation time was 195 ± 23 minutes and mean transfusion volume was 545 ± 27 ml. Mean ICU stay was 3 ± 5 days. Two patients (4.3%) died in the immediate post-operative period—one 10 hours after the operation and the other on the 2nd postoperative day. Cause of death in the first case was myocardial infarction. This patient had undergone PTCA with stenting to his right coronary artery 2 weeks earlier. The second death was due to acute renal shut-down leading to renal failure. This patient had chronic kidney disease (CKD). The aortic lesion in this case was juxta-renal requiring a suprarenal aortic clamping. The remaining 45 patients left the hospital in stable conditions with satisfactory surgical outcome. Mean hospital stay was 11 ± 5 days. Before discharge, all patients were evaluated by Duplex ultrasound and measurement of ABI. All patients were asked to return to the hospital for follow-up 1 month, 3 months, 6 months and 1 year after the operation. Further follow-up was at one-year interval. Additional revascularization procedures

in the distal arterial tree- when required- were planned 4-6 weeks after the discharge.

Wound infection and lymphorrhoea at the groin incision site were the two main immediate post-operative complications. Six patients had lymphorrhoea which was managed by insertion of a drain that was kept in situ until lymph secretion stopped. This strategy was successful in 4 patients while two required reexploration of the groin wound to plicate the lymphatics. Surgical wound infection was found in 8 patients. Six of these were superficial infections and responded to local wound care. The remaining 2 patients required a more expeditious care that included change in antibiotics according to culture and sensitivity report, wound debridement and secondary wound closure. There was no incidence of graft infection in this series.

Twelve patients attended the vascular out-patient department for post-operative follow-up up to 2 years. Graft occlusion was detected in five of these patients 8-23 months after the operation. Three of these patients underwent graft excision with redo Y-graft bypass. The remaining two were treated with extra-anatomic bypass (Axillo-bifemoral) with satisfactory outcome.

Discussion:

Infrarenal abdominal aorta and iliac arteries are among the commonest sites to be involved in atherosclerotic lesions.⁵ Stenotic lesions in this area have been classified into 3 main categories depending on the extent of the lesion. Type I disease represents lesion of the aorta and common iliac arteries, type II disease signifies lesions extending into the external iliac arteries and type III means that the lesions have involved the common femoral arteries in addition to the aorta and iliac arteries.⁶ Patients with type I lesions may remain asymptomatic due to the development of rich network of collaterals, although many experience buttock claudication.⁷ Type II lesions produce symptoms like buttock and thigh claudication and may also cause impotence when it comes to be termed 'Syndrome Leriche'. About two-thirds of the AIOD are type III lesions which typically produce the symptoms of intermittent claudication. Treatment approaches to AIOD have evolved considerably over the last couple of decades thanks to the tremendous development in the field of catheter-based techniques. Many type I lesions

are now treated by 'endovascular means'.⁸ However, bilateral long segment and multifocal lesions with additional femoro-popliteal involvement are better managed surgically than by interventional means. While deciding strategy for AIOD in developing countries, there is the additional issue of cost coming into the equation. Interventional therapy is often more expensive than surgical revascularization. At least 3 of our patients could have been suitable candidates for interventional treatment but were eventually treated by open surgical means on the grounds of cost.

The mean age of the patients in our series was only 46. This, to the best of our knowledge, is the youngest group of aorto-bifemoral bypass recipients. It may be worth mentioning that as many as 5 patients in this series were aged below 30 with another 7 being less than 40 years old. AIOD in such young patients raises important issues related to the pathophysiology of the disease. Is the disease process in these young patients different? Gross examination of the plaques could not answer this question. Detailed histopathological examination of the plaques and the arteries as well as nutritional, immunologic and genetic screening of these patients might give us newer insight into the issue.

AIOD patients with coexistent IHD constitute a contentious issue. We screened all patients for CAD and adopted the strategy of having the critical coronary lesion addressed before peripheral revascularization. We also had the surgery deferred for at least 3 months after any PTCA procedure. These, however, are not universal recommendations. Reports of Y-graft bypass surgery in presence of significant CAD have been published.⁹ One of the two mortalities in the present series occurred in a patient who had PTCA with stenting to the right coronary artery 2 weeks prior to the Y-graft bypass. We went for an earlier revascularization in this patient as he was suffering from severe ischemic rest pain with possibility of impending tissue loss. The patient had suffered a massive heart attack in the immediate post-operative period. This could have resulted from an episode of intraoperative hypotension that occurred in this patient resulting in acute stent thrombosis. We recommend particular care in

avoiding hemodynamic derangements in this particular group of patient in order to prevent adverse cardiac events. The 4.3% in-hospital mortality in the present series should be among the better results that have been reported for this procedure.¹⁰⁻¹⁸ We believe that our strategy regarding the coronary lesion have contributed positively to the results.

Juxta-renal aortic occlusion poses a formidable surgical challenge. We operated on 2 patients with such lesions. One of these patients had CKD and died of renal failure in the early postoperative period. Meticulous care during manipulation of the plaques at this critical aortic segment as well as appropriate renal protective measures should be instituted while handling such cases.

Good run-off arteries are important prerequisites for the patency of the Y-graft. To ensure this, any diseased femoro-popliteal segment should be revascularized in the same sitting. Unfortunately, this was not uniformly practiced in all patients of the present series. Generally, we staged the distal bypasses and performed 8 femoro-popliteal bypasses and endarterectomy in the same sitting after the Y-graft procedure. All other distal bypass procedures were performed 2-3 months after the aorto-femoral bypass.

Long-term patency of the Y-graft is an important issue. Previous studies have reported a 10-20% graft occlusion rate at 5 years and 25-30% graft failure at 10 years.^{9,10,12,14} Unfortunately, we had only 12 patients adhering to the post-operative follow-up protocol. Thus, data regarding graft patency in this series is inadequate. There was no incidence of graft thrombosis in the immediate post-operative period. The first case of graft occlusion was detected 8 month after surgery. This patient had occlusive disease in the distal arterial tree which was not revascularized during the aorto-femoral bypass. There were 4 additional cases of graft failure within 2 years after the surgery. All these patients presented with recurring claudication. Cases of occluded grafts were managed with re-do Y-graft bypass in 3 patients and extra-anatomic bypass in 2.

The importance of lifestyle modification in patients with AIOD cannot be over-emphasized. Cessation of smoking and meticulous control of diabetes, hypertension and serum lipid levels are necessary.

Regular walking and dietary modifications are also important. The patients often fail to understand the true importance of these measures. Many patients go back to their old smoking habit, which lead to progression of distal disease and recurrent symptoms. Proper counseling at the time of discharge may help in the implementation of the lifestyle modifications in these patients.

References:

1. Rutherford RB. Options in the surgical management of aorto-iliac occlusive disease: a changing perspective. *Cardiovasc Surg* 1999;7(1):5-12.
2. Brewster DC. Current controversies in the management of aortoiliac occlusive disease. *J Vasc Surg* 1997;25(2):365-79.
3. Rutherford RB. Aortobifemoral bypass, the gold standard: technical considerations. *Semin Vasc Surg* 1994;7(1):11-6.
4. Andr asi TB, Humbert T, Dorner E, Vahl CF. A minimally invasive approach for aortobifemoral bypass procedure. *J Vasc Surg* 2011;53(3):870-5.
5. DeBakey ME, Lawrie GM, Glaser DH. Patterns of atherosclerosis and their surgical significance. *Ann Surg* 1985;201:105-131.
6. Brewster DC. Clinical and anatomic considerations for surgery in aortic disease and results of surgical treatment. *Circulation* 1991;83:142-152.
7. Darling RC, Brewster DC, Hallett JW, Jr, Darling RC., 3rd Aortoiliac reconstruction. *Surg Clin North Am* 1979;59:565-579.
8. Kashyap VS, Pavkov ML, Bena JF, Sarac TP, O'Hara PJ, Lyden SP, Clair DG. The management of severe aortoiliac occlusive disease: endovascular therapy rivals open reconstruction. *J Vasc Surg* 2008;48(6):1451-7, 1457.e1-3.
9. Morris-Stiff G, Ogunbiyi S, Winter RK, Brown R, Lewis MH. Aortic replacement in aorto-occlusive disease: an observational study. *BMC Surg* 2008; 8: 19.
10. Moore WS, Cafferata HT, Hall AD, Blaisdell FW. Defense of grafts across the inguinal ligament: an evaluation of early and late results of aortofemoral bypass grafts. *Ann Surg* 1968;168:207-214.
11. Perdue GD, Long WD, Smith RB., III Perspective concerning aortofemoral arterial reconstruction. *Ann Surg* 1971;173:940-944.
12. Malone JM, Moore WS, Goldstone J. The natural history of bilateral aortofemoral bypass grafts for ischemia of the lower extremities. *Arch Surg* 1975;110:1300-1306.
13. Brewster DC, Darling RC. Optimal methods of aortoiliac reconstruction. *Surgery* 1978;84:739-747.
14. Mulcare RJ, Royster TS, Lynn RA, Connors RB. Long-term results of operative therapy for aortoiliac disease. *Arch Surg* 1978;113:601-604.

15. Nevelsteen A, Suy R, Daenen W, Boel A, Stalpaert G. Aortofemoral grafting: factors influencing late results. *Surgery* 1980;88:642–653.
16. Crawford ES, Bomberger RA, Glaeser DH, Saleh SA, Russell WL. Aortoiliac occlusive disease: factors influencing survival and function following reconstructive operation over a 25 year period. *Surgery* 1981;90:1055–1067.
17. Szilagyi DE, Elliott JP, Jr, Smith RF, Reddy DJ, McPharlin M. A 30-year survey of the reconstructive surgical treatment for aortoiliac occlusive disease. *J Vasc Surg* 1984;3:421–435.
18. Akker PJ van der, van Schilfgaarde R, Brand R, van Bockel JH, Terpstra JL. Long term success of aortoiliac operation for arteriosclerotic obstructive disease. *Surg Gynecol Obstet* 1992;174:485–496.