

Verrucous Carcinoma in External Auditory Canal – A Rare Case

Md Zillur Rahman¹, Bithi Bhowmik², Robiul Islam³, Rakib Hossain⁴

Abstract

Verrucous carcinoma is a variant of squamous cell carcinoma. It is of low grade malignancy and rarely present with distant metastasis. Oral cavity is the commonest site of this tumour; other sites are larynx, oesophagus and genitalia. Verrucous carcinoma in external auditory canal is extremely rare. This is the presentation of a 45 years old woman who came to the ENT & Head Neck Surgery department of Delta medical college, Dhaka, Bangladesh with discharging left ear and impairment of hearing on the same side for 7 years. Otoscopic examination showed a mass occupying almost whole of the external auditory canal and the overlying skin was thickened, papillary and blackish. Cytology from external auditory canal scrap showed hyperkeratosis and parakeratosis. External auditory canal bone was found eroded at some parts. Excision of the mass was done under microscope. Split thickness skin grafting was done in external auditory canal. The mass was diagnosed as verrucous carcinoma on histopathological examination. Afterwards she was given radiotherapy. Six months follow up showed no recurrence and healthy epithelialization of external auditory canal.

Key words: Verrucous carcinoma, parakeratosis, hyperkeratosis.

Delta Med Col J. Jan 2013;1(1):25-27

1. Prof. Dr. Md Zillur Rahman, MS, FCPS (ENT), Head of the department of ENT & HNS, Delta Medical College & Hospital, Dhaka, Bangladesh.
2. Dr. Bithi Bhowmik, FCPS (ENT), Assistant Professor, ENT & HNS department, Delta Medical College & Hospital, Dhaka, Bangladesh.
3. Dr. Robiul Islam, MS (ENT), Assistant Professor, ENT & HNS department, Delta Medical College & Hospital, Dhaka, Bangladesh.
4. Dr. Rakib Hossain, DLO, MCPS (ENT), Resident surgeon, ENT & HNS department, Delta Medical College & Hospital, Dhaka, Bangladesh.

Correspondence: Dr. Bithi Bhowmik. e-mail: bithi.bhowmik059@yahoo.com

Introduction

Verrucous carcinoma is a variant of well-differentiated squamous cell carcinoma. It has specific clinical and histological features. Various names are used to describe this condition including 'Ackerman's tumour', 'epithelioma cuniculatum' and 'carcinoma cuniculatum'.¹ The tumour grows slowly and locally.

It is invasive in nature but unlikely to metastasize. It appears as a painless, thick white plaque resembling a oracauliflower. The most common sites of oral mucosal involvement include the buccal mucosa, followed by the mandibular alveolar crest, gingiva and tongue.² Other sites are larynx, oesophagus and genitalia.

Verrucous carcinoma in external auditory canal is extremely rare. The ages range from 50 to 80 years with a male predominance.³ It may grow very large and can destroy adjacent tissue such as bone and cartilage.

The diagnosis is confirmed by histopathology. Surgeon has to provide adequate specimen including the full thickness of the tumour and adjacent uninvolved mucosa for the correct diagnosis.

Case Report

This is the presentation of a 45 years old woman who came to the ENT and Head Neck Surgery department of Delta Medical College, Dhaka, Bangladesh with a mass in left ear with discharge and impairment of hearing on the same side for 7 years. She was treated by some topical and systemic antibiotics on several occasions previously. Otoscopic examination showed a mass occupying almost whole of the external auditory canal and the overlying skin was thickened, papillary and blackish. Cytology from external auditory canal scrap showed hyperkeratosis and parakeratosis. External auditory canal bone was found eroded at some parts during surgery. Excision of the external auditory canal mass was done under general anaesthesia. Whole skin from external auditory canal was excised under microscope. The eroded bony part was made smooth using microdrill. Split thickness skin was taken from anterior aspect of left thigh and grafting was done in external auditory canal. The whole of the specimen was sent for histopathological examination which revealed it as verrucous carcinoma.

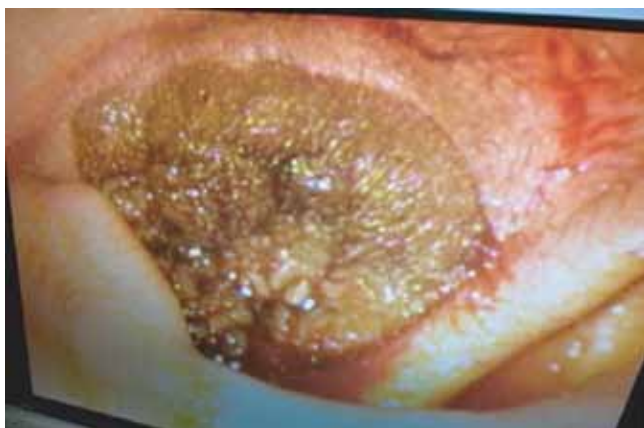

Fig 1: Preoperative photograph of external auditory canal (under microscope)

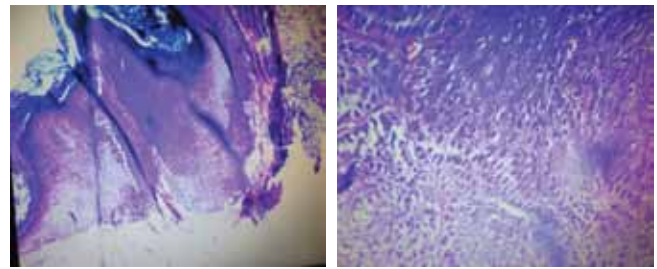


Fig 2: Photomicrograph - well differentiated squamous architecture and deep pushing margin

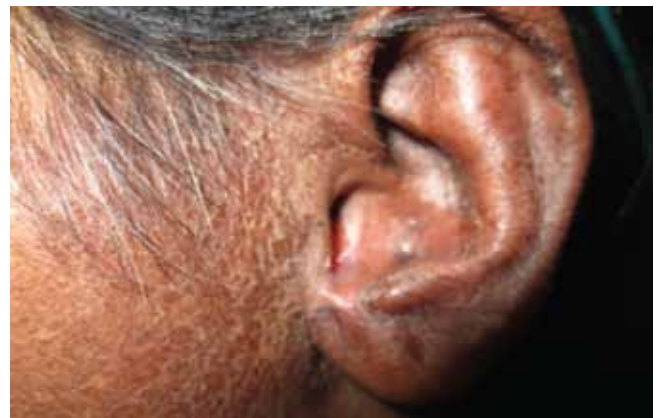

Fig 3: After surgery and radiotherapy (6 months)

Discussion

The etiology of verrucous carcinoma is not well defined. Human papilloma virus (HPV) has been considered one of the causative factors. Smoking seems to be highly associated with the development of mucosal verrucous carcinoma of the head and neck. Poor hygiene, presence of lichenoid and leucoplakic lesions may act as predisposing factors.⁴ In this report the patient has given no history of such causative factors.

Verrucous carcinoma and verrucous hyperplasia are indistinguishable clinically.⁵ The clinical association with leucoplakia is significant, and the evidence indicates that untreated leucoplakia may develop into a verrucous carcinoma in time. Verrucous hyperplasia is a forerunner of verrucous carcinoma.⁶ The transition is so consistent that the hyperplasia, once diagnosed should be treated as verrucous carcinoma. In verrucous carcinoma, regional lymph nodes are often enlarged and tender because of inflammatory involvement which simulate metastatic tumour. Lymph nodes were not involved in this case.⁷

Discussion

The etiology of verrucous carcinoma is not well defined. Human papilloma virus (HPV) has been considered one of the causative factors. Smoking seems to be highly associated with the development of mucosal verrucous carcinoma of the head and neck. Poor hygiene, presence of lichenoid and leucoplakic lesions may act as predisposing factors.⁴ In this report the patient has given no history of such causative factors.

Verrucous carcinoma and verrucous hyperplasia are indistinguishable clinically.⁵ The clinical association with leucoplakia is significant, and the evidence indicates that untreated leucoplakia may develop into a verrucous carcinoma in time. Verrucous hyperplasia is a forerunner of verrucous carcinoma.⁶ The transition is so consistent that the hyperplasia, once diagnosed should be treated as verrucous carcinoma. In verrucous carcinoma, regional lymph nodes are often enlarged and tender because of inflammatory involvement which simulate metastatic tumour. Lymph nodes were not involved in this case.⁷

Surgery is considered the choice of treatment for these lesions.⁸ Radiotherapy alone is controversial. Surgery followed by radiotherapy is the next most preferable treatment and may have benefits, particularly in cases of extensive lesions.⁹ Recurrence rate is high in cases in which either irradiation or surgery alone is performed. The patient was referred to the department of Oncology for post surgical management where she was treated by radiotherapy. On follow up she was free of any complaints. After six months of completion of radiotherapy, there was no recurrence.

Verrucous carcinoma of external auditory canal is very rare. Clinical presentation of any black, papillary mass in external auditory canal must be excluded for it.

References

1. Ackerman LV. Verrucous carcinoma of oral cavity. *Surgery*.1948;23:670-78.
2. Schwartz RA. Verrucous carcinoma of the skin and mucosa. *J Am Acad Dermatol*.1995;32:1-21.
3. Shear M, Pindborg JJ. Verrucous hyperplasia of the oral mucosa. *Cancer*.1980;46:1855-62.
4. Medina JE, Dichtel W, Luna MA. Verrucous-squamous carcinoma of the oral cavity: a clinicopathologic study of 104 cases. *Arch Otolaryngol*.1984;110:437-40.
5. Koch BB, Trask DK, Hoffman HT, Karnell LH, Robinson RA, Zhen W, Menck HR. National survey of head and neck verrucous carcinoma. *Cancer*.2001;92:110-20.
6. McDonald JS, Crissmas JD, Gluckman JL. Verrucous carcinoma of the oral cavity. *Head Neck Surg*. 1985;5:22-28.
7. Murrah VA, Batsakiz JG. Proliferative verrucous leuoplakia and verrucous hyperplasia. *Ann Otol Rhinol Laryngol*.1994;103:660-63.
8. Regezi JA, Siubba J. Oral pathology clinical pathologic correlations. Philadelphia: WB Saunders Company;1993.
9. Yoshimura Y, Mishima K, Obara S, Nariaib Y, Yoshimura H, Mikami T. Treatment modalities for verrucous carcinoma and their outcomes: contribution of radiotherapy and chemotherapy. *Int J Clin Oncol*.2001;6(4):192-200.