

Effect of Oyster Mushroom (*Pleurotus Florida*) on Paracetamol Induced Changes of serum bilirubin level and liver tissue protein in Rats

Afroza Khanam Sumy¹, Nasim Jahan², Nayma Sultana³, SM Ruhul Amin⁴

Abstract

Background: Liver is continuously exposed to a variety of toxic agents like drugs and chemicals that may interfere with hepatic function and may cause hepatic damage. Oyster mushroom is excellently edible, nutritious and has got free radical scavenging activity, thereby may be considered as hepatoprotective agent. **Objective:** To observe the effect of Oyster mushroom on paracetamol induced changes in serum bilirubin and liver tissue protein in rats. **Method:** This experimental study was carried out in the Department of Physiology, Sir Salimullah Medical College (SSMC), Dhaka from 1st July 2009 to 30th June 2010. A total number of 34 Wistar albino rats, age ranged from 90 to 120 days, weighing between 150 to 210 grams were selected for the study. After acclimatization for 14 days, they were divided into two groups, control group (Group A) and experimental group (Group B- mushroom pretreated and paracetamol treated group). Control group was again subdivided into group A₁ (baseline control) and group A₂ (paracetamol treated control group). All groups of animals received basal diet for 30 consecutive days. Group A₁ consisted of 10 rats, received propylene glycol (2 ml/kg bw, orally) only on 30th day. Group A₂ consisted of 14 rats, received single dose of paracetamol suspension (750 mg/ kg bw, orally) only on 30th day. Group B consisted of 10 rats, received mushroom extract (200 mg/ kg bw, orally) for 30 consecutive days and paracetamol suspension (750 mg/ kg bw, orally) only on 30th day. All the animals were sacrificed on 31st day. Then blood and liver sample were collected. Estimation of serum total bilirubin level and assessment of protein concentration in liver tissue homogenate were done by using standard laboratory kits. The statistical analysis was done by one way ANOVA and Bonferroni test as applicable. **Result:** The mean serum total bilirubin was significantly ($p < 0.001$) higher in paracetamol treated group in comparison to that of baseline control group. Again, the mean serum total bilirubin was significantly ($p < 0.001$) lower in mushroom pretreated and paracetamol treated group (experimental group) when compared to that of paracetamol treated group (control). The protein concentration in liver tissue homogenate was significantly ($p < 0.01$) lower in paracetamol treated group in comparison to that of baseline control group. Again, in the liver tissue homogenate protein concentration was significantly ($p < 0.001$) higher in mushroom pretreated and paracetamol treated group (experimental group) when compared to that of paracetamol treated group (control). **Conclusion:** The present study revealed that Oyster mushroom can protect liver tissue against paracetamol induced liver damage.

Key words: Hepatoprotective, Oyster mushroom, Tissue homogenate

J Bangladesh Soc Physiol. 2011 June; 6(1): 10-15

For author affiliations, see end of text.

<http://www.banglajol.info/index.php/JBSP>

Introduction

Liver is the most important organ concerned with the biochemical activities in the human body. It has great capacity

to detoxify toxic substances and synthesize useful products¹. A variety of toxic agents like paracetamol (APAP), D-galactosamine (D-GaIN),

carbon tetrachloride (CCL₄), viruses, alcohol, lipid peroxidative products and various drugs may damage the liver cells².

Paracetamol is a widely used antipyretic and analgesic drug. When taken in overdose, it may develop hepatotoxicity by over production of *N-acetyl p- benzoquinoneimine* (NAPQI) by cytochrome p450³. This NAPQI may react with the basic cellular constituents like protein, lipids, RNA, DNA and induce a dose dependent depletion of intracellular glutathione and disturb calcium homeostasis⁴. Additional mechanisms of paracetamol induced hepatotoxicity include nucleotide alterations and protein synthesis disruption⁵.

Damage to the liver by hepatotoxic agents is of grave consequence as because chronic liver injury leads to fibrosis, end stage cirrhosis and hepatocellular carcinoma⁶. As a result, there is increasing need to search of an agent which could protect the liver from such damage. Mushrooms have been used in folk medicine throughout the ancient times. Now a days, mushrooms are widely used as a nice vegetable⁷.

The *Pleurotus* mushroom comprises about 40 species that referred to as "Oyster mushroom" which is excellently edible and highly nutritious⁸. Oyster mushroom can suppress toxin induced increased level of serum total bilirubin in animals when compared to those of mushroom untreated rats, indicating the hepatoprotective effect of mushroom⁹. Again, some reasearchers observed that the mushroom extract can protect the structural integrity of the hepatic cell memebrane, which ultimately preserve liver tissue protein concentration¹⁰.

Throughout the world there is a lack of reliable liver protective drugs in modern medicine. Now a days Ayurveda recommended some medicinal preparation for the treatment of hepatic disorder. In abroad different research works with this

mushroom claimed that it may have hepatoprotective role, due to its free radical scavenging activity^{7,9}. But in Bangladesh little is known on this aspect. Therefore, the present study was undertaken to evaluate the scientific basis of the hepatoprotective effect of oyster mushroom. This study may be useful in the search of natural compounds that can protect liver from toxic agents without producing any undesirable side effects.

Methods

This experimental study was conducted between July 2009 to June 2010 in the Department of Physiology, SSMC, Mitford, Dhaka. A total number of 34 apparently healthy Wistar albino male rats, weighing from 150 to 210 gram, age ranged from 90 to 120 days were used. The animals were purchased from the animal house of Bangladesh Council of Scientific and Industrial Research (BCSIR), Dhaka. Ethical permission was taken from the Institutional Ethics Committee (IEC) of SSMC, Dhaka. Prior conducting the study the animals were acclimatized for 14 days under 12 hour dark & light schedule. During this period they had free access to food and water *ad libitum*. Then they were divided into two groups, control group (Group A) and experimental group (Group B- mushroom pretreated and paracetamol treated group). Control group again subdivided into group A₁ (baseline control) and group A₂ (paracetamol treated control group). All groups of animals received basal diet for 30 consecutive days. Group A₁ consisted of 10 rats, received propylene glycol (2 ml/kg bw, orally) only on 30th day. Whereas, Group A₂ consisted of 14 rats, received single dose of paracetamol suspension (750 mg/ kg bw, orally) only on 30th day. Finally, Group B consisted of 10 rats, received mushroom extract (200 mg/ kg bw, orally) for 30 consecutive days and paracetamol suspension (750 mg/ kg bw, orally) only on 30th day. During the study period, one rat of paracetamol treated control

group died might be due to toxic effect of paracetamol. After giving paracetamol and mushroom all the animals including the baseline control rats, were sacrificed on 31st day. After 14 days of acclimatization, body weights were measured (initial bw). Again, final body weights (final bw) of rats before sacrifice on 31st day were taken. Then blood and liver samples were collected. Liver was washed in ice cold saline. Then it was wiped in tissue paper and weighed. Measurement of serum total bilirubin was done by enzymatic method ¹¹ in the laboratory of Department of Biochemistry, SSMC. Assessment of protein concentration in liver tissue homogenate was done by using standard laboratory kits ¹² in the laboratory of Department of Biochemistry and Molecular Biology, Jahangirnagar University. Statistical analysis was done by ANOVA and Bonferroni test by using SPSS, version 15.

Preparation of liver supernatants

Each liver sample (100 mg/ml buffer) was homogenized in phosphate buffer (pH7), the homogenate was then centrifuged at 4000 rpm for 15 minutes and the supernatant obtained was used for assessment of protein concentration in liver tissue ¹³.

Preparation of mushroom extract

Oyster mushroom was collected from National Mushroom Development and Extension Center, Savar, Dhaka. Fresh mushroom was dried in the sun and finally in the oven and then crushed into powder with a mechanical grinder. Mushroom powder then was extracted with ethanol, filtered and evaporated to obtain mushroom extract ¹⁴.

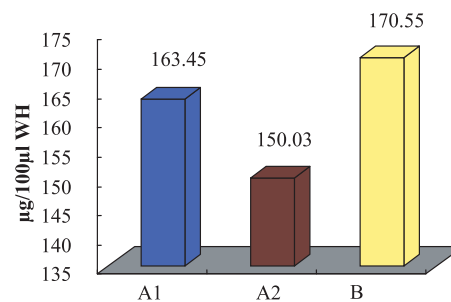
Result

Body weight of the rates are presented in Table I. The liver weight was higher in group A₂ when compared to that of group A₁ and B, though it

was statistically significant ($p < 0.01$) between group A₁ vs A₂, but non significant between group A₂ vs B. Again, liver weight of group B was higher than that of group A₁, but the difference was non significant (Table II).

The serum level of total bilirubin were significantly higher in group A₂ ($p < 0.001$) and group B ($p < 0.05$) in comparison to that of group A₁. Again, this value was significantly ($p < 0.001$) lower in group B when compared to that of group A₂ (Table III)

The protein concentration in liver tissue homogenate was significantly ($p < 0.01$) lower in group A₂ in comparison to that of group A₁. On the other hand, protein concentration was almost similar and showed no statistically significant difference between group A₁ and B. Again, this value was significantly ($p < 0.001$) higher in group B when compared to that of group A₂ (Figure 1).



Control group
 Group A1 (baseline control group)
 Group A2 (paracetamol treated control group)
 Experimental group
 Group B (mushroom pretreated and paracetamol treated group)
 WH=whole homogenate

Figure 1 : Protein concentration in liver in different groups (n=33)

Table I: Initial and final body weight of rat and percent of change of body weight in different groups (n=33)

Groups	n	Body weight (g)		% of change from final (F) weight to initial (I) weight
		Initial(day 1)	Final(day 31)	[(F-I)/I×100]
Group A ₁	10	182.80 ± 19.57	227.10 ± 19.31	24.69 ± 7.65
Group A ₂	13	183.38 ± 14.13	223.85 ± 14.52	22.27 ± 5.41
Group B	10	186.60 ± 10.11	216.70 ± 14.47	16.21 ± 6.59
Statistical analysis				
		p value		
A ₁ vs A ₂		0.999 ^{ns}	0.999 ^{ns}	0.999 ^{ns}
A ₁ vs B		0.999 ^{ns}	0.477 ^{ns}	0.020*
A ₂ vs B		0.999 ^{ns}	0.899 ^{ns}	0.104 ^{ns}

Results are expressed as Mean ± SD. Statistical analysis was done by ANOVA test and then perform Bonferroni test to compare between two groups. Figures in parentheses indicate ranges.

Control group

Group A₁ (baseline control group)

Group A₂ (paracetamol treated control group)

Experimental group

Group B (mushroom pretreated and paracetamol treated group)

n = Total number of subjects. ns = Non significant. * = Significant at p < 0.05

Table II Liver weight of rat in different groups (n=33)

Groups	N	Liver weight (g)
Group A ₁	10	3.57 ± 0.40
Group A ₂	13	4.22 ± 0.55
Group B	10	3.88 ± 0.42
Statistical analysis		
		p value
A ₁ vs A ₂		0.007**
A ₁ vs B		0.453 ^{ns}
A ₂ vs B		0.280 ^{ns}

Table III Serum total bilirubin in different groups (n=33)

Groups	n	Serum total Bilirubin (µmol/L)
Group A ₁	10	1.37 ± 0.29
Group A ₂	13	3.10 ± 0.69
Group B	10	1.95 ± 0.34
Statistical analysis		
		p value
A ₁ vs A ₂		0.001***
A ₁ vs B		0.043*
A ₂ vs B		0.001***

Discussion

In this study, the serum total bilirubin level of the rats was significantly ($p < 0.001$) higher in paracetamol treated group in comparison to that of baseline control rats. Again, serum bilirubin level was significantly ($p < 0.001$) lower in mushroom pretreated and paracetamol treated rats when compared to that of paracetamol treated rats. These findings are in consistent with those of some other investigators¹⁵.

In this study the protein concentration in the liver tissue homogenate was significantly ($p < 0.01$) lower in paracetamol treated group in comparison to that of baseline control group. On the other hand, protein concentration in the liver tissue was significantly ($p < 0.001$) higher in mushroom pretreated and paracetamol treated rats when compared to that of paracetamol treated group.

It has been suggested that high dose of paracetamol causes increased production of free radicals, which may initiate lipid peroxidation of hepatic cell membrane, mitochondrial dysfunction, hepatocellular death and ultimately increase in liver weight^{16,17} and also may cause increased serum bilirubin level¹⁸. However, increased liver weight and increased serum bilirubin levels both of which are useful indicators of paracetamol induced hepatocellular damage¹⁹.

It has been postulated that mushroom has a suppressive effect on the toxin mediated liver injury⁷. Some other researchers suggested that free radical scavenging activity of mushroom may be responsible for reduction in serum total bilirubin level⁹.

Different researchers suggested that some active compounds present in Oyster mushroom such as β -glucan, phenol and vitamin C scavenge free radicals and thus may act as an antioxidant. These active components of Oyster mushroom increase the activities of some antioxidant enzymes such as catalase (CAT), superoxide dismutase (SOD)

and glutathione peroxidase (GP_x)^{20, 21}. These antioxidant activities of mushroom are responsible for reduction of hepatic cell necrosis. All the above mentioned mechanisms may be responsible for preservation of tissue protein concentration.

In the present study, hepatic damage was observed in rats treated with paracetamol as evidenced by a higher level of serum bilirubin and lower level of protein concentration in liver tissue. This is further supported by an increase in liver weight in hepatotoxic rats of present study

Again, lower level of serum total bilirubin, higher level of protein concentration in the liver tissue and decrease in liver weight in mushroom pretreated and paracetamol treated rats suggested the possibility of this extract to give protection against toxin induced liver injury. These effects are most likely due to free radical scavenging activity. However, the exact mechanism involved in the hepatoprotective activity of Oyster mushroom extract against paracetamol induced liver damage in rats cannot be find out from this type of study.

Conclusion

This study reveals that oyster mushroom may have some role in decreasing serum bilirubin level and also in preservation of liver tissue protein due to its free radical scavenging activity. But the active component of mushroom which is responsible for this effect is exactly not yet known. So, further study on this aspect with larger sample size is required for definite conclusion.

Acknowledgement

Authors of this study are thankful to the authority of National Mushroom Development and Extension centre, Savar, Dhaka for the cooperation they provided. I would also express my sincere thanks to the DGHS for providing the partial financial support for completing the research work.

Author Affiliations:

1. Afroza Khanam Sumy, Assistant Professor, Department of Physiology, Enam Medical College and Hospital, Savar, Dhaka. Email; afrozakhanam58@yahoo.com
2. Professor Nasim Jahan, Professor and Head, Department of Physiology, Sir Salimullah Medical College SSMC, Mitford, Dhaka. Email; prof.dr.nasimjahan@gmail.com
3. Nayma Sultana, Assistant Professor, Department of Physiology, Sir Salimullah Medical College SSMC, Mitford, Dhaka. Email; nayma_sultana@yahoo.com
4. SM Ruhul Amin, Upazilla Agriculture Officer (LR), Khamarbari, Dhaka.

References:

1. Ganong WF. Regulation of gastrointestinal function. In: Review of Medical Physiology 23rd ed. New York: McGraw-Hill Companies, 2005.
2. Hwang JM, Tseng TH, Tsai YY, Lee HJ, Chou FP, Wang CJ, Chu CY. Protective effects of baicalein on tert-butyl hydroperoxide- induced hepatic toxicity in rat hepatocytes. *Journal of Biomedical Science*. 2005; 12: 389-397.
3. Dahlin DC, Miwa GT, Lu AYH, Nelson SD. N-acetyl-p-benzoquinone-imine: a cytochrome P-450 mediated oxidation product of acetaminophen. *Proc Natl Acad Sci USA*. 1984; 81:1327-1331.
4. Michael SL, Pumford NR, Mayeux PR, Niesman MR, Hinson JA. Pretreatment of mice with macrophage inactivators decreases acetaminophen hepatotoxicity and formation of reactive oxygen and nitrogen species. *Hepatology*. 1999; 30: 186-195.
5. Anderson ME, Nuganuma A, Meister A. Protection against cisplatin toxicity by administration of glutathione ester. *FASEB J*. 1990; 4: 3251-3255.
6. Lee WM. Hepatitis B virus infection. *N Engl J Med*. 1997; 337(24): 1733-1745.
7. Koyama T, Chounan R, Uemura D, Yamaguchi K, Yazawa K. Hepatoprotective effect of a hot water extract from the edible thorny oyster *Spondylus varius* on carbon tetrachloride induced liver injury in mice. *Biosci Biotechnol Biochem*. 2006; 70(3): 729-731.
8. Rishikesh M. Some edible oyster mushrooms of Arunachal Pradesh. In; Kumar A, Bohra CP, Singh LK, editor. Environment, pollution and management. New Delhi: APH publishing corporation; 2003; P. 349.
9. Selvi S, Arunavadas, Umadevi P. Hepatoprotective effect of the ethanolic extract of *Pleurotus florida* and *Calocybe indica* against CCL₄ induced hepatic damage in albino rats. *The Icfai University Journal of Life Sciences*. 2008; 2(4): 17-28.
10. Vermeulen NPE, Bessems JGM, Straat VD. Molecular aspects of paracetamol- induced hepatotoxicity and its mechanism- based prevention. *Drug Metabolism Reviews*. 1992; 24(3): 367-407.
11. Rand RN, di Pasqua A. *Clin Chem*. 1962;8: 570
12. Lowry HO, Rosebrough NJ, Farr AL, Randall RJ. Protein measurement with the folin phenol reagent. *J Biol Chem* 1951;193: 265-275.
13. Jayakumar T, Thomas P, Geraldine, P. Protective effect of an extract of the oyster mushroom, *Pleurotus ostreatus*, on antioxidants of major organs of aged rats. *Experimental Gerontology*. 2007;42:183-191.
14. Jayakumar T, Ramesh E, Geraldine P. Antioxidant activity of the oyster mushroom *Pleurotus osteratus*, on CCL₄ induced liver injury in rats. *Food and Chemical Toxicology*. 2006; 44: 1989-1996.
15. Raj Kapoor B, Venugopal Y, Anbu J, Harikrishnan N, Gobinath M, Ravichandran V. Protective effect of *Phyllanthus polyphyllus* on acetaminophen induced hepatotoxicity in rats. *Pak J Pharm Sci*. 2008; 21(1):57-62.
16. Murugaian P, Ramamurthy V, Karmegam N. Hepatoprotective activity of *Wedelia calendulacea* L. against acute hepatotoxicity in rats. *Research Journal of Agriculture and Biological Science*. 2008; 4(6): 685-687.
17. Mitchell JR, Jollow DJ, Potter WZ, Gillette JR, Brrodie BB. Paracetamol induced hepatic necrosis. Protective role of glutethione. *J Pharmacol Exp Ther*. 1973; 187: 211-217.
18. Holt M, Ju C. Drug induced liver injury. In: J Utrecht, editor. *Adverse Drug Reaction*. Springer Heidelberg Dordrecht London. 2009.
19. Walker RM, Racz WJ, McElligot TF. Acetaminophen induced hepatotoxic congestion in mice. *Hepatology*. 1985;5(2): 233-240.
20. Bovek P, Ozdin L, Kuniak L. Effect of Oyster mushroom and on the activities of antioxidative enzymes in rats fed the cholesterol diet. *The Journal of Nutritional Biochemistry*. 1997; 8: 469-471.
21. Fu HY, Shieh DE, Ho CT. Antioxidant and free radical scavenging activities of edible mushrooms. *J Food Lipids*. 2002; 9: 35-43.