

## Case Report

# Bilateral renal angiomyolipoma not associated with tuberous sclerosis: A case report

Khaled A<sup>1</sup>, Arif NUM<sup>2</sup>, Zaman W<sup>3</sup>, Nasir TA<sup>4</sup>

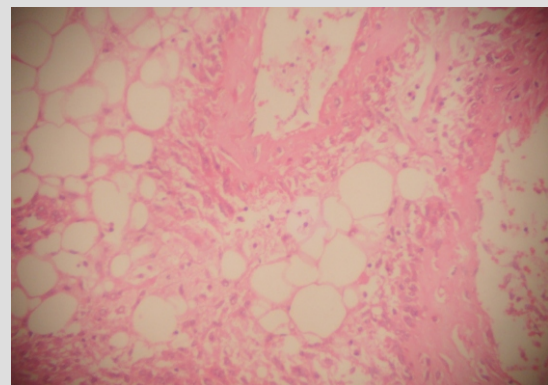
### Abstract

Angiomyolipoma is a tumour composed of varying admixtures of blood vessels, smooth muscles and adipose tissue. Renal angiomyolipoma can be unilateral or bilateral. Bilateral angiomyolipoma has a very strong association with tuberous sclerosis. In non tuberous sclerosis patient, bilateral renal angiomyolipoma is relatively rare. We have described a 49 year old non tuberous sclerosis female presented with bilateral renal angiomyolipoma. Renal angiomyolipoma commonly behaved in a benign way and resection is curative in most of the cases.

**Introduction:** Angiomyolipoma is a tumor composed of varying admixtures of blood vessels, smooth muscle cells and adipose tissue. The lesion should be considered a choriostoma, a disordered arrangement of mature tissue appearing at a site where that tissue does not normally reside. The frequency of angiomyolipoma of kidney varies from 0.7 to 2% of all renal tumors depending upon whether cases were discovered as incidental findings or as symptomatic tumor with or without associated tuberous sclerosis. Patients are predominantly female. The average age at diagnosis is 41 years. Among symptomatic patients, flank pain related to intratumoral hemorrhage is the most common complaint. Angiomyolipoma have been observed in patients with several hereditary disorders including Von Recklinghausen disease, Von Hippel Lindau syndrome, and autosomal dominant polycystic kidney disease. The association is particularly strong with tuberous sclerosis (mental retardation, epilepsy, cutaneous hamartoma, depigmented spots and subungual fibromas of fingers). Angiomyolipoma occurs in 80% of individual with tuberous sclerosis and in most cases it is bilateral. The association is so close that all patient with multiple renal angiomyolipomas should be evaluated for tuberous sclerosis.<sup>1</sup>

**Case report:** A 49 year old non diabetic, hypertensive female came with the complaint of long standing left lumbar pain in the urology outpatient department of Apollo hospital Dhaka. Her physical examination revealed lumps on both side of abdomen extending from hypochondrium to lumbar region, non tender, firm and bimanually palpable. Laboratory examination showed raised serum creatinine, neutrophilia but urine examination was negative for haematuria. Ultrasonogram of whole abdomen showed bilateral renal mass and suggested CT/MRI correlation. MRI revealed bilateral enlarged kidneys with lobulations, loss of architecture and replacement by fat containing mass lesion very much suggestive of bilateral diffuse angiomyolipomatosis of the kidneys. She was screened for other signs of tuberous sclerosis and found to be negative. Her bone scan was also negative. Left sided nephrectomy was done and specimen was sent for histopathological examination. Grossly, the total specimen measured 26x14x7 cm. Cut surface showed a huge mass with yellowish and hemorrhagic areas replacing almost whole of kidney tissue. Sections from

the growth revealed the feature of angiomyolipomas characterized by areas of mature adipose tissue, tortuous thick walled blood vessels, bundles of smooth muscles and perivascular epithelioid cells (Fig: 1).



**Figure 1:** Intimate mixture of thick walled blood vessels, smooth muscles and adipose tissue in angiomyolipoma.

**Discussion:** Angiomyolipomas of the kidneys are hamartomas that may be sporadically found. They are usually asymptomatic and more common than previously appreciated, approaching 13 per 10,000 adults.<sup>2</sup> Moreover, they may be found either in one or in both kidneys. Multiple lesions are found in about one third of the cases and bilateral tumors in 15%. Such tumors may occur in other organs (e.g. liver), in association with renal angiomyolipoma. Our patient had bilateral disease. Angiomyolipomas are much more prevalent in patients with tuberous sclerosis in a percentage as high as 50-80%, accompanied by cysts and occasionally by renal cell carcinoma.<sup>3</sup> Tuberous sclerosis is a multisystem syndrome characterized by neurological symptoms and tumors in multiple organs including kidneys, brain, skin, eyes, heart and lungs. In symptomatic patients, the most common manifestations are pain, retroperitoneal hemorrhage or hypovolaemic shock, haematuria, hypertension, palpable mass, anemia, acute pyelonephritis and fever.<sup>4</sup> The size of the tumor varies and they are classified as small (< 4 cm), medium (4-8 cm) or large (> 8 cm). Renal angiomyolipoma of

1. Specialist, Department of Histopathology, Apollo Hospital Dhaka, 2. Registrar, Department of Urology, Apollo Hospital Dhaka, 3. Sr. Consultant, Department of Urology, Apollo Hospital Dhaka, 4. Sr. Consultant, Department of Histopathology, Apollo Hospital Dhaka

## Bilateral renal

less than 4 cm is generally asymptomatic. Angiomyolipomas greater than 8 cm, responsible for significant morbidity, require treatment, prior to the development of symptoms and potential complications.<sup>5</sup> The large ones are more common in women than in men and their rapid growth during pregnancy suggest that hormones may be responsible for increasing size of angiomyolipoma.<sup>6</sup>

Imaging methods for the diagnosis of renal tumors include US, CT, angiography and MRI. US reveal a high acoustic renal mass. In CT, the excessive fat tissue of the tumor has a characteristic appearance and after intravenous bolus injection of contrast media, the pathological blood circulation of the tumor is evidenced.<sup>7</sup> Typical angiomyolipomas are benign tumors. However, the smooth muscle component is troublesome because it may exhibit hypercellularity, marked pleomorphism and moderate mitotic activity. These features may prompt a mistaken diagnosis of leiomyosarcoma. In addition, the regional lymph nodes may be involved, but it is generally regarded as an expression of multicentricity rather than true metastasis. Furthermore, they may show resemblance to renal cell carcinoma because of their yellow color, intratumoral hemorrhage and frequent extra renal growth. The percutaneous needle aspiration biopsy under US, CT or MRI control, usually confirms the diagnosis of angiomyolipomas, allowing differentiation of this entity from other renal tumours.<sup>8,9</sup>

The management approach of angiomyolipomas is surgical resection, which should be aimed at parenchyma preservation. This can be effectively accomplished by limited surgery, without postoperative dysfunction or need for dialysis, even in solitary kidney.<sup>10,11</sup> Furthermore, complete or selective renal embolization is a viable alternative to surgery, mainly in patients with poorly functioning kidneys who present with pain or bleeding, and in those who are poor operative candidates. The embolization is safe, reliable and

minimally invasive with few long-term sequelae, and it is well tolerated.<sup>12,13</sup> In conclusion, current management options of renal angiomyolipomas include observation, embolization and partial or total nephrectomy. Recommendations of treatment are usually based on the symptoms observed and the size of the lesion.

In conclusion, we have described a bilateral renal angiomyolipoma in a non tuberous sclerosis patient along with general characteristics of renal angiomyolipoma.

### References:

1. Murphy WM, Beckwith JB, Farrow GM, editors. Tumors of the kidney, bladder, and related urinary structures: AFIP fascicles: 1994. p. 161-178.
2. Edle JN. Angiomyolipomas of kidney. *Semin Diagn Pathol.* 1998;15:21-40.
3. Neuman HP, Schwarzkopf G, Henske EP. Renal angiomyolipomas, cysts and cancer in tuberous sclerosis complex. *Semin Pediatr Neurol.* 1998;5:269-75.
4. Benchekroun A, Lechkar A, Soumana A. Renal angiomyolipoma. A propos of 11 cases. *Ann Urol.* 1998;32:128-32.
5. Dickinson M, Ruckle H, Beagher M, Headley HR. Renal angiomyolipoma: optimal treatment based on size and symptoms. *Clin Nephrol.* 1998;49:281-6.
6. Kessler OJ, Gillon G, Neuman M, Engelstein D. Management of renal angiomyolipomas: analysis of 15 cases. *Eur Urol.* 1998;33:572-5.
7. Yakamoto S, Nakamura K, Kawanami S, Aoki T, Watanabe H, Nakata H. Renal angiomyolipoma: evolutionary changes of its internal structure on CT. *Abdom Imag.* 2000;25:651-4.
8. Fazeli-Matin S, Novick AC. Nephron-sparing surgery for renal angiomyolipoma. *Urology.* 1998;52:577-83.
9. Metro MJ, Ramchandani P, Banner MP. Angiomyolipomas of the renal sinus: diagnosis by percutaneous biopsy. *Urology.* 2000;55:286-288.
10. Yip KH, Peh WC, Tam PC. Spontaneous rupture of renal tumors: the role of imaging in diagnosis and treatment. *Br J Radiol.* 1998;71:146-54.
11. Smith DC. Treatment of renal angiomyolipoma. *N Engl J Med.* 1998;339:1400.
12. Hom D, Eily D, Lumerman JH, Siegel DN, Goldfischer ER, Smith AD. Complete renal embolization as an alternative to nephrectomy. *J Urol.* 1999;161:24-7.
13. Kehagias D, Mourikis D, Kousaris M, Vlahos L. Management of renal angiomyolipoma by selective arterial embolization. *Urol Int.* 1998;60:113-7.