



## Case Report

# Disseminated Subcutaneous Rhinosporidiosis : A Case Report

Md. Moniruzzaman Sarker<sup>1</sup>, A. K. M. Golam Kibria<sup>2</sup>, Md. Manzurul Haque<sup>3</sup>

### Abstract

Rhinosporidiosis is a chronic granulomatous infection that frequently involves the nose and nasopharynx, and occasionally affects the other areas of the body. We report a 40-year-old patient who had disseminated subcutaneous rhinosporidiosis. The patient presented with multiple subcutaneous lesions over the different parts of the body during last five years. He had a past history of a lesion in his right nostril with nasal blockage and haemorrhage ten years back. In our surgical unit the patient had been subjected to elective operation with excision of subcutaneous lesions. The histopathology report of excised subcutaneous lesions was rhinosporidiosis. The patient is being followed up postoperatively.

TAJ 2006; 19(1): 31-33

### Introduction

Rhinosporidiosis is a chronic granulomatous disorder caused by *Rhinosporidium seeberi*. The organism has never been successfully isolated *in vitro*, and its taxonomic position is unclear. Molecular biological techniques have more recently demonstrated that this organism is an aquatic protistan parasite. It is currently included in a new class, the *Mesomycetozoa*. Rhinosporidiosis, initially described by Seeber in 1900 in an individual from Argentina. The disease is endemic in India and Sri Lanka but has also been reported from the United States, South America, and Iran<sup>1,2,3</sup>. It is more common in adult men and is possibly transmitted to humans by direct contact with spores through dust, through infected clothing or fingers, and through swimming in stagnant waters<sup>2</sup>. Rhinosporidiosis frequently involves the nose and nasopharynx (70%). The conjunctiva and the lacrimal sac are

involved in 15% of cases. Occasionally, rhinosporidiosis affects the lips, palate, uvula, maxillary antrum, epiglottis, larynx, trachea, bronchus, ear, scalp, vulva, vagina, penis, rectum, and the skin<sup>4</sup>. Dissemination of infection has been described very rarely. This report describes a case of disseminated subcutaneous rhinosporidiosis.

### Case report

A 40-year-old man was admitted into surgery department of Rajshahi Medical College Hospital in March, 2007 with a 5-year history of multiple subcutaneous lesions in the different parts of the body. First he noticed a swelling in the left side of front of the chest and subsequently in the both legs, left forearm, left gluteal region and right thigh. All the swellings had been gradually increasing in size and were painless. He has a history of regular swimming in ponds in his village. He had no history of anorexia, weight loss, chest pain, cough, haemoptysis or bone pain etc.

<sup>1</sup> Registrar, Department of Surgery, Rajshahi Medical College Hospital, Rajshahi.

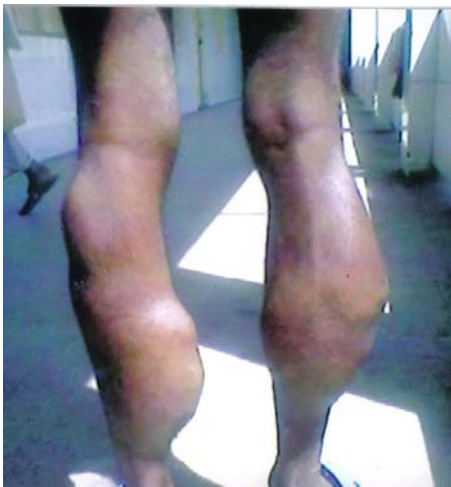<sup>2</sup> Assistant Professor, Department of Surgery, Rajshahi Medical College, Rajshahi.

<sup>3</sup> Associate Professor, Department of Surgery, Rajshahi Medical College, Rajshahi.

The patient had a past history of a lesion in his right nostril with nasal blockage and haemorrhage ten years back. He had been treated and operated in a tertiary hospital. An otolaryngologist excised the nasal lesion. Histopathology report of the excised mass was not available with the patient.

On examination, multiple subcutaneous lesions were detected over different parts of the body. The larger two were located over left and right legs (about 24x18cm and 20x18cm respectively). All the lesions were non-tender and firm in consistency. The margins were more or less well defined and surfaces were lobulated. The overlying skin was free and all the lesions were mobile in all directions. There was no regional lymphadenopathy. Distal pulses were normal and no evidence of neurological deficit was detected. Examination of the nose and palate were normal. Other systemic examinations revealed no abnormality.

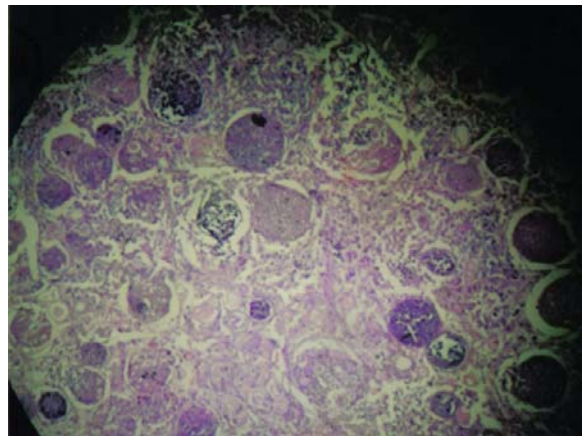
FNAC of the left forearm and leg swellings were done in the pathology department of Rajshahi Medical College. But the reports were inconclusive. Subsequently a moderate size lesion over the left forearm was excised completely and was sent for histopathological examination. Histopathology report revealed multiple mature and immature cysts (sporangia) packed with spores. There were chronic inflammatory cells infiltrating into normal tissue. The histopathological diagnosis was rhinosporidiosis.



*Fig-1: Subcutaneous lesions on both legs*

As a part of academic exercise two larger leg lesions were also excised on next available

operation schedule and the tissue was sent for histopathological examination. The report was rhinosporidiosis again. The other swellings were not excised because they were very small in size. The post operative period was uneventful. The final diagnosis was disseminated subcutaneous rhinosporidiosis. The patient was put on dapsone 100mg per day orally. He was advised follow-up at monthly interval.



*Fig-2: Photomicrograph showing multiple mature and immature cysts (sporangia) packed with spores.*

## Discussion

Rhinosporidiosis is usually limited to the surface epithelium of nasal mucosa, but, rarely, wide dissemination with visceral involvement can occur<sup>5</sup>. Nasal lesion presenting as a painless, friable, polypoidal growth, which may hang anterior to the nares or posteriorly into the pharynx. The lesions are pink or purple-red and studded with minute white dots, which are sporangia containing the spores<sup>1,3</sup>. Nasal obstruction and bleeding are the most common symptoms<sup>4</sup>.

Disseminated subcutaneous rhinosporidiosis is very rare. The organism may be disseminated through haematogenous route. To the best of our knowledge this is the first case reported in Bangladesh with disseminated subcutaneous rhinosporidiosis. It is very much probable that our patient had an attack of nasal rhinosporidiosis ten years back, which had been treated by the ENT specialist. But before being radically treated it had already been disseminated through haematogenous route.

The diagnosis can easily be clinched by performing a Giemsa stained imprint smear<sup>2</sup>. Fine-needle aspiration cytology from lesion may be an additional diagnostic tool<sup>1</sup>. We have done the fine-needle aspiration cytology from the lesions in this case, but the report was inconclusive. Probably owing to very uncommon presentation. Histopathology of rhinosporidiosis reveals enormous number of mycotic elements. These elements consist of sharply defined globular thick-walled cysts (sporangia), which contain numerous rounded endospores. Immature and collapsed sporangia are also present. The reported case showed the similiar histopathological features.

Treatment of rhinosporidiosis is a problem yet unsolved. Surgical removal and electrodesiccation are the treatments of choice<sup>5</sup>. Dapsone may arrest the maturation of sporangia and accelerate degenerative changes in them. The effete organisms are then removed by an accelerated granulomatous response<sup>4</sup>. In this case surgical excision of two larger leg lesions and forearm lesion were done with electrocoagulation of the lesional bases. Patient was put on dapsone 100mg per day orally during postoperative period and is continued.

## Acknowledgement

We are thankful to the Director of Rajshahi Medical College Hospital for allowing us to publish this case report. We are also thankful to Dr. Israt Faisal, Dr. Mobinul Islam, and Dr. Abdullah Al Muti for their cordial support.

## Reference

1. Ramanan C, Ghorpade A. Giant cutaneous rhinosporidiosis. *Int J Dermatol* 1996 Jun; 35:441-442.
2. Kamal MM, Luley AS, Mundhada SG, Bohate SK. Rhinosporidiosis. Diagnosis by scrape cytology. *Acta Cytol* 1995 Sep-Oct; 39(5):931-935.
3. Thappa DM, Venkatesan S, Sirka CS, Jaisankar TJ, Gopalkrishnan, Ratnakar C. Disseminated cutaneous rhinosporidiosis. *J Dermatol* 1998 Aug; 25(8): 527-532.
4. Kumari R, Laxmisha C, Thappa DM. Disseminated cutaneous rhinosporidiosis. *Dermatology Online Journal* 2005; 11(1):19.
5. Vijaikumar M, Thappa DM, Karthikeyan K, Jayanthi S. Verrucous lesion of the palm. *Postgrad Med J* 2002 May; 78(919):302,305-306.

All correspondence to:  
Md. Moniruzzaman Sarker  
Registrar, Department of Surgery  
Rajshahi Medical College Hospital, Rajshahi