

Article

Developmental trajectory of the prenatal lymphoid organs in native chickens: a macro anatomical study

Md. Nabiul Islam^{1*}, Md. Zahirul Islam Khan², Mir Rubayet Jahan² and Koh Shinoda¹

¹Division of Neuroanatomy, Graduate School of Medicine, Yamaguchi University, Ube, Yamaguchi 755-8505, Japan

²Department of Anatomy and Histology, Faculty of Veterinary Science, Bangladesh Agricultural University, Mymensingh-2202, Bangladesh

*Corresponding author: Dr. Md. Nabiul Islam, Assistant Professor, Division of Neuroanatomy, Graduate School of Medicine, Yamaguchi University, Ube, Yamaguchi 755-8505, Japan. Phone: +81-836-22206; Fax: +81-836-22205; E-mail: nabiul@yamaguchi-u.ac.jp

Received: 28 November 2017/Accepted: 24 December 2017/ Published: 28 December 2017

Abstract: Native chickens of Bangladesh are scavenging in nature. In our previous studies, we have histologically and immunohistochemically examined the ontogeny of lymphoid organs of native chickens of Bangladesh in prenatal stages. To date, the study on gross anatomical development of prenatal lymphoid organs is lacking. In the present study, detailed macro-anatomical development of prenatal lymphoid organs of native chickens were examined during different embryonic stages of development, which was conducted in the laboratory of the department of Anatomy and Histology, Bangladesh Agricultural University. In the present study, thymus was first identified by the 10 days of incubation (ED 10) as a chain at the both side of the neck. Bursa of Fabricius and spleen were also first found to develop at ED 10. While comparing with the prenatal development of lymphoid organs of native chickens with that of previously studied hybrid chickens, the native chickens' lymphoid organs were found to develop earlier. Taken together with our previous results, the developmental trajectory data of the present study are first to clarify that the immune system of native chickens are being prepared earlier to face the scavenging environment after hatching.

Keywords: lymphoid organs; native chickens; gross anatomy; embryo

1. Introduction

The chickens of Bangladesh are scavenging in nature and they are continuously exposed to a wide spectrum of potential environmental immunomodulators including physical and chemical factors as well as various microorganisms and antigenic particles, whether occurring naturally or deliberately introduced. In addition, temperature, housing, air quality, diet, environment contaminants, feed additives, therapeutics and vaccines are significant categories of immunomodulators. To cope with the diversity of potentially harmful agents on one hand, and to mount a protective immune response on the other, scavenging chickens possess an array of humoral and cell mediated immune mechanisms that destroy infected cells or pathogens and mount an adaptive immune response. For this, immunocompetent defense system is the decisive prerequisite (Jeurissen *et al.*, 1994; Khan *et al.*, 2007, 2008; Islam *et al.*, 2012, 2013). The lymphoid tissue of the chicken is divided into "central" and "peripheral" ones. The primary site for the development of lymphocytes is central one, e.g., the bursa of Fabricius and thymus. The peripheral or secondary lymphoid tissues apparently depend on the central lymphoid tissue for their origin, development and function. In chickens the peripheral lymphoid tissue includes the spleen and all the mucosa-associated lymphoid tissues including respiratory tract genitourinary tract, alimentary tract with cecal tonsils and head associated lymphoid tissues which consists of Harderian gland, lacrimal glands and duct, eyelid conjunctivas and nasal cavity mucosa (Jeurissen *et al.*, 1994; Islam *et al.*, 2008, 2012).

Although the native chickens of Bangladesh are scavenging in nature and native chickens represent more than 70% of the total poultry where more than 74% households keep these birds in Bangladesh (Rahman *et al.*, 2003), to date, most investigations on lymphoid organs were performed in high yielding birds (Bejdic *et al.*, 2017; Khan *et al.*, 1996, 1997, 2007, 2008; Jeurissen *et al.*, 1992, 1994, 1998). To the best of our knowledge, relatively little information is available on the development of lymphoid organs of native chickens of Bangladesh. Although in our very recent studies we have reported histologically and immunohistologically that immune cells were developed earlier in the lymphoid organs of native chickens than that of hybrid chickens, to cope with the scavenging environment after hatching (Islam *et al.*, 2012, 2013), it is still unknown that whether the lymphoid organs are developed earlier or not. To answer this question, the present research work has been designed to understand the gross anatomical developmental trajectory of lymphoid organ of native chickens of Bangladesh.

2. Materials and Methods

2.1. Collection of embryo

We have collected fifty apparently healthy eggs from the native chickens. Very small (<40g) and very large (>50g) eggs were rejected. The eggs were stored in the laboratory of the Department of Anatomy and Histology, Mymensingh, Bangladesh for 6 days at 15°C. All the selected eggs were fumigated with formaldehyde gas and incubated in an electric egg incubator at 37°C and at 55–60% relative humidity (Yoshimura *et al.*, 2009; Ozurlu *et al.*, 2010). The lymphoid tissues (bursa of Fabricius, thymus and spleen) were dissected out from the embryo using microscope at embryonic day 10 (ED 10) which was followed by ED 12, ED 14 and ED 20. A total of 20 embryos were used for the present study (five embryos for each day of sample collection). Experiments were carried out in accordance with the guidelines laid down by the National Institute of Health (NIH) in the USA and in accordance with Bangladesh Veterinary Council (BVC) laws and regulations.

2.2. Gross anatomical investigation

The gross anatomical investigations were performed accordingly our previous study (Islam *et al.*, 2006; Jahan *et al.*, 2009). First, embryonic lymphoid organs were examined *in situ*, then immediately after collection of thymus, bursa of Fabricius and spleen, the gross morphology were studied including location, color and size of the gland.

2.3. Photographs

Photographs were taken using a digital camera (Nikon, Japan) for the present study. All images were transferred to Adobe Photoshop Elements 15 (Adobe Systems, Inc., San Jose, CA, USA) and the brightness and contrasts were adjusted (Jahan *et al.*, 2015; Islam *et al.*, 2017). No other adjustment was made.

3. Results

3.1. Gross anatomical development of prenatal bursa

The bursa of fabricius of native chickens was a single lympho-epithelium organ. The organ appeared as a dorso-medial diverticulum of the proctodium, being smooth and globular in shape and yellowish white in color. The embryonic bursa of native chickens was found to develop from embryonic day 10 and became a fully differentiated immune organ on embryonic day 14 (Figure 1).

3.2. Gross anatomical development of prenatal thymus

The thymus was consisting of a series of irregular shaped lobes located along the jugular vein on both sides of the neck of embryonic native chickens. About 6-8 flattened ovoid lobes of varying shaped of thymic lobule could not be counted until embryonic day 20 (ED 20) (Figure 2), however, these lobes were visible clearly as a chain on both side of neck from embryonic day 10. They appeared pink in the fresh state and all the lobes were longer than they were broader. The cranial end of each string of lobes was found at the level of the third cervical vertebra and extends caudally to the region of the thyroid gland within the thoracic cavity. The lateral surface of each lobe was convex while the medial surface was slightly concave or just flat in few cases. The blood vessels supplying each lobe penetrated from the medial surface.

3.3. Gross anatomical development of prenatal spleen

The spleen was rounded in shape on embryonic day 10 of native chickens in the present study. It was located close to the right side of the junction between the proventriculus and the gizzard (Figure 3). The spleen was pinkish brown in color in the fresh specimen but usually pale colored after fixation. In the fresh specimen, the

whole organ was smoothly round with a hilus on the ventral aspect where the vessels entered and leave. The ventral surface was flattened horizontally on the midline while the dorsal surface was convex. The whole organ had a thin tough capsule covering the surface except at the hilus.

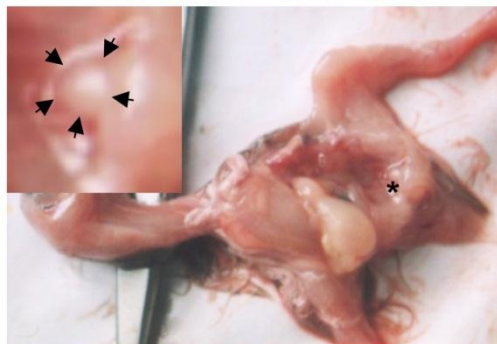


Figure 1. The embryonic bursa of Fabricius of native chickens at embryonic day 14. Inset is the enlargement of * indicating fully developed bursa.

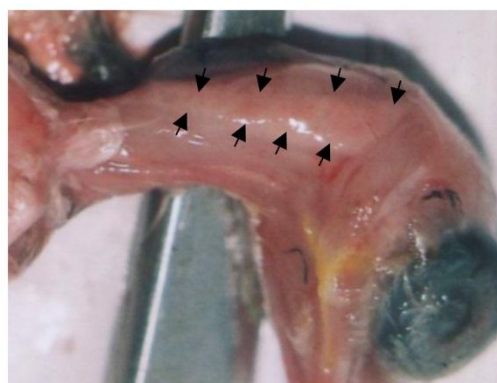


Figure 2. The embryonic thymus of native chickens at embryonic day 20. Arrowheads indicating the lobes of thymus arranged as a chain.

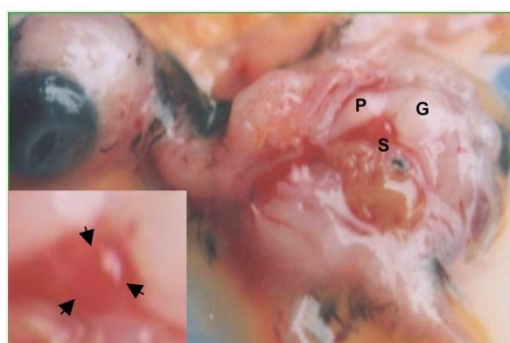


Figure 3. The embryonic spleen of native chickens at embryonic day 20. Fully developed spleen (s) was visible at the right side of the junction between the proventriculus (p) and the gizzard (g). Inset is the enlargement of s, indicating fully developed spleen.

4. Discussion

The present study employing gross anatomical investigation, is the first to clarify the developmental trajectory of the major lymphoid organs of native chickens of Bangladesh. We demonstrated that the thymus, bursa of Fabricius and spleen were found to develop at ED 10. These results were very much similar to the study of Payne (1971) in high yielding birds. The number of lobes of embryonic thymus of native chickens were similar as that of high yielding birds (Payne, 1971) and Onyeausi (1994) in guinea fowl but varied to the report of Hohn (1956), who stated that the duck and goose had about 10 lobes each. Gross anatomical dynamics of the

developing bursa of Fabricius was very much similar to the observation of Gasc and Stumpf (1981), In addition, the shape, position and color of embryonic spleen were also similar to that of hybrid chicken (Hodges, 1974; King, 1975) and guinea fowl (Onyeanus, 2006).

The most interesting results we have found in the present study is that bursa of Fabricius of native chickens were fully differentiated on ED 14 that is earlier than that of high yielding White Leghorn birds where bursa became fully differentiated immune organ on ED 15 (Gasc and Stumpf, 1981). These results indicating that the lymphoid organs were matured earlier in native chickens than that of high yielding birds. These findings were in line with our previous studies where we have shown that the cluster of lymphocytes appears in the embryonic lymphoid organs of native chickens relatively earlier than that of high yielding birds (Islam *et al.*, 2012) and the appearance of Immunoglobulin-containing plasma cells (IgA, IgM, IgG) was also earlier in all of the lymphoid organs of native chickens than that of other high yielding birds (Islam *et al.*, 2013).

5. Conclusions

Taken together with our previous results, our present results may provide the first basic macro-anatomical data that the immune system of native chickens are being prepared earlier to face the scavenging environment after hatching.

Conflict of interest

None to declare.

References

- Bejdic P, R Avdic, L Amidzic, V Cutahija, N Hadziomerovic, A Katica and N Mlaco, 2017. Ultrastructural of plasma cells in Harderian gland of laying hen. *Antat Histol Embryol.*, 00: 1-5.
- Gasc JM and WE Stumpf, 1981. The bursa of Fabricius of the chicken embryo: localization and ontogenic evolution of sex-steroid target cells. *J Embryol Exp Morphol.*, 63: 225-231.
- Hodges RD, 1974. The histology of the fowl. In: *The digestive system Academic Press, London, New York, San Francisco.* 35-108.
- Hohn, EO, 1956. Seasonal recrudescence of the thymus in adult birds. *Canadian Journal of Biochemistry and Physiology*, 34: 90-101.
- Islam MN, MZI Khan, MR Jahan and MR Islam, 2006. Comparative histomorphology of the gastrointestinal tract's mucosa of broilers and native chickens of Bangladesh. *J. Bangladesh Soc. Agric. Sci. Technol.*, 3: 57-60.
- Islam MN, MZI Khan, MR Jahan, MR Karim and Y Kon, 2008. Comparative studies of Mucosa and Immunoglobulin-containing Plasma cells in the gastrointestinal tract of Broiler and native Chickens of Bangladesh. *J. Poult. Sci.*, 45: 125-131.
- Islam MN, Khan MZI, Jahan MR, Fujinaga R, Yanai A, Kokubu K, Shinoda K, 2012. Histomorphological study on prenatal development of the lymphoid organs of native chickens of Bangladesh. *Pak. Vet. J.*, 32:175-178.
- Islam MN, MZI Khan, MR Jahan, R Fujinaga, K Shinoda, 2013. Ontogenic development of immunoglobulins (Igs)-positive lymphocytes in the lymphoid organs of native chickens of Bangladesh. *Int. J. Vet. Sci. Med.*, 1: 96-101.
- Islam MN, Y Takeshita, A Yanai, A Imagawa, MR Jahan, G Wroblewski, J Nemoto, R Fujinaga and K Shinoda, 2017. Immunohistochemical analysis of huntingtin-associated protein 1 in adult rat spinal cord and its regional relationship with androgen receptor. *Neuroscience*, 340:201-217.
- Jahan MR, MN Islam and MZI Khan, 2009. Gross and biometrical study of the Harderian gland in adult native chickens of Bangladesh. *Int J Biol Res.*, 7: 31-34.
- Jahan MR, Kokubu K, Islam MN, C Matsuo, Y Yanai, G Wroblewski, R Fujinaga and K Shinoda, 2015. Species difference in androgen receptor expression in medial preoptic and hypothalamic areas of adult male and female rodents. *Neuroscience*, 284:943-961
- Jeurissen SHM, E Claassen and EM Janse, 1992. Histological and functional differentiation of non-lymphoid cells in the chickens spleen. *Immunology*, 77: 75-80.
- Jeurissen SHM, L Vervelde and EM Janse, 1994. Structure and function of lymphoid tissues of the chicken. *Poultry Sci. Rev.*, 5: 183-207.
- Jeurissen SHM and EM Janse, 1998. The use of chicken-specific antibodies in veterinary research involving three other avian species. *Vet. Q.*, 20:140-143.
- Khan MZI, Y Hashimoto Y Iwami and T Iwanaga, 1996. Hormonal regulation of T-cell subsets in the oviduct: An immunohistochemical study using sex-hormone- treated chickens. *J. Vet. Med. Sci.*, 58: 1161-1167.

- Khan MZI, Y Hashimoto, Y Iwami and T Iwanaga, 1997. Postnatal development of B-lymphocytes and immunoglobulin-containing plasma cells in the chicken oviduct: studies on the cellular distribution and influence of sex hormones. *Vet. Immunol. Immunopathol.*, 56: 329-338.
- Khan MZI, MR Jahan, MN Islam, Z Haque, MR Islam and Y Kon, 2007. Immunoglobulin (Ig)-containing plasma cells in the Harderian gland in broiler and native chickens of Bangladesh. *Tissue Cell.*, 39: 141-149.
- Khan MZI, SH Akter, MN Islam, MR Karim, MR Islam and Y Kon, 2008. The Effect of Selenium and Vitamin E on the Lymphocytes and Immunoglobulin-containing Plasma cells in the Lymphoid organ and Mucosa-Associated Lymphatic Tissues of Broiler Chicken. *Anat. Histol. Embryol.*, 37: 52-59.
- King AS and J McLelland, 1975. *Outlines of Avian Anatomy*. Ballie`re Tindal, London, 104-125.
- Onyeausi BI, JC Onyeausi, AN Emma and CD Ezeokoli, 1994. The Thymus of the Guinea Fowl from the eighteenth day of incubation until maturity. *Anat. Histol. Embryol.*, 23:320-329.
- Onyeausi BI, 2006. The Guinea Fowl spleen at embryonic and post-hatch periods. *Anat. Histol. Embryol.*, 35: 140-143
- Oznurlu Y, I Celik, TT elatar and E Sur, 2010. Histochemical and histological evaluations of the effects of high incubation temperature on embryonic development of thymus and bursa of Fabricius in broiler chickens. *Br Poult Sci.*, 51: 43-51.
- Payne LN, 1971. The lymphoid system. In: *Physiology and Bio-chemistry of the domestic fowl vol. 2* (Bell, D.J., and Freeman, B.M. eds.) Veterinary Academic Press, London and New York. 985-1037.
- Rahman ML, MR Islam, M Asaduzzaman and MZI Khan, 2003. Lymphoid tissues in the digestive tract of Deshi Chicken (*Gallus domesticus*) in Bangladesh. *Pakistan Journal of Biological Sciences*, 6: 1145-1150.
- Yoshimura Y, C Tsuyuki, K Subedi, H Kaiya, T Sugino and N Isobe, 2009. Identification of ghrelin in fertilized eggs of chicken. *J. Poult. Sci.*, 46: 254-259.