

## Kikuchi-Fujimoto Disease: A Diagnostic Dilema

\*SMK Nahar Begum<sup>1</sup>, MMR Siddiqui<sup>2</sup>, AS Arif<sup>3</sup>, MA Kahhar<sup>4</sup>

<sup>1</sup>Dr. SM Khodeza, Nahar Begum, Associate Professor of Pathology, Anwer Khan Modern Medical College, Dhaka

<sup>2</sup>Dr. Md. Mahmudur Rahman Siddiqui, Assistant Professor of Medicine, Anwer Khan Modern Medical College, Dhaka

<sup>3</sup>Dr. Abdus Salam Arif, Professor of Surgery (c.c), Anwer Khan Modern Medical College, Dhaka

<sup>4</sup>Prof. Dr. Md. Azizul Kahhar, Professor of Medicine, Dhaka Medical College, Dhaka

\*Corresponding Author

### ABSTRACT

Fujimoto (KD) disease or histiocytic necrotizing lymphadenitis is a rare, benign, self limiting cervical lymphadenitis of unknown etiology. Since Tubercular lymphadenopathy is the commonest cause for chronic cervical lymphadenopathy in developing and tropical country like Bangladesh. Occasionally it is misdiagnosed as TB and subsequently shows unresponsiveness to ATT. As a result the morbidity increases and cost of antitubercular treatment (ATT) in wrong diagnosed case is enormous. We report a similar case of misdiagnosis. We report a 26 year old lady who reported with history of right sided neck pain and fever since last 2 months. Clinical examination revealed enlarged right sided lymph nodes in the neck. Fine needle aspiration cytology revealed features suggestive of granulomatous lymphadenitis. The case was suspected to be tuberculosis and anti-tubercular therapy (ATT) was started immediately. Since the patient did not respond, lymph node biopsy was done and the histological features suggested the diagnosis of Kikuchi's disease. She did well after recommended treatment.

**Keywords:** Kikuchi-Fujimoto disease (KFD), Histiocytic Necrotizing Lymphadenitis, Systemic Lupus Erythematosus (SLE), Karyorrhexis; Chronic cervical lymphadenitis. Anti-tubercular therapy (ATT)

### Introduction

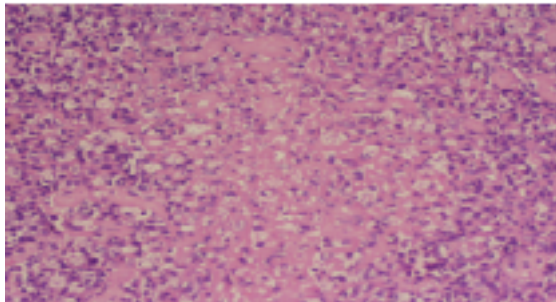
Kikuchi-Fujimoto disease was first described independently by Kikuchi<sup>1</sup> and Fujimoto et al.<sup>2</sup>, as lymphadenitis with focal proliferation of reticulum cells accompanied by numerous histiocytes and extensive nuclear debris. The disease is a benign and self limiting syndrome characterized by regional lymphadenopathy with tenderness, predominantly in the cervical region, usually accompanied with mild fever and night sweats. The clinical and histological features suggest that this disorder represents a common pattern of response to a variety of etiologies<sup>3</sup>. Histopathology and sometimes immunohistochemistry are necessary for the diagnosis. We report a case of a female suffering from chronic cervical lymphadenopathy, taking anti tubercular treatment (ATT) with no response. Histopathology finally reversed the diagnoses and Kikuchi-Fujimoto disease was confirmed and treated successfully.

AKMMC J 2014; 5(2): 51-53

### Case report

A 27-year-old female presented to our hospital with 2 months history of swellings in the neck, fever, rash, mild chills and night sweats. There was no weight loss. Routine blood tests and fine needle aspiration cytology were performed. FNAC was done in another hospital where the features were suggested as tubercular lymphadenitis. She was on ATT as advised by a local practitioner with no response for last 1 month. On physical examination, her left cervical lymph nodes were significantly enlarged, mild tender, firm, and discrete. The LNs were multiple, 1-3 cm in diameter in left supraclavicular and jugolodiagastric regions. Few erythematous macules were noted symmetrically in both upper and lower extremities. Her temperature was 101°F and weight 42 Kg. Examination of other systems was normal. Haematology showed mild neutropenia with normocytic red cell indices (Hb - 9.2 g/dl., MCV - 93.2 fl., Platelete count - 286

10<sup>9</sup>/l). Erythrocyte sedimentation rate (ESR) was 38 mm/h and C-reactive protein was 29. Mantoux test (MT) 14 mm after 72 hours and normal chest skiagram (CXR). Excisional biopsy of a lymph node was done under local anesthesia. The histopathology demonstrated focal necrosis surrounded by karyorrhectic debris, histiocytes and plasmacytoid lymphocytes (Fig.). Kikuchi-Fujimoto disease (KFD) was diagnosed. The patient had a recovery after 21 days of supportive care.



**Fig 1:** Karyorrhectic debris and histiocytes in kikuchi's lymphadenitis

### Discussion

Kikuchi-Fujimoto is also called histiocytic necrotizing lymphadenitis, often presents as cervical lymphadenopathy in young females which may be tender and can be accompanied by fever, upper respiratory tract symptoms. Unilateral and posterior cervical lymph nodes are the commonest to be involved<sup>4</sup>. The course of the disease is variable, but usually self-limiting. Less common manifestations are in the form of axillary and mesenteric lymphadenopathy, splenomegaly, parotid gland enlargement, arthralgias, myalgias, aseptic meningitis<sup>5</sup>, bone marrow haemophagocytosis<sup>6</sup> and interstitial lung disease<sup>7</sup>. The cutaneous lesions include erythematous macules, papules, plaques and nodules<sup>8</sup>.

The exact etiology of Kikuchi's disease is not known. Viral agents such as Epstein barr virus (EBV), Human immunodeficiency virus (HIV), Herpes simplex virus, Human T lymphocytic virus 1 (HTLV1) and Parvovirus B19 have been suggested as possible etiological agents, but none have been confirmed so far. Toxoplasma and other bacterial agents like *Yersinia enterocolitica*, *Bartonella*, *Brucella* have also been implemented<sup>9</sup>.

An autoimmune mechanism has also been proposed because KFD is seen in conjunction with Systemic lupus erythematosus (SLE). The strongest link is with SLE, although the exact nature of the association has not yet been established<sup>8</sup>. Since some patients of KD have later developed SLE and since the necrotic lesion in the lymph node is similar, it has been suggested that necrotizing histiocytic lymphadenitis may be an initial manifestation of SLE<sup>10</sup>.

Clinically Kikuchi's disease may mimic systemic lupus erythematosus (SLE) or lymphoma (especially T-cell non-Hodgkins lymphoma) as both these diseases can present with lymphadenopathy and fever and the skin lesions of Kikuchi's disease patients can resemble those seen in SLE. Careful histopathologic examination will thus help us distinguish KFD from other diseases. Histological feature which helps in the differentiation of KFD from the lymphadenopathy of systemic lupus erythematosus is almost total absence of plasma cells in the involved nodal tissue. Moreover appropriate serologic tests should be done to exclude systemic lupus erythematosus<sup>11</sup>. Antinuclear antibodies (ANA) and anti-DNA antibodies were done in our patient and were negative. Features that distinguish KFD from malignant lymphoma include incomplete architectural effacement with patent sinuses, presence of numerous reactive histiocytes, relatively low mitotic rates, absence of Reed-Sternberg cells<sup>12</sup>. Patients with this Kikuchi-Fujimoto disease may develop anemia, leucopenia, atypical lymphocytosis and raised ESR<sup>13</sup>.

Fine-needle aspiration cytology (FNAC) can be used to make cytologic diagnosis. But one may sometimes misdiagnose the case as nonspecific reactive lymphadenitis or granulomatous lymphadenitis. In a typical case however; characteristic cytologic findings in KD include crescentic histiocytes, plasmacytoid monocytes, and extracellular debris<sup>14</sup>. The usefulness of fine-needle aspiration cytology (FNAC) to establish a cytologic diagnosis of KFD has been limited and, in general, it is less useful than excisional LN biopsy, the overall diagnostic accuracy of FNAC for KFD has been estimated at 56.3%<sup>15</sup>. Therefore excisional lymph node biopsy should be mandatory if clear-cut clinical and cytologic KFD findings are absent.

The histology of KD is distinctive. There are patchy, irregular paracortical areas of coagulative necrosis without a polymorphonuclear leucocyte infiltration. The necrotic areas show prominent karyorrhectic debris, immunoblasts, histiocytes with characteristic C-shaped nuclei, some of which contain cellular debris, and plasmacytoid T-cells/monocytes<sup>16</sup>.

In general, immunohistochemistry shows a positive immunostaining by antibodies Mac 387, KP1 (CD 68) and Ki M1P. In addition, a variable number of T-cells immunostained by antibody MT1 (CD 43) or UCHL1 and (CD 45RO). CD8+ T cells were identified by antibody CD8/144 in all lesions<sup>13</sup>. Immunohistochemistry clearly differentiates this KD from other chronic cervical lymphadenopathies.

### Conclusion

Although the incidence of Kikuchi-Fujimoto disease is rare, this disorder must be considered among the differential diagnosis when a young female patient presents with fever and cervical lymphadenopathy. Clinically Kikuchi's disease may mimic tuberculosis, lymphoma or systemic lupus erythematosus (SLE). Therefore a careful histopathological examination is necessary in arriving at the diagnosis. In our case, it helped in differentiating Kikuchi-Fujimoto disease from tubercular lymphadenopathy and guided to stop the non responsive antitubercular treatment. Patient responded well of supportive treatment and recovered in 3 weeks.

Conflict of Interest: We have no conflict of interest.

### References

1. Kikuchi M. Lymphadenitis showing focal reticulum cell hyperplasia with nuclear debris and phagocytes. *Acta Hematol Jpn* 1972; 35:379-80
2. Fujimoto Y, Kozima Y, Yamaguchi K. Cervical subacute necrotizing lymphadenitis. A new clinicopathological entity. *Naika* 1972; 30: 920-927.
3. Onciu M, Medeiros LJ. Kikuchi-Fujimoto lymphadenitis. *Adv Anat Pathol* 2003; 10(4):204-211.
4. Poulouse V, Chiam P, Poh WT. Kikuchi's disease: a Singapore case series. *Singapore Med J* 2005; 46(5):229-232.
5. Sato Y, Kuno H, Oizumi K. Histiocytic necrotizing lymphadenitis (Kikuchi's disease) with aseptic meningitis. *J Neurol Sci* 1999; 163(2):187-191.
6. Mahadeva U, Allport T, Bain B, et al. Haemophagocytic syndrome and histiocytic necrotizing lymphadenitis (Kikuchi's disease). *J Clin Pathol* 2000;53(8):636-638.
7. Sharma OP. Unusual systemic disorders associated with interstitial lung disease. *Curr Opin Pulm Med* 2001; 7(5): 291-294.
8. Yasukawa K, Matsumura T, Sato-Matsumura KC, et al. Kikuchi's disease and the skin: case report and review of the literature. *Br J Dermatol* 2001; 144(4): 885-889.
9. Sausa Ade A, Soares JM, de sa Santos MH, et al. Kikuchi-Fujimoto disease: three case reports. *Sao Paulo Med J.* 2010; 128(4):232-235.
10. Schnitzer B. Reactive lymphoid hyperplasia, in Jaffe ES (editor). *Surgical pathology of lymph node and related organs* 2nd edition. Philadelphia. W.B. Saunders co.1995; p124-128.
11. Louis N, Hanley M, Davidson NM. Kikuchi-Fujimoto disease: a report of two cases and an overview. *The Journal of Laryngology Otolaryngology* 1994; 108: 1001-1004. doi:10.1017/S0022215100128749.
12. Bosch X, Guilabert A. Kikuchi-Fujimoto disease. *Orphanet J Rare Dis.* 2006;1: 18. doi:10.1186/1750-1172-1-18.
13. Kuo TT. Kikuchi's disease (Histiocytic necrotizing lymphadenitis). A clinicopathologic study of 79 cases with an analysis of histologic subtypes, immunohistology and DNA ploidy. *Am J Surg Pathol* 1995; 19(7): 798-809.
14. Tsang WY, Chan JK. Fine needle aspiration cytologic diagnosis of Kikuchi's lymphadenitis. A report of 27 cases. *Am J Clin Pathol* 1994; 102(4): 454-458.
15. Tong TR, Chan OW, Lee KC. Diagnosing Kikuchi disease on fine needle aspiration biopsy: a retrospective study of 44 cases diagnosed by cytology and by histopathology. *Acta Cytol* 2001; 45: 953-957.
16. Dorfman RF, Berry GJ. Kikuchi's histiocytic necrotizing lymphadenitis: an analysis of 108 cases with emphasis on differential diagnosis. *Semin Diagn Pathol* 1988; 5(4): 329-345