

## Case Report

# Spontaneous Splenic Rupture in Severe Dengue

Ahmad Mursel Anam<sup>1</sup>, Mohammad Mufizul Islam Polash<sup>2</sup>, Md. Motiul Islam<sup>3</sup>, Muhammad Mahbubur Rahman Bhuiyan<sup>4</sup>, ARM Nooruzzaman<sup>5</sup>, Mirza Nazim Uddin<sup>6</sup>

### Abstract:

*Dengue is a mosquito-borne systemic viral infection with variety of clinical presentation, ranging from mild febrile illness to severe and fatal disease. A patient presented with history of fever and abdominal pain, and later developed shock. From clinical and epidemiological features, he was diagnosed as a patient of severe dengue, later confirmed by laboratory investigations. In dengue, shock can result from plasma leakage, and abdominal pain may be a feature of acalculous cholecystitis or pancreatitis, recognised presentations of dengue and usually managed conservatively. But high index of suspicion persuaded abdominal imaging, revealing a potentially fatal complication of dengue- spontaneous splenic rupture. Aggressive resuscitation and early surgery saved the patient.*

**Key Word:** Severe dengue, Spontaneous splenic rupture, Atypical feature of dengue

### Introduction:

We report a presentation of severe dengue, caused by an uncommon but life threatening complication, mimicking a common feature of plasma leakage. It could have easily been misdiagnosed, if were not for our high index of suspicion, and would result in an unwanted loss of life.

### Case report:

In middle of August, a 52-year-old hypertensive gentleman, a resident of Dhaka, Bangladesh, presented with high fever for 4 days, and abdominal pain for 6 hours. Fever was continued, and highest temperature recorded was 39°C. No rash was noticed, and there was no complaint of nausea, vomiting or constipation. On admission, he was found conscious, haemodynamically stable with blood pressure 130/90 mm Hg, and febrile (38.3°C). Tourniquet test was

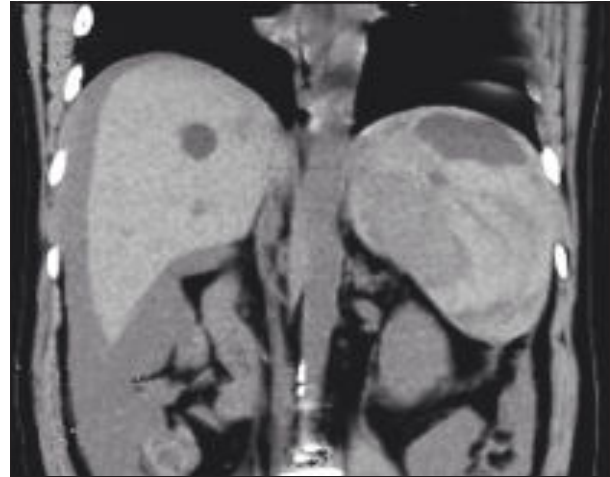
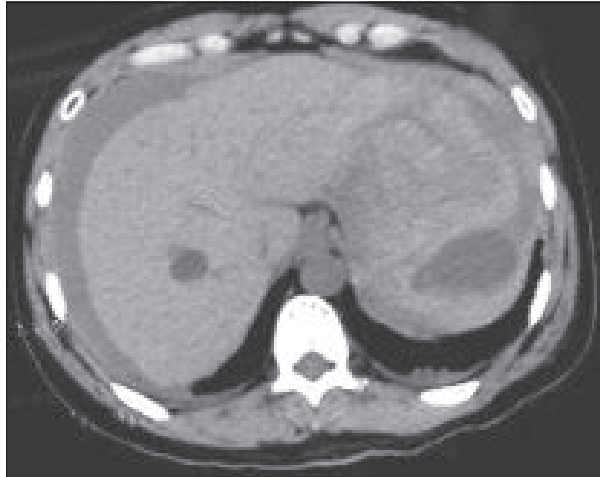
positive. Abdomen was soft, but with diffuse tenderness all over the nine quadrants. There was no palpable organomegaly, and bowel sound was audible. Other systems appeared normal. Presumptive diagnosis of 'dengue fever with warning sign' was made, and treatment was started accordingly.

After a few hours, he became pale and developed shock (pulse 140/min and blood pressure 80/50 mmHg). There was no response to intravenous fluid and packed red cell transfusion. He was shifted to the Intensive Care Unit (ICU) as his condition continued to deteriorate. At the ICU, he was found anaemic, drowsy, dyspnoeic (respiratory rate 26/min), and in profound shock (pulse 148/min and blood pressure 60/40 mmHg). He was electively intubated and put on mechanical ventilator support. Inotropes were administered to raise his blood pressure. On further physical examination, there was no visible bleeding from any site. Abdomen became distended, tender and board-like rigid. Diagnostic paracentesis yielded frank haemorrhagic fluid.

On admission, haemoglobin was 14.3 g/dl, haematocrit 41.3%, and platelet count 56,000/ $\mu$ L. Anti-Dengue Antibodies (both IgM & IgG) were positive. Following fluid resuscitation, haemoglobin was reduced to 9.5 g/dl and haematocrit to 28.5%. By another 6 hours, haemoglobin and haematocrit was further reduced to 7.12 g/dl & 21.2%, respectively. Platelet count remained <50,000/ $\mu$ L. Aminotransferases were slightly elevated (ALT 48 U/L & AST 64 U/L), but all other biochemical results were within normal range. Evidence of intra-abdominal haemorrhage from paracentesis persuaded to do an ultrasonogram (USG) of whole abdomen that suggested gross ascites of haemorrhagic nature with splenomegaly, and a possible intrasplenic haematoma. A plain CT scan of abdomen revealed splenic rupture with haematoma in the spleen and haemoperitoneum [Fig. 1 & 2].

1. Dr. Ahmad Mursel Anam, MBBS, Chief Resident, ICU, Square Hospitals Ltd., 18/F, BU Qazi Nuruzzaman Sarak (West Panthapath), Dhaka 1205, Bangladesh.
2. Dr. Mohammad Mufizul Islam Polash, MBBS, Clinical Staff, ICU, Square Hospitals Ltd., 18/F, BU Qazi Nuruzzaman Sarak (West Panthapath), Dhaka 1205, Bangladesh.
3. Dr. Md. Motiul Islam, MBBS, Clinical Staff, ICU, Square Hospitals Ltd., 18/F, BU Qazi Nuruzzaman Sarak (West Panthapath), Dhaka 1205, Bangladesh.
4. Dr. Muhammad Mahbubur Rahman Bhuiyan, MBBS, Clinical Staff, ICU, Square Hospitals Ltd., 18/F, BU Qazi Nuruzzaman Sarak (West Panthapath), Dhaka 1205, Bangladesh.
5. Dr. Abu Reza Mohammad Nooruzzaman, MRCP, Consultant, Internal Medicine & Critical Care, Square Hospitals Ltd., 18/F, BU Qazi Nuruzzaman Sarak (West Panthapath), Dhaka 1205, Bangladesh.
6. Dr. Mirza Nazim Uddin, MRCP, Consultant, Internal Medicine & Critical Care, Square Hospitals Ltd., 18/F, BU Qazi Nuruzzaman Sarak (West Panthapath), Dhaka 1205, Bangladesh.

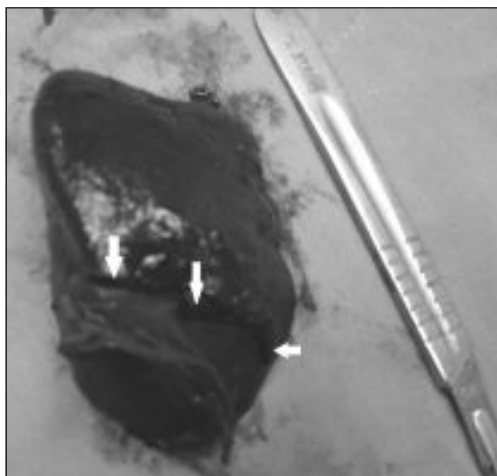
**Corresponding Author :** Dr. Ahmad Mursel Anam, MBBS, Chief Resident, ICU, Square Hospitals Ltd., 18/F, BU Qazi Nuruzzaman Sarak (West Panthapath), Dhaka 1205, Bangladesh., Mobile: +880-191-1010841, E-mail: murselanam@gmail.com



**Fig. 1 & 2:** Plain CT-scan of abdomen showing splenic rupture with haematoma in the spleen and haemoperitoneum.

The epidemiologic and presenting features all suggested towards the diagnosis of severe dengue. Hypotension and shock is a common feature of plasma leakage/shock syndrome of severe dengue. Abdominal pain might have been a feature of acalculous cholecystitis or acute pancreatitis, recognised atypical manifestations of dengue. But USG and CT scan of abdomen clearly identified the pathology, and the patient was finally diagnosed as a patient of 'spontaneous splenic rupture due to severe dengue'.

Initially, the patient was resuscitated with intravenous fluid and packed red cells, according to WHO guideline<sup>1</sup>. Inotropes were also required to normalize blood pressure. Fever was controlled by tepid sponging and paracetamol. After urgent surgical review, emergency laparotomy was arranged. Splenectomy and lavage of peritoneal cavity was done. There was a longitudinal rupture on the splenic surface [Fig. 3] on macroscopic examination, and later, it was found normal histopathologically. Vaccinations were carried out post-operatively.



**Fig. 3:** Longitudinal rupture on the splenic surface (Arrows).

His post-operative recovery was uneventful. He was discharged after 2 weeks of hospital admission, with complete physical well-being and stable haemodynamics. In follow-up visit after 2 weeks of discharge, he was found healthy.

#### **Discussion:**

Dengue is the most rapidly spreading mosquito-borne disease, with increasing geographic expansion to newer regions and, even from urban to rural settings.<sup>1</sup> It is a self-limiting, systemic viral infection, caused by one of four single-stranded RNA viruses (Dengue virus type 1 through 4), of genus flavivirus, spread by mosquito of genus *Aedes*.<sup>2</sup>

After an incubation period of 4-10 days, the illness begins abruptly and is followed by the three phases: febrile, critical and recovery. The acute febrile phase usually lasts 2-7 days and high fever is often accompanied by facial flushing, skin erythema, generalized body ache, myalgia, arthralgia and headache. A positive tourniquet test in this phase increases the probability of dengue. Around the time of defervescence, when the temperature drops to 37.5-38°C or less and remains below this level, usually on days 3-7 of illness, an increase in capillary permeability in parallel with increasing haematocrit levels may occur. If the patient survives the 24-48 hour critical phase, a gradual reabsorption of extravascular compartment fluid takes place in the following 48-72 hours.<sup>1</sup> Our patient presented on the 5<sup>th</sup> day of illness, at the critical phase.

Most infections are asymptomatic, but a wide variety of clinical manifestations, from mild febrile illness to severe and fatal disease may take place.<sup>2</sup> Patients either suffer from dengue (that recover without major complications) with or without warning signs, or severe dengue. Presumptive diagnosis of dengue is made on epidemiologic and clinical basis, i.e. patients live in or travel to dengue

endemic area, have fever and two of the followings, anorexia and nausea, rash, aches and pains, warning signs, leukopenia and positive Tourniquet test. The warning signs are abdominal pain or tenderness, persistent vomiting, clinical fluid accumulation, mucosal bleed, lethargy, restlessness, liver enlargement >2 cm, increase in haematocrit concurrent with rapid decrease in platelet count.<sup>1</sup> Young age, female gender, high body mass index, virus strain, and genetic variants have been identified as risk factors for severe dengue. Secondary dengue infection, in the form of two sequential infections by different serotypes, is also an epidemiologic risk factor for severe dengue.<sup>2</sup> Criteria for severe dengue includes severe plasma leakage leading to shock, serosal fluid accumulation with respiratory distress, severe bleeding, and AST or ALT e"1000, impaired consciousness, involvement of heart and, other organs.<sup>1</sup>

To confirm dengue by laboratory test is important when there is no signs of plasma leakage.<sup>1</sup> Dengue can be detected directly (by detecting virus or viral components in serum) or indirectly (by serology). During the febrile phase, detection of soluble non-structural protein 1 (NS1) by ELISA is confirmatory. Viral nucleic acid can also be detected in serum by RT-PCR assay, at this stage.<sup>1,2</sup> IgM antibodies are the first immunoglobulin isotype to appear, detectable by days 3-5 after onset of illness, peak about two weeks after the onset of symptoms and then decline to undetectable levels over 2-3 months. Anti-dengue serum IgG is usually detectable at low titres at the end of the first week of illness, increases slowly thereafter, and remains detectable after several months, even for life. During a secondary infection, IgG is detectable at high levels, even in the acute phase.<sup>1</sup>

As our patient was a resident of Dhaka, an established endemic dengue zone, and presented with fever, warning sign (abdominal pain) and positive Tourniquet test, there was no difficulty to reach his diagnosis. Furthermore, he developed signs of severe dengue, and anti-dengue antibodies also were positive.

Apart from the common clinical manifestations like fever, headache, retro-orbital pain, photophobia, arthralgia, and myalgia, atypical symptoms involving almost all systems of the body has also been reported in dengue.<sup>3</sup> Although quite a few cases of spontaneous splenic rupture in dengue has been reported,<sup>4-16</sup> it is a rare presentation.<sup>3</sup>

Splenic rupture takes place most commonly due to trauma. Non-traumatic splenic rupture has been reported in infection (malaria, infectious mononucleosis, typhoid, dengue), malignancy (non-Hodgkin lymphoma, metastasis), metabolic disorders, connective tissue diseases (rheumatoid arthritis, systemic lupus

erythematosus, polyarteritis nodosa, Wegener's granulomatosis) and haematological disorder (acute myeloid leukaemia, chronic lymphoid leukaemia). Spontaneous splenic rupture is termed when non-traumatic splenic rupture occurs in a histologically proven normal spleen, and is extremely rare.<sup>5,17</sup> The exact mechanism is yet to understand completely, but hypothesised as 1) increased intrasplenic tension caused by cellular hyperplasia and engorgement, 2) compression by abdominal muscles during sneezing, coughing or defecation, and 3) vascular occlusion causing thrombosis and infarction, interstitial and sub-capsular bleed, stripping of the capsule and finally capsular rupture.<sup>17</sup> In dengue, it is thought to be due to a combination of coagulation factors and severe thrombocytopenia, but again, the mechanism is not fully clear.<sup>5</sup>

Splenic rupture needs a high index of suspicion for diagnosis. It can occur in both uncomplicated and complicated/severe dengue. Abdominal pain is usually the presenting symptom, which can easily be mistaken for acalculous cholecystitis, a relatively common complication of dengue. Hypotension is frequently associated with complication of plasma leakage in dengue, and even an experienced clinician may overlook, rather than to associate with splenic rupture. This may lead even to unwanted loss of life. Imaging (USG and CT) of the abdomen can easily identify the complication, so it should always be considered in a patient of suspected dengue presenting with abdominal pain and hypotension. Early surgical intervention and appropriate supportive management is required for successful outcome of patient.<sup>5,17</sup>

#### Acknowledgement:

We thank Professor Sanawar Hossain and Dr. Ruhul Hassan Joarder, Consultants of surgery, SHL, for their active cooperation regarding the early surgical intervention and follow-up.

#### Reference:

1. Dengue: Guidelines for Diagnosis, Treatment, Prevention and Control, New edn. Geneva: World Health Organization, 2009.
2. Simmons CP, Farrar JJ, Chau NV, Wills B. Current Concepts: Dengue. *N Engl J Med* 2012;366:1423-1432.
3. Gulati S, Maheshwari A. Atypical Manifestations of Dengue. *Trop Med Int Health* 2007; 12:1087-1095.
4. Gopie P, Teelucksingh S, Naraynsingh V. Splenic Rupture Mimicking Dengue Shock Syndrome. *Trop Gastroenterol* 2012; 33: 154-155.
5. Bhaskar E, Moorthy S. Spontaneous Splenic Rupture in Dengue Fever with Non-fatal Outcome in an Adult. *J Infect Dev Ctries* 2012;6:369-372.
6. Imbert P, Sordet D, Hovette P, Touze JE. Spleen Rupture in a Patient with Dengue Fever. *Trop Med Parasitol* 1993; 44:327-328.

7. Pungjitprapai A, Tantawichien T. A Fatal Case of Spontaneous Rupture of the Spleen due to Dengue Virus Infection: Case Report and Review. *Southeast Asian J Trop Med Public Health* 2008;39:383-386.
8. Redondo MC, Ríos A, Cohen R, Ayala J, Martínez J, Arellano G et al. Hemorrhagic Dengue with Spontaneous Splenic Rupture: Case Report and Review. *Clin Infect Dis* 1997;25:1262-1263.
9. Seravali MR, Santos AH, Costa CE, Rangel DT, Valentim LF, Gonçalves RM. Spontaneous Splenic Rupture due to Dengue Fever: Report of Two Cases. *Braz J Infect Dis* 2008;12:538-540.
10. Sharma SK and Kadhiraivan T. Spontaneous Splenic Rupture in Dengue Hemorrhagic Fever. *Am J Trop Med Hyg* 2008;78:7.
11. Couvelard A, Marianneau P, Bedel C, Drouet MT, Vachon F, Hénin D et al. Report of a Fatal Case of Dengue Infection with Hepatitis: Demonstration of Dengue Antigens in Hepatocytes and Liver Apoptosis. *Hum Pathol* 1999;30:1106-1110.
12. Rapp C, Debord T, Imbert P, Lambotte O, Roué R. Splenic Rupture in Infectious Disease: Splenectomy or Conservative Treatment? Report of Three Cases. *Rev Med Interne* 2002;23:85-91.
13. Miranda LE, Miranda SJ, Rolland M. Case Report: Spontaneous Rupture of the Spleen due to Dengue Fever. *Braz J Infect Dis* 2003;7:423-425.
14. Naik RP, Joshipura VP, Patel NR, Thakkar RM. Spontaneous Rupture of Spleen in Dengue Virus Infection. *Trop Gastroenterol* 2010;31:237-239.
15. de Moura Mendonça LS, de Moura Mendonça ML, Parrode N, Barbosa M, Cardoso RM, de Araújo-Filho JA. Splenic Rupture in Dengue Hemorrhagic Fever: Report of a Case and Review. *Jpn J Infect Dis* 2011;64:330-332.
16. Liyanage ASD, Kumara MTGJ, Rupasinghe DK, Sutharshan S, Gamage BD, Kulathunga A et al. An Unusual Cause for Shock in Dengue Fever. *Ceylon Med J* 2011;56:120-121.
17. Gedic E, Girgin S, Aldemir M, Keles C, Tuncer MC, Aktas A. Non-traumatic Splenic Rupture: Report of Seven Cases and Review of the Literature. *World J Gastroenterol* 2008;14:6711-6716.