

## Case Report

# Post-Angiography Contrast-Induced Encephalopathy

Adnan Shareef<sup>1</sup>, Ahmad Mursel Anam<sup>2</sup>, Meher Nigar Alam<sup>3</sup>, Raihan Rabbani<sup>4</sup>

### Abstract

*The use of radio-contrast agents are increasing day by day in modern imaging modalities. But they are not completely risk free. Among others, contrast-induced encephalopathy is a rare adverse effect. We report a patient with end-stage renal disease developing contrast induced encephalopathy following coronary angiogram (CAG).*

### Case Report:

A 70-year-old male got admitted in September, 2013 in the Dept. of Cardiology of SHL with the features of heart failure for 3 weeks. He was a hypertensive, non-diabetic and a known case of end stage renal disease receiving regular hemodialysis. The primary aim of admission was to perform an investigative Coronary Angiogram (CAG).

On admission the patient was conscious with GCS 15/15 and all the vitals were stable. All laboratory parameters were within range except the calculated GFR (9.0 ml/min). After admission with all necessary precautions the investigative angiogram was performed, utilizing 75ml of Iopamidol contrast solution (370mg/ml) which revealed Double Vessel Coronary Artery Disease.

About three hours later, the patient developed agitation and restlessness with severe bitemporal headache, but there was no associated confusion. Oral paracetamol was administered. An hour later, the patient became visibly confused, drowsy, emetic and clinically obtunded. The patient was unable to follow verbal commands; however vital signs were still unremarkable. The patient had a Glasgow Coma Scale (GCS) of 10, and on thorough neurological examination had no focal signs. Immediate labs revealed serum levels of corrected calcium – 9.6mg/dl (8.5-10.5); Sodium- 139mmol/L (135-145), potassium-4.3mmol/L (3.5-5.0); Cl -90mmol/L (95-105); TCO<sub>2</sub> -26mmol/L (24-30); Creatinine- 6.0 mg/dl (0.8-1.4); Urea- 113 mg/dl (10-50).

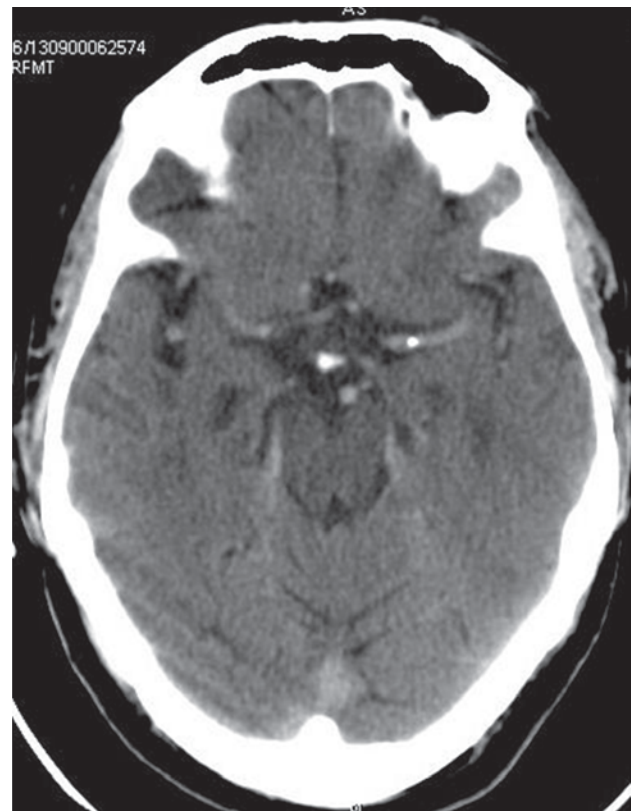
1. Dr. Adnan Shareef, MBBS, Resident Medical Officer, ICU, Square Hospitals Ltd.
2. Dr. Ahmad Mursel Anam, MBBS, Chief Resident, ICU, Square Hospitals Ltd.
3. Dr. Meher Nigar Alam, MBBS, Resident Medical Officer, Nephrology, Square Hospitals Ltd.
4. Dr. Raihan Rabbani, FCPS, MD(USA), Consultant, ICU, Square Hospitals Ltd.

All the Authors work in SQUARE Hospital Limited.

### Corresponding Author:

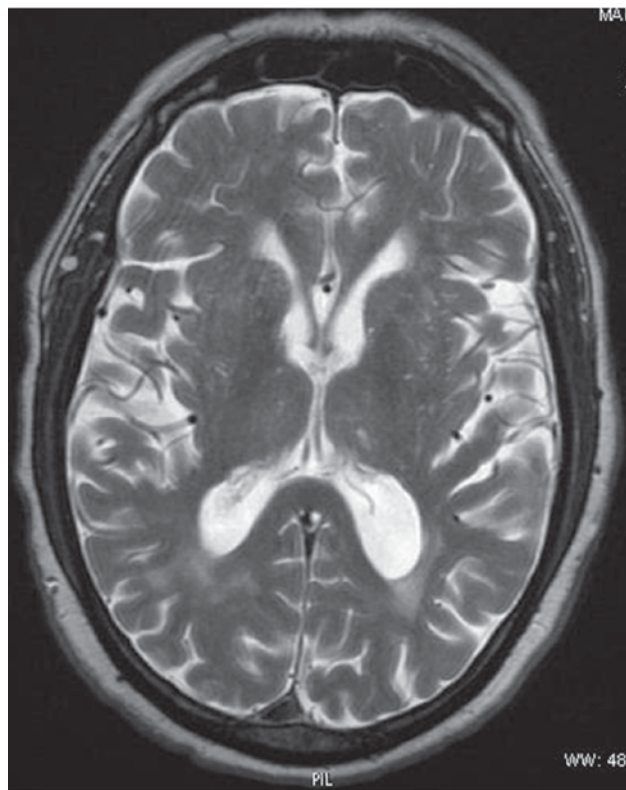
Dr. Adnan Shareef, MBBS  
Resident Medical Officer, ICU  
Square Hospitals Ltd,  
18F B U Kazi Nuruzzaman Sarak  
Dhaka, Bangladesh.  
Email: adnanshareef18@yahoo.com

The patient's GCS further reduced to 8/15 and he developed neurological findings, including brisk lower limb reflexes and positive Babinski sign bilaterally. A CT-scan of the brain without contrast was performed immediately. In addition to the findings of cerebral atrophy with chronic micro-vascular ischemia and primary empty sella, prominent vascular markings, especially in the fronto-temporal region suggested presence of radio-contrast media [Fig. 1].



**Fig 1:** CT-Scan of Brain showing prominent vascular markings, especially in the fronto-temporal region suggested presence of radio-contrast media

The patient was immediately shifted to ICU and an emergency hemodialysis was arranged. Over the next few hours, neurological symptoms and signs were resolved. The patient was shifted back to his cabin in a full conscious condition. A Magnetic Resonance Imaging (MRI) of the brain was performed but revealed no obvious abnormalities [Fig. 2], thereby excluding a structural cause for acute encephalopathy.



**Fig 2:** MRI of the brain (T2 film) showing no structural abnormality.

A preliminary diagnosis of contrast-induced encephalopathy with complete neurological recovery was made. The patient was discharged, and informed that any future procedure involving contrast should be avoided.

#### **Discussion:**

The term 'Encephalopathy' describes a general alteration in brain function manifesting as an attention disorder anywhere within the continuum between a hyper alert agitated state and coma. In clinical practice, the diagnosis of encephalopathy is usually reserved for the diffuse brain dysfunction felt to be due to a systemic, metabolic or toxic derangement or a multifocal structural process. Diagnosis is usually made by finding encephalopathic symptoms and (mostly) nonlocalizing findings within the appropriate clinical context, usually with exclusion of other processes through imaging other studies.<sup>1</sup>

The administration of contrast agents is usually associated with few side effects such as anaphylactoid reaction, heart failure, arrhythmia, renal failure and very rarely encephalopathy. The mechanism of this encephalopathy is not well understood. Probably the contrast agent disturbed the blood-brain barrier and entered into the brain of our patient which may be the primary mechanism leading to encephalopathy.<sup>2</sup>

It has been postulated that a combination of chemotoxic effects related to contrast hyperosmolarity and direct neurotoxicity of the contrast agent itself are responsible for the clinical syndrome. The following aspects may cause this

phenomenon. Firstly, contrast such as hypertonic solutions could draw water out of the endothelial cells of brain capillaries, arteriols and venules, causing the endothelial cell to shrink and to separate at tight junctions. Secondly, the increase in intraluminal pressure caused by pressure injection of the contrast agent as well as by contrast agent-induced cerebral vasodilatation might contribute to increasing vascular wall tension, further separating tight junctions. Thirdly, vesicular transport may be a mechanism of osmotic barrier opening. All these mechanisms could lead to the leakage of contrast agent into the CSF causing encephalopathy and repeated injections of contrast agents within several minutes may result in neurotoxic effects.<sup>2</sup>

These effects are seen at higher concentrations and are more frequently associated ionic and high-osmolar agents, however, non-ionic, low-osmolar contrast media can still be associated with adverse reactions involving the neural circuitry, as was seen in this case.<sup>3</sup>

Iopamidol is a contrast medium of the new generation of non ionic compounds which are water-soluble because the molecular structure incorporates hydrophilic groups. These contrast agents are usually well tolerated as their aqueous solutions show an inherently high osmolality and this is responsible for a number of side effects too. There are no definite or absolute contraindications to the use of Iopamidol with possible exception of Waldenström's macroglobulinemia, multiple myeloma and severe liver and kidney diseases.<sup>4</sup>

#### **Conclusion**

Contrast-induced encephalopathy should be considered in a new-onset neurological disorder following an angiographic procedure. The phenomenon might be rare but it carries more risk in end stage renal disease patient. Despite the infrequency of this complication, medical staff should be vigilant in the post-angiographic procedure period for signs and symptoms of neurological dysfunction. This would translate to better outcomes for the patient in the short- and long-terms, and possibly deter further cautions in using contrast to a patient at-risk of developing or already displaying features this condition.

#### **References**

1. Lewis SL. Encephalopathy. In: Roos KL, ed. *Emergency Neurology*, Springer; 2012:283-284.
2. Jiang X, Li J, Chen X. Contrast-Induced Encephalopathy Following Coronary Angioplasty with Iopromide. *Neurosciences (Riyadh)* 2012;17(4):378-9.
3. F Ting, A Bhat, R Markus, M Ortega, S Ting. Contrast-Induced Encephalopathy Post-Angiography. *The Internet Journal of Neurology*. 2013 Volume 16 Number 1.
4. Literary leaflet of BRACCO for Iopamidol preparation (Iopamiro). <[http://www.old.health.gov.il/units/pharmacy/trufot/alonim/IOPA\\_MIRO\\_dr\\_1327916922980.pdf](http://www.old.health.gov.il/units/pharmacy/trufot/alonim/IOPA_MIRO_dr_1327916922980.pdf)>