

Case Report

Calvarial tuberculosis - a case report

SahaDK¹, Ahsan ASMA², Fatema K³, Faruq MO⁴, Saha M⁵ AhmedF⁶

Abstract :

Tuberculosis is an infectious disease caused by acid fast bacilli, Mycobacterium tuberculosis that usually affects the lung although it may affect any organ. Tuberculous osteitis of the cranial bone is known as calvarial tuberculosis.

The disease is considered secondary to an active or latent tuberculous lesion elsewhere in the body, but direct spread from orbit, paranasal sinuses and face has also been implicated. Though tuberculosis is endemic in Bangladesh, calvarial tuberculosis is very very rare.

We report a case of a female, diabetic, hypertensive, chronic kidney disease(CKD), bronchial asthma patient presented with osteolytic lesion in skull with adjacent subcutaneous swelling. She was eventually diagnosed as calvarial tuberculosis on the basis of positive MTB- PCR from the pus aspirated from the swelling.

Key words: Calvarial tuberculosis, Intensive care unit.

Introduction :

Tuberculosis of skull is a rare manifestation of extrapulmonary disease.^{1,2} Skeletal TB accounts for 1-3% of all cases of tuberculosis³ and calvarial involvement is seen only in 0.2-1.3% of patients with skeletal tuberculosis.¹ Tubercular osteomyelitis is rare even in areas where tuberculosis is endemic.⁴ Here we report the case of an elderly immunocompromised lady who presented with osteolytic lesion in skull with adjacent subcutaneous swelling, eventually diagnosed as calvarial tuberculosis.

Case report :

A 70-year old female, diabetic, hypertensive, known CKD, Bronchial asthma admitted in BIRDEM under Neurology department with complaints of redness and watering of left eye associated with bilateral poorly localized headache for 3

months. Patient also developed swelling and loss of vision of left eye with low grade fever without chill, rigor and cough for 1 month. She had anorexia, nausea. Previously she consulted with several physicians and diagnosed as a suspected case of cerebral abscess and panophthalmitis on the basis of MRI brain which suggested left periorbital and temporo-parietal soft tissue inflammation (abscess) with left retro-orbital extension causing proptosis of left eyeball (Fig 1); left fronto-temporal cerebritis; got treatment without any improvement.

Following BIRDEM admission, she was diagnosed as acute kidney injury (AKI) on CKD, and advised for dialysis. But party refused. During hospital stay, she gradually developed altered level of consciousness and shortness of breath, and later shifted to Intensive Care Unit (ICU). On ICU admission, she was unconscious (Grade-III), anemic, edematous, tachypneic, having poor oral hygiene. There was a swelling of left side of scalp (10 X 8cm) which was soft with positive fluctuation and normal skin overlying. Underlying bones could not be felt. Left eye had proptosis with congested conjunctiva and chemosis; Fundus had retinal haemorrhage. Pupil –mid dilated and not reacting. Reflexes were normal with bilateral planter extensor. No signs of meningeal irritation found. Breath sound was vesicular with prolonged expiration, widespread ronchi throughout. Her ABG showed type 2 respiratory failure, she was intubated and supported by mechanical ventilator. Urgent CT brain showed extra cranial soft tissue swelling with underlying bony defect in left frontal bone.

1. Dr. Debasish Kumar Saha, FCPS (Medicine), Registrar, Dept of Critical Care Medicine, BIRDEM.
2. Dr. A.S.M. Areef Ahsan, FCPS (Medicine), MD (Chest), MD (Critical Care Medicine), Associate Professor and Head, Dept of Critical Care Medicine, BIRDEM.
3. Dr. Kaniz Fatema, FCPS (Medicine), MD (Critical Care Medicine), Assistant Professor, Dept of Critical Care Medicine, BIRDEM.
4. Prof. Mohammad Omar Faruq, MD, FACP, FACEP, FCCM, FCPS (Medicine), Professor, Dept of Critical Care Medicine, ICU, Ibn Sina Hospital, Dhaka.
5. Dr. Madhurima Saha, FCPS (Medicine), Registrar, Dept of Critical Care Medicine, BIRDEM
6. Dr. Fatema Ahmed, FCPS (Medicine), MD (Critical Care Medicine), Assistant Professor, Dept of Critical Care Medicine, BIRDEM

Corresponding Author :

Dr. Debasish Kumar Saha
FCPS (Medicine)
Registrar, Dept of Critical Care Medicine, BIRDEM.
Email:debasish81dmc@yahoo.com

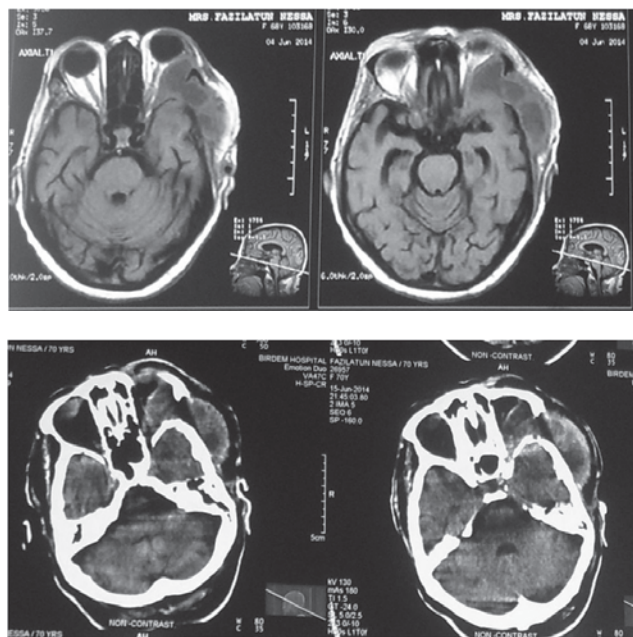


Fig 1: MRI brain suggesting left periorbital and temporo-parietal soft tissue inflammation (abscess) with left retro-orbital extension causing proptosis of left eyeball.

Laboratory investigations showed Hb 8.6mg/dl, ESR 100 mm/1st hour, Urea 173mg/dl, S. Creatinine 9mg/dl, X-ray chest unremarkable; Blood, Urine and Tracheal Aspirate C/S revealed no growth, T/A for AFB not found. CSF study including ADA normal. With the consent of the party, we did FNA from scalp swelling, which showed pus (Fig 2) and histopathology revealed few aggregates and scattered epithelioid cells along with many polymorphs, lymphocytes as well as histiocytes; compatible with abscess (Fig 3); possibility of TB cannot be ruled out.



Fig 2 : Fine needle aspiration material from the swelling

Pus for C/S yield no growth, PCR for MTB complex in pus was positive. She was then finally diagnosed as Calvarial Tuberculosis, with extension into left orbit. She was started

anti-tubercular drugs (four drugs regimen with dose adjustment according to CCR) and her conscious level was improving slowly. But unfortunately, party could not bear the expense and she was discharged against medical advice, and ultimately expired.

Discussion :

Skeletal TB accounts for 1-3% of all cases of TB³ and calvarial involvement is seen only in 0.2-1.3% of patients with skeletal TB.¹ Since the first description of TB of the skull by Reid in 1842,⁵ the condition has been reported infrequently, even in areas where TB is endemic.⁴ The possible reasons for this includes: (1) chronic indolent asymptomatic lesion, (2) decreased awareness of the entity, and (3) earlier diagnosis and management of the primary disease.⁶

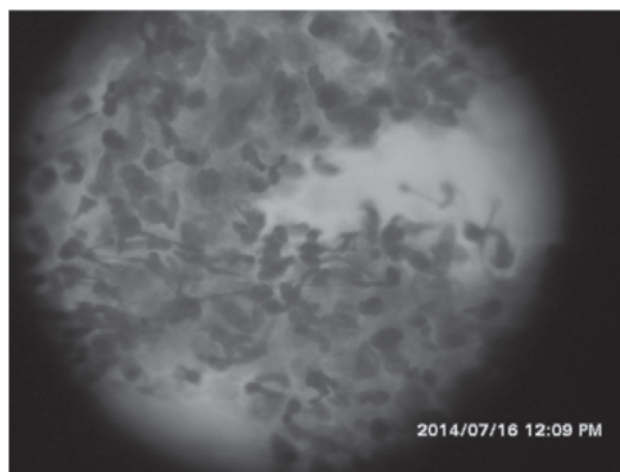


Fig 3 : Histopathological slide of FNA material

Tuberculous osteitis of the skull is essentially a disease of the young, with 75-90% of the reported cases being in patients under age of 20 years and 50% in those under the age of 10 years.^{4,5} The disease is rare in infants as the infants' skull is poor in cancellous bone.² It affects both sexes equally.^{4,7}

Most cases of calvarial TB occur secondary to pulmonary TB,^{5,8} though direct spread from the orbit, paranasal sinuses and face has also been implicated.⁸ Spread of the disease via the lymphatic route may be more likely, as this would explain the rarity of TB in the skull which is poor in lymphatics though rich in vascularity. Skull lesions are seen more commonly in the fronto-parietal region than in occipito-temporal region, the ratio being five to one.¹¹ In our patient, bony lesion was in left frontal bone.

The infection causes capillary obliteration and replacement of bony trabeculae by granulation tissue. Spread may be contained by concentrically placed proliferating fibroblast; otherwise extension may take place through either table.¹² The outer table is usually destroyed first and though eventually both tables can be affected.

Suture do not constitute a barrier to the spread of disease, but the dura is extremely resistant.¹²

Patient typically present with a painless, soft, fluctuant swelling with a firmly attached base. Attachment to skin, sinus formation and discolouration are late features. Our patient presented with a painless, soft, fluctuant swelling over fronto-parietal areas with intact skin overlying and no colour changes. Headache, if present, is usually localized to the site of infection. Our patient had headache but not localized. She also had redness and watering of left eye which was due to extension of the disease into orbit. Systemic manifestations are uncommon, but the ESR is elevated, MT is usually positive. Our patient had some systemic features such as fever, anorexia, nausea. Her ESR was 100 mm in 1st hour. Radiographs of skull can be helpful, although features are variable and non-specific. Both osteolytic and osteoblastic areas may be seen.^{4,7} CT features only recently described^(4,12,13,14) are not necessarily diagnostic. An irregular bony defect, wider at the inner table, forming a cone shape,¹² as seen in our patient; a diffuse hypodense lesion with enhancing margins and central hypodensity, and a well circumscribed enhancing hyperdense lesion have all been described.⁴

A definitive diagnosis can only be made by identification of the acid-fast bacilli in smears or biopsy specimens. FNAC is a logical investigation in lesions with intact overlying skin and may obviate the need for surgery.⁹ We did FNAC from the swelling which showed pus and the histopathology was suggestive of tuberculosis, and the PCR for MTB complex was positive, on that basis confirmed diagnosis was established.

The management includes surgery and anti-tubercular drugs. Good results were achieved with surgery alone in the era before chemotherapy.^{5,12} However with the advent of anti-tubercular therapy, surgery is indicated for the diagnostic purposes, for removal of epidural collection and/or large sequestra, and for patient with discharging sinus,^{12,14} intracranial extension,¹⁴ or large collection of caseating material causing mass effect or an increase in intracranial pressure.⁴ Our patient got adjusted four drugs regime of antitubercular drugs. She had other comorbidities such as ESRD, for which party did not agreed for renal replacement therapy despite repeated counseling. Due to financial constraints, she was discharged against medical advice and ultimately she expired.

Conclusion :

Calvarial tuberculosis is an uncommon disease, even in countries with endemic tuberculosis. Incidence of the disease is on the rise, especially with the prevalence of immunodeficiency syndrome. There are no pathognomonic clinico-radiological features of the disease. The difficulty in diagnosis may be compounded by secondary bacterial infection. Efforts should be made to isolate mycobacteria by use of FNAC. Antitubercular therapy should be started as soon as possible to ensure better outcome.

References :

1. Straus DC. Tuberculosis of flat bones of the vault of the skull. *Surg Gynaecol Obstet* 1933; 57: 384-98.
2. Barton CJ. Tuberculosis of the vault of the skull. *Brit J Radiol* 1961; 34: 286.
3. Tuli S. Epidemiology and Prevalence: tuberculosis of the skeletal system: Jaypee Brothers, New Delhi, 1993;1.
4. Gupta PK, Kolluri VR, Chandramouli BA, Venkataramana NK, Das BS. Calvarial tuberculosis: a report of two cases. *Neurosurgery* 1989;25:830-3.
5. Miles J, Hughes B. Tuberculous osteitis of the skull. *Br J Surg* 1970;57:673-9.
6. Fisher S, Nitzan M, Garty BZ. Tuberculous osteomyelitis of the skull in an Ethiopian immigrant child [see comments]. *Isr J Med Sci* 1992;28:893-4.
7. Unuvar E, Oguz F, Sadikoglu B, Sidal M, Ones U, Tetikkurt S. Calvarial tuberculosis. *J Paediatr Child Health* 1999;35:221-2.
8. Malhotra R, Dinda AK, Bhan S. Tuberculous osteitis of skull. *Indian Pediatr* 1993;30:1119-23.
9. Dharwal M, Gupta DK, Punia VP, Sinha RS. Tuberculous osteomyelitis of skull in a sixty year old female. *J Assoc Physicians India* 1995;43:575-7.
10. Tirona JP. The roentgenological and pathological aspects of tuberculosis of the skull. *AJR Am J Roentgenol* 1954;72:762-8.
11. Tata HR. Tubercular osteomyelitis of the skull. *Indian J Tuberc* 1978;25:208-9
12. LeRoux P, Griffin GE, Marsh HT, Winn R. Tuberculosis of the skull—A rare condition: case report and review of the literature. *Neurosurgery* 1990;26:851-6.
13. Jadhav RN, Palande DA. Calvarial tuberculosis. *Neurosurgery* 1999;45:1345-50.
14. Tyagi AK, Kirolos RW, Kang NV. Tuberculous osteitis of the skull: a case report and review of the literature. *Br J Neurosurg* 1996;10:399-401.
15. Schuster J, Rakasun T, Chonmaitree T. Tuberculous osteitis skull mimicking histiocytosis. *J Pediatr* 1984; 105: 269-71