

Original Article

A Comparative Study between Swenson Abdominoperineal Pull-through and Transanal, Full Thickness, Swenson like Approach for Hirschsprung Disease

Khalid Mahmud¹, MK Islam², M Rashedul Alam³, Sabbir Karim⁴

Abstract

Background: Hirschsprung disease (HD) is a congenital developmental disorder of intrinsic component of enteric nervous system leading to severe complication which needs operative correction. There are different operative techniques existing and each technique has its advantages and disadvantages.

Objective: The aim of the study was to evaluate the better outcome between Transanal full thickness swenson like pull through and Swenson abdomino-perineal pull through.

Method: The Prospective comparative study had been carried out in the department of paediatric surgery, Dhaka Shishu (Children) Hospital during the period of January 2014 to July 2016. Total 56 patients with HD patients were included in the study irrespective of colostomy except major co-morbidities which can influence the general outcomes and who did not agree to close stoma within 12 weeks of pull-through operation. Patients were allocated in both groups by purposive sampling. Twenty eight patients with long segment HD were allocated in Group-A and operated by Swenson abdominoperineal pull through and 28 patients with short segment disease were allocated in group-B and operated by Transanal, full thickness, swenson like procedure.

Result: Among the study population 32 (57.14%) were male and 24 (42.86%) were female with age range was 1 day-96 months. Four patients developed urinary incontinence, 3 patients developed cuff abscess and 2 patients developed fecal incontinence. And in group-B no patient developed urinary incontinence but 4 developed cuff and anastomotic abscess and no patient developed fecal incontinence. The mean operation time 114.14 ± 13.02 in group-A and 68.36 ± 16.12 minutes in group-B. Mean hospital stay in group-A was 6.18 ± 1.83 days and 5.05 ± 0.43 days in group-B.

Conclusion: The newer modification, Transanal, full thickness Swenson like procedure can be better technique in the management of HD.

Key words: Hirschsprung, Trans anal Full Thickness, Swenson.

Introduction:

Hirschsprung's disease is a developmental disorder of the intrinsic component of the enteric nervous system that is characterized by the absence of ganglion cells in the myenteric and submucosal plexuses of the distal intestine.^{1,2} Because these cells are responsible for normal

speristalsis, patients with Hirschsprung's disease present with functional intestinal obstruction at the level of aganglionosis.

The absence of ganglion cells or aganglionosis starts at the distal bowel beginning at the internal anal sphincter and extending proximally for various length, in 5% to 10% of cases can involve the entire colon or even a significant amount of the small intestine.² The incidence of Hirschsprung's disease is approximately 1 in 5000 live-born infants.¹

The initial attempt to cure the disease was a diverting colostomy by various authors. The procedure relieved the symptoms but recurred after closure of colostomy. This, now we can explain by persistence of disease in the distal colon. Swenson's goal was removal of the entire aganglionic colon, with an end-to-end anastomosis above the anal sphincter.¹ Swenson pull through was the historic breakthrough in the understanding of pathogenesis and treatment of HD. The procedure, soon became popular as Swenson's procedure, brought a realistic hope that children with HD can be cured.³

Swenson is the least often chosen technique as surgeons all over the world was complaining about fecal, urinary and sexual dysfunction in children under went Swenson pull through.⁴ Yet, it is hard to surpass or even match the results that had been obtained by Swenson over many dedicated

1. Dr. Khalid Mahmud, MS (Paediatric Surgery), Resident Medical Officer, Division of Paediatric Surgery, Dhaka Shishu (Children) Hospital, Dhaka
2. Prof. MK Islam, MS (Paediatric Surgery), Professor & Head, Department of Neonatal Surgery, Dhaka Shishu (Children) Hospital, Dhaka
3. Dr. M Rashedul Alam, MBBS, Registrar, Department of Paediatric Surgery, Dhaka Shishu (Children) Hospital, Dhaka
4. Dr. Sabbir Karim, (Paediatric Surgery), Registrar-in-charge, Department of Paediatric Surgery, Dhaka Shishu (Children) Hospital, Dhaka

Corresponding Author:

Dr. S.M. Khalid Mahmud
Resident Medical Officer
Dhaka Shishu (Children) Hospital
Sher-e- Banglanagar, Dhaka.
E-mail: drshakildsh@gmail.com

years. He was certainly a blessing to patients with congenital aganglionosis coli.⁵

As there are some complications like fecal incontinence, urinary incontinence, calf abscess and sexual dysfunction with Swenson pull through; some other procedures were described by several authors.⁶⁻¹⁵ So search for newer ideas never ends. In this continuity Levitt MA et al.⁴introduced a newer idea. They thought that if they carried out the pelvic dissection very close to the wall of the rectum as they do in PSARP then morbidity might be minimized. Upon their thought they started Swenson like transanal pull through for Hirschprung's patients.⁴ They carried out the operation through transanal route if the patient had Short segment HD, and abdominal and perineal route for patients with long segment disease.

We also believe that if the pelvic dissection can be carried out through transanal route rather than abdominal route in case of classic Swenson pull through then morbidity can be minimized, provided that transanal pelvic dissection done very close to the rectal wall. On this background we wanted to compare the outcome of abdominoperineal Swenson pull through with the most recent procedure transanal full thickness Swenson like pull through.

Methods:

The prospective comparative study was conducted in the department of paediatric surgery, Dhaka Shishu (Children) Hospital during the period of January 2014 to July2016. Ethical permission was taken from ethical committee of Bangladesh Institute of Child Health (BICH). Patients with Hirschprung's disease diagnosed by history, radiology and histopathology irrespective of colostomy and level of aganglionosis attending surgery outpatients department were the study subjects. First 56 patients admitted through SOPD with Hirschprung's disease were included in the study after fulfillment of inclusion criteria and allocated in group-A and Group-B by purposive sampling. 28 patients in group-A had their transition zone above rectosigmoid region (long segment) and operated by Swenson procedure and Group – B patients had their transition zone at rectosigmoid region and operated by transanal, fullthickness, Swenson like approach. Necessary informations and written informed consents were taken from the guardians for this study. After getting written consent from parents in a preformed questionnaire, clinical examination, evaluating preoperative management, operative findings, post operative management and follow up at 2nd, 4th, 8th and 12th weeks following operations and collected data were arranged in systematic manner and data was analyzed by SPSS 19.0 software system and significant tests were performed by chi-square for qualitative data and un-paired t test for quantitative data.

Operative Technique:

All the patients were operated under general anaesthesia. All 28 patients of Group A underwent classic Swenson or abdominoperineal pull through where as all 28 patients of Group B underwent transanal Swenson like pull through.

Mechanical bowel preparations along with rectal irrigations are recommended. Prior to operation a total body preparation from the nipples to the toes and urinary catheterization is performed.

Swenson procedure:

The operation was originally done through a laparotomy, with the anastomosis being performed from a perineal approach after eversion of the aganglionic rectum. Coloanastomosis was done 1cm proximal to dentate line. Dissection continued up to the tip of the coccyx. Then the dissected aganglionic gut was pulled through the anus in everted fashion. Last of all the healthy ganglionic gut was pulled through the aganglionic gut keeping a seromuscular cuff measuring 1 cm anteriorly and 0.5 cm posteriorly (fig-1)

Transanal, full-thickness, Swenson-like procedure:

The procedure was done through transanally. After preserving the dentate line within the hook of lone star retractor, full thickness dissection was carried out proximal to traction sutures placed 1 cm proximal to dentate line. Then dissection carried out on rectal wall to avoid injury to neuro vascular structures. Finally aganglionic segment was removed and anastomosis was done by 2 layers 4-0 polyglactin 910 suture material.⁴ (fig 2).

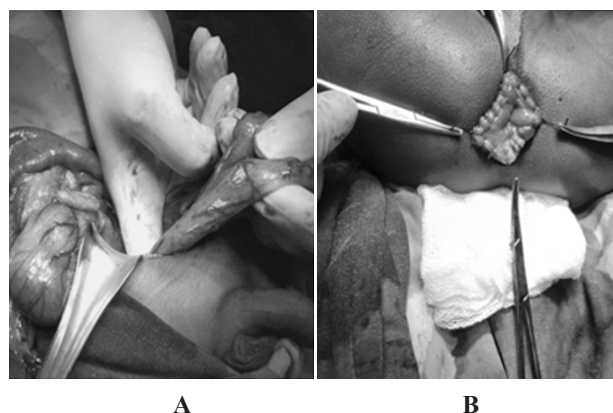


Figure 1: Steps of classic abdominoperineal Swenson Pull through. A: Identification of normal colon with mobilization. B: Colo-anal anastomosis.

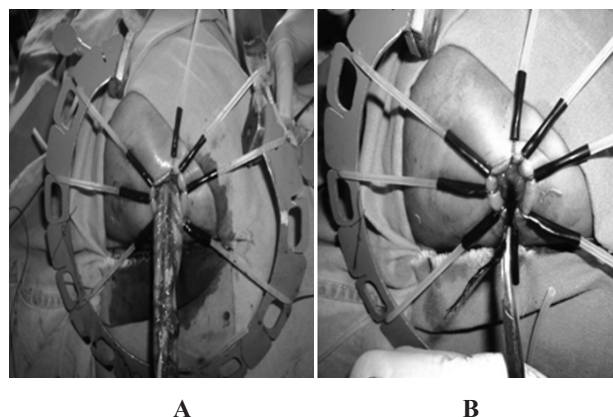


Figure 2: Steps of transanal full thickness Swenson like pull through. A: Replace hook 1cm proximal to Dentate line. B: Pull through of aganglionic narrow colon.

Results:

After employing exclusion criteria 56 patients were evaluated, with age at the time of operation ranging from 1 day to 96 months. Mean age of group-A were 21.16±11.57 months and in group-B were 14.71± 19.68 months. Among all study population there were 32 males (57.14%) and 24 (42.86%) females, with male:female ratio of 1.3:1.

Table -1: Age and Sex distribution among study groups

Features	Group-A (Classic Swenson)	Group-B (Transanal, Swenson like)
Patients(n)	28	28
Age (month)		
Mean ± SD	21.16 ± 11.57	14.71 ± 19.68
Range	6.5 – 49	1 - 96
Sex		
Male	20 (37.71%)	12 (21.43%)
Female	08 (14.29%)	16 (28.57%)

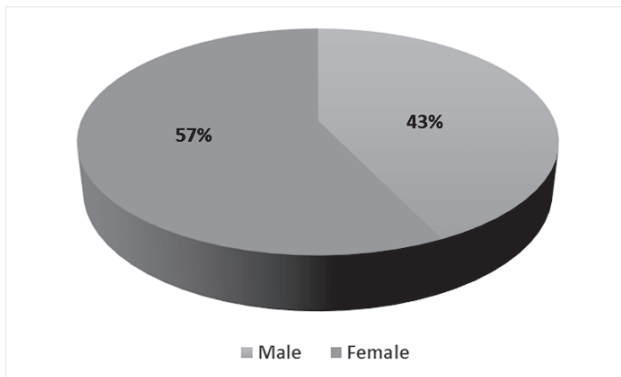


Fig.3: Sex distribution among study groups

Associated anomalies in the series included 3 patients with minor cardiac anomaly, 1 patient with cleft lip. Pre operative evaluation with contrast enema revealed a transition zone between rectosigmoid to mid transverse colon. We performed transanal resection on 28 patients who had well defined rectosigmoid transition zone on contrast enema and 28 patients underwent classic Swenson procedure who had their transition zone above the fixed part of sigmoid colon in contrast enemas. The average length of resected specimen was 22.7 ± 11.9 cm. in group-B and 23.17 ± 17.67 cm in group-A.

Postoperative complications were evaluated. No patients needed perioperative blood transfusion. Four patients in group-B and 3 patients in group-A developed anastomotic abscess (p value is >0.05). Two patients in group-A and 1

patient in group-B developed fecal incontinence (p value>0.05). Four patients in group-A developed urinary incontinence and on the other hand no patient in group-B developed urinary incontinence which was statistically significant (p value 0.035).

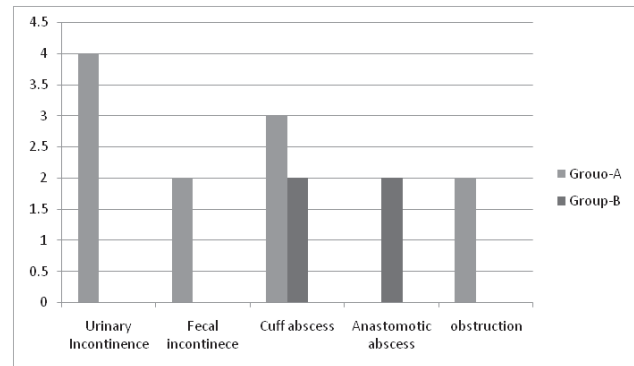


Fig. 4: Post operative complications

Table II: Postoperative complications

Variables	Group-A	Group-B	P Value
Urinary Incontinence	4	0	0.038
Anastomotic/cuff abscess	3	4	0.16
Wound Infection	3	0	0.15
Fecal Incontinence	2	1	0.35

The mean operation time from incision to dressing was 68.46 ± 29.03 minutes in group-B and 114.14 ± 13.02 in group-A which was statistically significant(p value<0.05). Mean hospital stay from operation to discharge was 6.18±1.83 days in group-A and in group-B it was 5.01 ± 0.43 days (p value<0.05).

Table III:

Variables	Group-A	Group-B	p Value
Operation Time(min)			
Range	90-1351	55-110	
Mean±SD	114.14±13.02	68.46±29.03	<0.05
Hospital Stay			
Range	5-9	7-11	<0.05
Mean±SD	6.18±1.86	5.05±0.43	

Discussion:

Hirschsprung’s disease is a developmental disorder of the intrinsic component of the enteric nervous system that is characterized by the absence of ganglion cells in the myenteric and submucosal plexuses of the distal intestine.

Because these cells are responsible for normal peristalsis, patients with Hirschsprung's disease present with functional intestinal obstruction at the level of aganglionosis.^{1,2} This functional obstruction eventually lead to failure to thrive, HAEC and death. This is the reason we should concern about HD. This prospective comparative study titled comparative study between transanal, full-thickness, swenson-like approach and Swenson abdominoperineal pull through for Hirschsprung's disease was conducted in the Department of Paediatric Surgery, Dhaka Shishu (Children) Hospital, Dhaka during the period of July 2014 to January 2016.

56 patients with Hirschsprung's disease having different length of colonic aganglionosis; with or without diverting colostomy were included by purposive sampling to form study sample volume. These 56 patients were grouped into: Group A, included 28 patients who were subjected to perform classic swenson procedure and in Group B, included 28 patients who were operated by Trans anal full thickness Swenson like pull through.

In this study, surgical complications, outcome, per operative cost and post operative hospital stay between the two groups were compared. In our study age range of the patients were 1 months to 96 months with the mean age 17.93 months. The mean ages of Group A and Group B were 21.16 ± 11.57 months and 14.71 ± 19.68 months. There was no significant difference (P value >0.05) between the mean ages. In group A the mean age is higher than group B. It might be due to intentional delay by the surgeons who perform Swenson pull through waits for definitive pull through operation until the baby gains 10 Lb weight. Whereas patients in group B who underwent transanal approach, mean age were 8.025 ± 11.23 months. In the study of Levit MA et al,⁴ mean age of the Patients were 18.8 ± 26 months, which is very close to the mean age of our study.

Regarding sex distribution, in group A that is in classic Swenson group 20 (37.71%) patients were male and 08 (14.29%) patients were female. On the other hand in group B 12 (21.43%) patients were male and 16 (28.57%) patients were female. Among the whole study group 32 (57.14%) were male patients and 24 (42.86%) were female patients. Male: Female ratio was 1.33:1. Our result is very similar with other studies like Zhang SC et al¹⁶ and Levit MA et al.⁴

After confirmation of the diagnosis by means of rectal biopsy or contrast enema and preoperative evaluation, definitive resection pull through was performed in all 56 patients. 28 patients in Group A were operated by abdominoperineal classic Swenson pull through and in 28 patients of Group B Trans anal full thickness Swenson like pull through. All the patients were followed up daily after pull through till discharge from the hospital and after discharge at 2nd, 4th, 8th and 12th weeks following operations.

In this study 4 (14.28%) patients in group A developed urinary incontinence where as no patients in group B developed urinary incontinence. Though incontinence cannot be judged beyond 3 years of age, in our study patients having urinary dribbling even after last follow up after 3 months was noted as

incontinence. In this context there is significant difference between 2 groups. Probably the massive pelvic dissection in Swenson abdominoperineal pull through leads to injury to the nerve plexus around the bladder and causes incontinence.¹⁷ In fact 9 patients in group A developed urinary dribbling post operatively, but in subsequent follow up on 8th and 12th week, we found that incontinence resolved in 5 patients and persisted in 4 patients. These 5 patients probably had neurogenic component which lead to overflow incontinence. Regarding group B, we noticed 4 patients had urinary dribbling after catheter removal. But in subsequent follow up on 8th week urinary dribbling of 3 patients resolved and in 1 patient, it resolved on 12th week. In the study of Zhang SC et al.¹⁶ showed 3.1% patients developed urinary incontinence, but he judged it after a long follow up more than 3 years. So we have to follow up more to conclude finally about urinary incontinence.

Regarding Pelvic or anastomotic or cuff abscess 3 patients in group A developed calf abscess. On the other hand 2 patients in group B developed pelvic and 2 patients developed anastomotic abscess. We performed 2 stage operation by exteriorising the labelling colostomy for that 3 patients of group A who developed calf abscess. On the other hand 2 patients of group B who developed pelvic abscess also underwent 2 stage operation. Moreover mean age of the patients of group B who developed abscess was 24.75 months which is much higher than the mean age of group B, and in these patients per operatively we found sign of inadequate decompression of ganglionic segment. Probably these things played role in more abscess formation in group B.¹⁸

Like urinary incontinence fecal incontinence should be judge after 3 years of age, moreover patients with stoma was ensured to have stoma closure 8 to 12 weeks of pullthrough, and patients having perianal fecal soiling during 12th weeks follow-up was labelled as fecal incontinence. Regarding this point of view 2 patients in group A developed fecal incontinence where as no patients in group B developed fecal incontinence. Zhang SC et al.¹⁶ showed 9.1% patients in their study developed fecal incontinence. In our study it is 7.14%. Both the result is very much similar.

Postoperative wound infection denotes infection of abdominal wound in case of abdominoperineal Swenson pull through and patients of Swenson like transanal pull through where laparotomy was done. Upon this condition 2 patients that is 7.14% patients in group A developed post operative wound infection. On the other hand developed wound infection as they did not need laparotomy. Statistically there is no difference between 2 groups. Wound infection was treated with wound swab C/S, regular dressing and culture sensitive antibiotics. Probably the higher operation time of group A patients influence more infection rate.

Regarding operation time, the mean operation time in group A was 114.14 ± 13.02 minutes and in group B it was 68.35 ± 25.60 minutes. Statistically there is significant gap between 2 groups. Prolonged operation time of group A might lead to high wound infection rate among group A patients. In the

study of Leily M et al. the mean operation time was 134.3±51.4 minutes.²⁰ Our mean operation time of abdominoperineal Swenson pull through was lower than the operation time taken by Leily et al.¹⁹ Both the results are not very much dissimilar.

In this study 2 patients in group-A developed post operative intestinal obstruction and no patient in group-B developed obstruction. This obstruction in group-A may be due to massive intestinal handling during pull through procedures.^{19,20}

Post operative hospital stay was ranges from 5 days to 7 days with the mean ± SD was 6.18 ± 1.82 days where as in group B range of post operative hospital stay was 4 to 6 days and mean was 5.04 ± 0.43 days. In group B 1 patient was discharged on request on 4th POD, that makes the range 4 to 6 days. After removal of the catheter on 5th POD, patients who developed retention, burning micturition or fever was kept admitted for more days. Moreover more wound infection among group A patients prolonged mean post operative hospital stay in group A patients.

Conclusion:

There is difference between Swenson abdominoperineal pull through and Transanal full thickness Swenson like pull through in context of operation time, hospital stay and urinary incontinence. Based on this resultstransanal full thickness Swenson like approach can be a good alternativein the treatment of short segment Hirschsprung's disease.

References:

- Jacob CL. 2004. Hirschsprung disease. in : JA O'Neil, MI Rowe, JA Grossfield, EW Fankalsrud, AG Coran, editors. Pediatric Surgery, 7thedn, vol 2. Missouri: Mosby year book, 1870-1895.
- Garipey C. Developmental disorders of the enteric nervous system: Genetic and molecular bases. J Pediatr Gastroenterol Nutr 2004; 39:5-11.
- Swenson O, Bill AH. Resection of rectum and rectosigmoid with preservation of the sphincter for benign spastic lesions producing megacolon: An experimental study. J Surg 1948; 24: 212-220.
- Skaba R. Historic milestones of Hirschsprung's disease (commemorating the 90th anniversary of Professor Harald Hirschsprung's death). J Pediatr Surg 2007; 42: 249-251.
- Levitt MA, Miller C, Hamrick BE, Andrea B, Jennifer H, Peña A. Transanal, full-thickness, Swenson-like approach for Hirschsprung disease. Journal of Pediatric Surgery 2013; 48: 2289-95.
- Swenson O, Bill AH. Resection of rectum and rectosigmoid with preservation of the sphincter for benign spastic lesions producing megacolon: An experimental study. J Surg 1948; 24: 212-20.
- Soave F. A new operation for the treatment of Hirschsprung's disease. J Pediatr Surg 1964; 56:1007-14.
- Duhamel B. A new operation for the treatment of Hirschsprung's disease. Arch Dis Child 1960; 35:38-39.
- Rehbein F, Von Zimmermann H. Results with abdominal resection in Hirschsprung's disease. Arch Dis Child 1960; 35:29-37.
- So HB, Schwartz DL, Becker JM, et al. Endo rectal pull through without preliminary colostomy in neonates with Hirschsprung's disease. J Pediatr Surg 1980; 15:470-1
- Eitelbaum DH, Coran AG. Primary pull through for hirschsprung's disease. Semin Neonatol 2003; 8:233-41.
- Latorre-Mondragon L, Ortega-Saldrago JA. Transanal endorectal pullthrough for Hirschsprung's disease. J Pediatr Surg 1998; 33:1283-6.
- Langer JC, Minkes RK, Mazziotti MV. Transanal one-stage Soave procedure for infants with Hirschsprung disease. J Pediatr Surg 1999; 34:148-52.
- Georgeson KE, Fuenfer MM, Hardin WD. Primary laparoscopic pull through for Hirschsprung's disease in infant and children. J Pediatr Surg 1995; 30:1017-22.
- Zhang SC, Bai YZ, Wang W. Long-term outcome, colonic motility, and sphincter performance after Swenson's procedure for Hirschsprung's disease: a single-center 2- decade experience with 346 cases. Amer J Surg 2007; 194: 40-47.
- Lange JC, Winthrop AL. Antegrade dilatation over a string for the management of anastomotic complications after a pull-through procedure. J Am Coll Surg 1996; 183:411-412.
- Holschneider AM, Kraeft H, Scholtissek C. Urodynamic investigation of bladder disturbances in imperforate anus and Hirschsprung's disease. Z Kinderchir 1982; 35:64-68
- Fonkalsrud EW. 2000. Complication of Hirschsprung's disease and allied disorders. In: Holschneider A.M., Puri, P. (eds). Hirschsprung's disease and allied disorders., 2nd edn. Harwood, Singapore. 425-431.
- Leily M, Ahmed KT, Mohsen R, et al. Comparison between Swenson and Soave pull through in Hirschsprung disease. Ann colorectal Res 2015; 3(4):e 32700.
- Dasgupta R, Langer JC. Evaluation and management of persistent problems after surgery for Hirschsprung disease in a child. J Pediatr Gastroenterol Nutr 2008; 46:13-19.