

Case Report

Lightning Injury

Rajib Hasan¹, Md. Motiul Islam², ARM Nooruzzaman³, Mohiuddin Ahmed³, Mohammad Rabiul Halim¹, Muhammad Mahbubur Rahman Bhuiyan¹, Muhammad Moshir Rahman¹, Kazi Nuruddin Ahmed¹, Tapash Chandra Roy⁴

Abstract

Lightning injuries are injuries caused by lightning strikes. Lightning delivers a massive electrical pulse over a fraction of a millisecond. It can kill a person by instantaneously short-circuiting the heart. Lightning injuries have been the second most common cause of storm-related death in the United States^{1,2,3}. Far more injuries and deaths occur in tropical and subtropical countries. Here we present the case report of a 45 year old Bangladeshi lady who was struck by lightning. Patient presented with immediate loss of consciousness and some superficial skin burn about 1 hour following the event. Over the next few days she was found to have intracerebral haemorrhage and infarct, tympanic membrane rupture and bilateral cataract. Surprisingly patient did not suffer from any cardiac or renal injury. All lightning strike victims should receive emergency medical support on site of injury and be treated in intensive care units (ICU) equipped with multiple organ support facility.

Introduction

For most thunderstorms, 90% of lightning strikes from cloud to cloud. From 10-30% of lightning can be cloud to ground, depending on the storm. Lightning strikes the earth more than 100 times each second and 8 million times per day. Worldwide, approximately 50,000 thunderstorms occur per day that may result in forest fires, injury to animals and people and damage to electrical and communications lines and electronics⁴. Since lightning is caused by common meteorological conditions, anyone is a potential victim.

Case Report

Mrs. X, a 45 years old non-diabetic, normotensive previously healthy lady hailing from Enayetpur, Sirajgonj got admitted to the medical ICU of a tertiary care hospital through Emergency Room (ER) with the complaints of unconsciousness, labored breathing, feeble pulse, unrecordable blood pressure & superficial burn injury over face, scalp, chest and thigh following hit by a lightning strike during a thunderstorm about 1 hour back. Patient got struck by a lightning bolt one hour back while she was sitting beside a pond. Following the strike patient fell from sitting position and did not sustain any injury due to fall. There was no history

of vomiting or convulsion. There were four people altogether at the site of the lightning strike; two children, one young lady and the discussed patient. The two children were dead on spot but the young lady suffered mild physical trauma with rupture of tympanic membrane.

After admission in ICU patient was thoroughly evaluated. She was unconscious with GCS scoring of 5/15 (E₁, V₂, M₂), pupils were bilateral 4.5 mm and sluggishly reacting to light, planter response were bilaterally extensor. She was hemodynamically unstable with heart rate of 100 bpm, sinus rhythm and BP of 80/60 mm of Hg. Respiration was labored with SpO₂ of 80% with 5L O₂ through face mask. Arterial blood gas analysis showed features of type I respiratory failure. Patient was having profuse vomiting. On physical examination she was noted to have multiple superficial burn injury over face, neck, chest and lateral part of right thigh. ENT examination was normal with intact tympanic membranes and ophthalmological examination also revealed no abnormalities.

After initial assessment immediate attempts were made for resuscitation of the patient by endotracheal intubation and putting on mechanical ventilator support to correct hypoxia. Intravenous pressors were started after adequate fluid resuscitation to achieve hemodynamic stability. All supportive care were established according to the standard ICU protocol. All baseline investigations were sent.

Following initial resuscitative measures patient got stabilized hemodynamically with pressor support, hypoxia was corrected, urine output was adequate. Blood reports showed neutrophilic leukocytosis with mildly raised troponin I and moderately raised creatine phosphokinase (CPK). Liver function, kidney function and other reports were within normal limits. Bedside echo was normal with no regional wall motion abnormalities with LVEF of 60%.

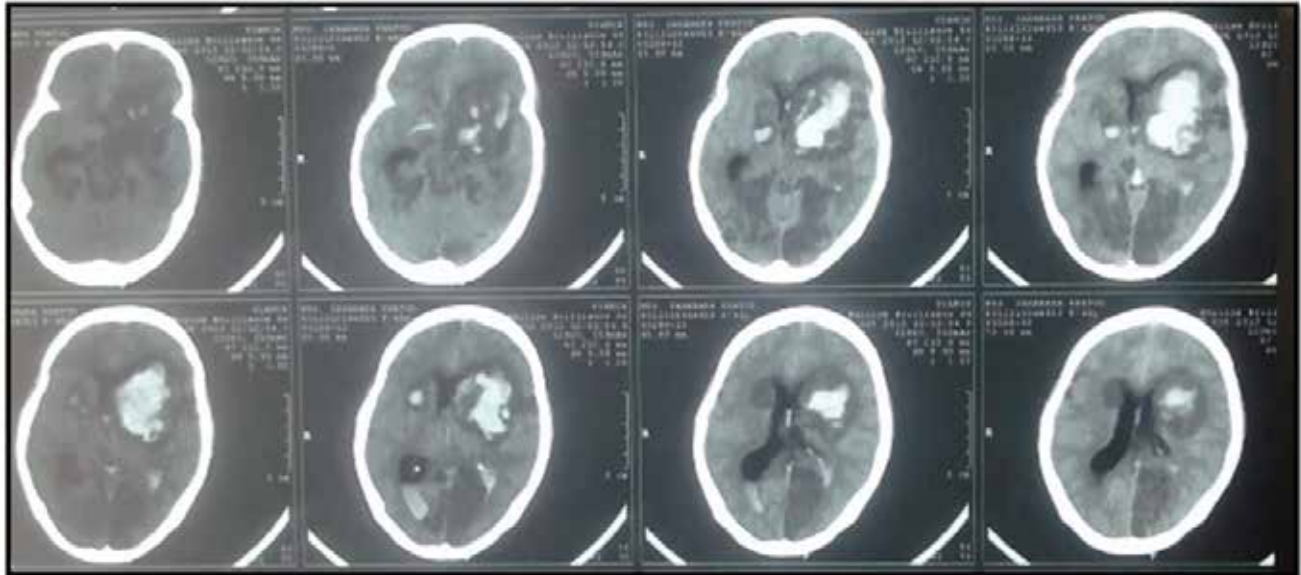
On the second day during her stay in ICU, patient's vitals became more stabilized. BP was stable without any pressor support, urine output remained adequate. Lab reports also showed improvement with down going troponin I and CPK.

1. Senior Clinical Staff, ICU, Asgar Ali Hospital 111/1/A, Distillery Road, Gandaria, Dhaka-1204, Bangladesh.
2. Associate Consultant, Medical ICU, Asgar Ali Hospital, 111/1/A, Distillery Road, Gandaria, Dhaka-1204, Bangladesh.
3. Consultant, Internal Medicine & ICU, Asgar Ali Hospital, 111/1/A, Distillery Road, Gandaria, Dhaka-1204, Bangladesh.
4. Resident Medical Officer, ICU, Asgar Ali Hospital, 111/1/A, Distillery Road, Gandaria, Dhaka-1204, Bangladesh.

Corresponding Author:

Dr. Rajib Hasan (MBBS, FICM)
Senior Clinical Staff, ICU,
Asgar Ali Hospital, 111/1/A, Distillery Road, Gandaria,
Dhaka-1204, Bangladesh.
Email: dr.rajab.icu@gmail.com

But there was bloody discharge from the right auditory canal. Otoloscope examination revealed ruptured tympanic membrane. Patient's pupils were also becoming increasingly non-reacting to light. Ophthalmological examination revealed development of bilateral cataract. Patient's level of consciousness however remained unchanged at GCS 5/15. She was still on mechanical ventilator support though oxygen requirement was gradually decreasing.



On the third day, as the patient was not improving neurologically, a CT scan of brain and brainstem was done which revealed "Bilateral capsulo basalganglionic acute haematoma with intraventricular extension with acute occipital and brainstem infarct". Patient's management was headed by an intensivist and special support was taken from internist, cardiologist, general surgeon, ophthalmologist, ENT surgeon and neurosurgeon. Neurosurgical intervention was advised but patient's next of kin denied any surgical treatment although her clinical condition including possible poor prognosis was discussed in details with her relatives. The following day, patient was transferred to a different facility against our medical advice and eventually we lost contact with the patient.

Discussion

Two-thirds of lightning-associated deaths occur within one hour of injury and are generally due to a fatal arrhythmia or respiratory failure⁵. Approximately 30 percent of those struck by lightning die and up to 74 percent of survivors may have permanent disabilities⁶.

Lightning injury is caused by a DC current exposure that lasts from 1/10 to 1/1000 of a second, but often has voltages that exceed 10 million volts. Peak temperature within a bolt of lightning rises within milliseconds to 30,000 Kelvin (five times hotter than the sun), generating a shock wave of up to 20 atmospheres induced by the rapid heating of the surrounding air^{7,8,9}. This shock wave then can be transmitted through the body and result in mechanical trauma. Injuries due to

electricity occur by three mechanisms¹⁰:

- Direct effect of electrical current on body tissues
- Conversion of electrical energy to thermal energy, resulting in deep and superficial burns
- Blunt mechanical injury from lightning strike, muscle contraction, or as a complication of a fall after electrocution.

Serious lightning injuries are likely to primarily cause cardiac and neurologic injury. Otologic injury and cutaneous burns have also been noted as frequent sequelae of these events. Cataract formation resulting from lightning injury typically occurs within days to weeks of injury, as was the case in our patient.

American Heart Association recommends, prolonged cardiopulmonary resuscitation (CPR) should be undertaken following electrical injury regardless of the initial rhythm, since most victims are young and good outcomes have been noted even among patients with asystole¹¹. The treatment for particular arrhythmias is unchanged. Patients can have spontaneous cardiac activity but paralysis of the respiratory muscles. Prompt restoration of gas exchange via a secure airway may prevent secondary cardiac and neurologic dysfunction or death. However, in our patient there was no cardiac involvement or arrhythmia and cardiac resuscitation was not needed.

The person who suffers a serious lightning strike has sustained significant trauma. Appropriate trauma resuscitation should be performed, beginning with a rapid assessment of the airway and cardiopulmonary status. Cervical spine immobilization is necessary, and tetanus prophylaxis should be administered.

Neurologic complications after lightning consist of: 1) immediate and transient variety presenting with the symptomatology which includes loss of consciousness, amnesia, confusion, headache, paresthesia, and weakness; 2) immediate and prolonged or permanent variety which

includes post-hypoxic-ischemic encephalopathy, intracranial hemorrhages, cerebral infarction and cerebellar syndromes; 3) delayed presentation after weeks to months including motor system disease and movement disorders and 4) destructive injuries secondary to falls¹². Our patient's neurological complications fall in the second category as she had bilateral basal ganglia haemorrhage with occipital and brainstem infarct.

Intracranial hemorrhages in lightning-strike patients often appear in basal ganglia¹³⁻¹⁶. Studies suggest that current may enter via orifices (eyes, nose, ears) and travel caudally from neocortex toward the basal ganglia and brainstem¹². Blood vessels and neural tissue have been found to carry more current per unit area than the other tissues and to become damaged before the surrounding tissues, in an animal model. Preferential conduction along Virchow-Robin spaces in the anterior perforated substance has been a proposed mechanism of bleed after a lightning strike¹⁴. However, this mechanism does not explain the predilection for basal ganglia, as was the case in our patient.

Patients with soft tissue injuries from a severe electrical exposure require aggressive IV fluid replacement, especially if there are signs of muscle necrosis. The approach to fluid resuscitation in lightning is similar to that used for the prevention of acute kidney injury from rhabdomyolysis. Our patient had no muscle injury as evidenced by mildly raised CPK.

In general, wounds in lightning injury patients are treated in a similar manner to flame or other thermal burns. Patients with burns may require transfer to a burn unit and treatment with fasciotomy, escharotomy, extensive skin reconstruction, or limb amputation. Our patient only sustained superficial skin burns which was treated by topical antibiotics and frequent dressing.

After stabilization, careful otologic and audiometric examinations may reveal injuries that are amenable to delayed repair. Ophthalmologic evaluation is warranted because of the potential for delayed development of cataracts, particularly following lightning injury. Cataracts generally develop several days after injury, though there may be a lag of up to two years. Our patient developed bilateral cataract and ruptured tympanic membrane on the second day after injury.

In case of patients who recover from the various types of injury sustained by lightning attack, early institution of physical therapy may prevent deterioration in functional status, and psychiatric consultation may be required for patients who develop behavioral disturbances or post-traumatic stress disorder.

References :

1. Centers for Disease Control and Prevention. Lightning-associated deaths-United States, 1980-1995. *Morbidity Mortality Weekly Reports*. 391-4. 1998.
2. Jensenius JS. A detailed analysis of recent lightning deaths in the United States. 23rd International Lightning Detection Conference; 2014.
3. Roeder WP. Lightning has fallen to third leading source of US storm deaths. National Weather Association Annual Meeting; 2012.
4. Okafor UV. Lightning and acute renal failure: A review. *Ren Fail* 2005; 27:129-34.
5. Blumenthal R. Lightning fatalities on the South African Highveld: a retrospective descriptive study for the period 1997-2000. *Am J Forensic Med Pathol* 2005; 26(1):66-9
6. Whitecomb D, Martinez J A, Daberkow D. Lightning injuries. *South Med J* 2002; 95:1331-4.
7. Bier M, Chen W, Bodnar E, Lee RC. Biophysical injury mechanisms associated with lightning injury. *Neurorehabilitation* 2005; 20(1):53-62.
8. Lee RC. Injury by electrical forces: Pathophysiology, manifestations, and therapy. *Curr Probl Surg* 1997; 34(9):677-764.
9. Lee RC, Zhang D, Hannig J. Biophysical injury mechanisms in electrical shock trauma. *Annu Rev Biomed Eng* 2000; 2:477-509.
10. Cooper MA. A fifth mechanism of Lightning injury. *Acad Emerg Med* 2002; 9(2):172-4
11. Anonymous. Part 8: advanced challenges in resuscitation. Section 3: special challenges in ECC. 3G: electric shock and lightning strikes. European Resuscitation Council. *Resuscitation* 2000; 46(1-3):297-9.
12. Cherington M. Neurologic manifestations of lightning strikes. *Neurology*. 2003;60:182-5
13. Carrera-Izquierdo E, Morán-Sánchez JC, Carrera-Izquierdo M, Jiménez-Corral C, Rodríguez-Recio FJ, Ocastegui-Candial JL. Intracranial haemorrhage secondary to a lightning strike: A case report. *Rev Neurol*.2004;39:530-2.
14. Ozgun B, Castillo M. Basal ganglia hemorrhage related to lightning strike. *AJNR Am J Neuroradiol*.1995;16:1370-1.
15. Stanley LD, Suss RA. Intracerebral hematoma secondary to lightning stroke: Case report and review of the literature. *Neurosurgery*. 1985;16:686-8.
16. Thomas M, Pillai M, Krishna Das KV. Intracranial haematoma resulting from lightning stroke. *J Assoc Physicians India*. 1991;39:421-2.