

## Case Report

# A 46, XX / 46, XY mosaicism or chimerism diagnosed by Karyotyping

Mansura Khan<sup>1</sup>, Mohammad Moniruzzaman<sup>2</sup>, Fauzia Mohsin<sup>3</sup>, Ashesh K. Chowdhury<sup>4</sup>

### Abstract:

*The presence of both 46, XX and 46, XY cell lines in a person is a very rare condition which is known as either chimerism or mosaicism. These conditions usually determined in early childhood during investigation of ambiguous genitalia. Our case is probably the first such report case in our country. Our case was ten months aged child, born to non-consanguineous couple referred to Cytogenetics unit of Immunology Department of BIRDEM General Hospital for chromosomal analysis and Karyotyping with the chief complaint of right sided undescended testis. He was normal looking and playful, presenting complaint was small penis with abnormal urethral opening and absence of one testis since birth. His developmental milestones were normal and intelligence was average. There was no history of congenital and genetic diseases in their family. On examination of the external genitalia the following features were noticed: stretched penile length (SPL) 3.5 cm with penoscrotal hypospadiasis. Right sided testis was not palpable as undescended and left sided testis was palpable in scrotum, volume of which was 2 to 3 ml.*

**Key words:** Chimerism, Mosaicism.

### Introduction:

The presence of both 46, XX and 46, XY cell lines in a person is known as either chimerism or mosaicism. A chimera is an individual with two or more cell lines derived from different zygotes. In mosaicism, on the other hand, two or more cell lines come from the same zygote as a result of non-disjunction during mitotic division. Phenotypic characteristics may vary from individual to individual from normal genitalia, ambiguous genitalia to ovotesticular disorder of sexual development (DSD).

Mosaicism can be distinguished from chimerism with genetic analysis in certain circumstances. In an individual with mosaic pattern showed some cells have the male chromosomal complement (XY) and some cells have the female chromosomal complement (XX). Chimerism may occur either during in-vitro fertilization or naturally during pregnancy, when two non identical zygotes developed in a single fetus at a very early stage of development. Chimerism also occurs during intrauterine transfusion, allogenic bone

marrow transplantation and exchange of blood cells, via the placenta, between non-identical twins in uterus<sup>1</sup>. As the result chimera may possess cells that have different sets of chromosome. In present case, we describe an infant having right sided undescended testis with 46, XX/46, XY in lymphocyte culture, which is a rare condition.

### Case Case report:

A ten months aged child, born to nonconsanguineous couple was referred to cytogenetic unit of Immunology Department of BIRDEM General Hospital for chromosomal analysis and Karyotyping with the chief complaint of ambiguous genitalia. A detailed family history, clinical information, physical examination, reference for relevant special investigations were recorded after coming in the department.

For chromosomal analysis, conventional peripheral lymphocyte culture was done by the standard method using the G-banding technique. The protocol employed for karyotyping was as follows: about 2 ml of heparinized blood was collected in a syringe from peripheral veins of the referred patient. Lymphocytes were grown in RPMI (Roswell Park Memorial Institute)-1640, media containing antibiotics (penicillin and streptomycin) and 15% serum supplementation (fetal bovine serum). The phytohaemagglutinin (PHA) was added as a mitotic stimulant and the samples were incubated for 72 hours at 37°C in 5% CO<sub>2</sub> incubator (Forma Scientific, USA). The cells were arrested at metaphase stage of cell cycle with 0.1% colchicines after the incubation. Then after one hour of incubation (with colchicines) the cells were treated with KCL hypotonic solution. After that, the cells were fixed by three times wash with fixative solution (3:1; methanol: glacial acetic acid). All the reagents used were from Sigma Aldrich, Germany. The slides were then stained with Giemsa and air dried. Chromosome analysis was done under 100X magnification. At least 70 metaphase spreads were screened for this patient.

1. Dr. Mansura Khan, Assistant Professor, Department of Immunology, BIRDEM General Hospital, Dhaka - 1000.
2. Dr. Mohammad Moniruzzaman, Assistant Professor, Department of Immunology, Bangladesh University of Health Sciences, Dhaka - 1216.
3. Dr. Fauzia Mohsin, Professor, Pediatric Endocrinology Unit, Department of Endocrinology, BIRDEM General Hospital-2, Dhaka - 1000.
4. Dr. Ashesh Kumar Chowdhury, Professor and Head, Department of Immunology, BIRDEM General Hospital, Dhaka - 1000.

### Corresponding Author:

Dr. Mansura Khan  
Assistant Professor,  
Department of Immunology, BIRDEM General Hospital, Dhaka - 1000.  
Contact- +88 01817075095  
Email: mansura24@yahoo.com

The child was only child and referred to us as male. He was normal looking and playful, presenting complaint was small penis with abnormal urethral opening and absence of one testis since birth. His developmental milestones were normal and intelligence was average. There was no history of congenital and genetic diseases in their family. On examination of the external genitalia the following features were noticed: stretched penile length (SPL) 3.5 cm with penoscrotal hypospadias. Right sided testis was not palpable due to undescended testis and left sided testis was palpable in scrotal which volume was 2 to 3 ml (Fig: 1)

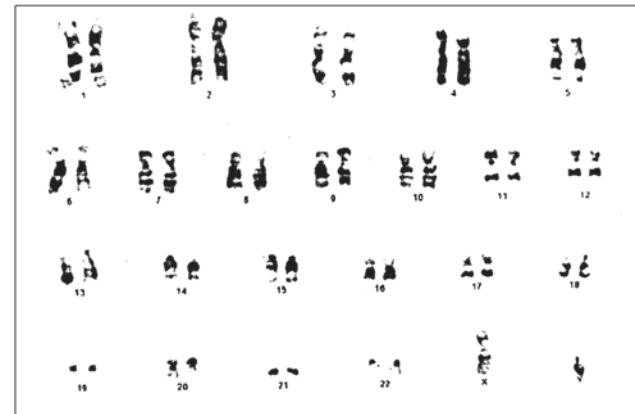
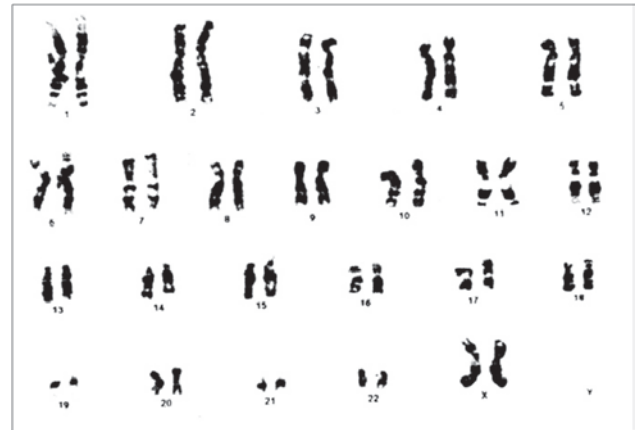
**Fig 1:** Showing small penis with underdeveloped scrotum of the patient.

**Investigation:**

Serum level of testosterone was 0.19 ng/ml (0.01- 1.77), luteinizing hormone 6.16 mIU/ ml (<0.3) and follicular stimulating hormone 0.21 mIU/ml (<4). In ultrasonography abdominal organs appeared normal, no uterus and ovary like structure were detected; left testis was seen in scrotal sac measuring about (18.4x 8) mm.

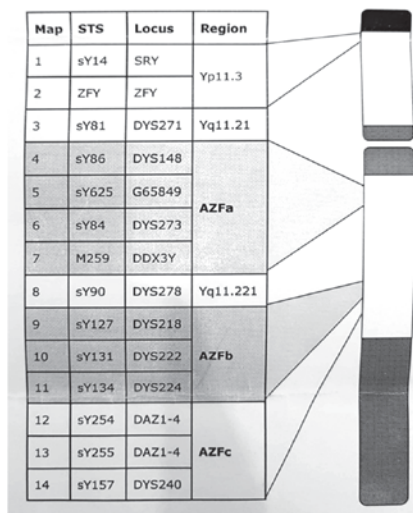
In chromosome analysis by lymphocyte culture method we counted more than 70 metaphase spreads which revealed two cell line and we found 70% normal female and 30% normal male Karyotype (46,XX/ 46,XY). To confirm this diagnosis we sent patients sample to other lab for Karyogram. They also counted 40 metaphase spreads which also showed two cell line (25 normal female Karyotype and 15 normal male Karyotype) (figure-2).



**Fig 2:** Karyogram showing both male 46, XY (above) and female 46, XX (below) Karyotype in same patients.

We also did Y chromosome analysis by Quantitative fluorescence- PCR. There we found normal Y chromosome and no evidence of micro-deletion at AZFa, AZFb, AZFc and SRY region of Y chromosome (figure-3).

Schematic overview of the marker positions on the Y-chromosome.



**Figure 3:** PCR showing sequence specific tag (STS) markers are specific for Y chromosome.

### Discussion:

Review of literature revealed with DSD individuals 6.06% (2/33) of patients showed 46,XX/46,XY Karyotype<sup>2</sup> and in another study 0.1% (1/916) patients referred as male and karyotyping showed 46,XX/46,XY chromosomes<sup>3</sup>. Auruna and her colleagues<sup>4</sup> found only one (3.45%) individual out of 29 consecutively referral for ambiguous genitalia over a period of three years presented with 46,XX/46,XY Karyotype. The true frequency of the genotype is unknown because every patients with ambiguous genitalia was not referred for genetic analysis. Rare cases of chimerism or mosaicism with both normal male and normal female genotype have also been ascertained as an incidental finding<sup>5</sup>. In normal fertile males same type of mosaicism<sup>6,7</sup> and fertile females with mosaicism<sup>5</sup> were also reported. Fertile female with phenotypically normal features with 46,XX/ 46,XY Karyotype also reported<sup>7</sup>. However, only one case of 46,XX/46,XY mosaicism ascertained prenatally with molecular analysis has been described in the literature<sup>8</sup>.

In our study affected infant was found with a normal male phenotype. Our case is the first reported infant diagnosed case of a 46,XX /46,XY phenotypic male child in Bangladesh. Several mechanisms might exist for mosaics. Yaron et al<sup>8</sup> explained two theoretical mechanisms of 46,XY /46,XX mosaicism. In one of the two, a nondisjunction occurs at meiosis 2 during oogenesis, leading to a 24,XX oocyte, which develops into a 47,XXY zygote after fertilization with a normal 23,Y sperm cell. Another mechanism might involve nondisjunction during early embryogenesis.

In infancy any patient with hypospadias and undescended testis should be advised for karyotyping or karyogram for gender determination. For late diagnosis, there is a possibility

for the patient to develop malignancy in undescended gonad is greater and issues of fertility may become significant. Male sex was ascertained to the present case. Regular follow up by an experienced team is the best approach including specialists from pediatrics, gynecology, surgery, urology, endocrinology and psychiatry.

### Reference:

1. Van Dijk BA, Boomsma DI, De Man AJ. Blood group chimerism in human multiple births is not rare. *American Journal of Medical Genetics* 1996; 61: 264–68.
2. Zhen-Guo MI, Xiao-Feng Y. Karyotypic analysis of intersexuality in Chinese from Taiyuan Asian. *Journal of Andrology* 2000; 2: 155-57.
3. Duarte AC, Cunha E, Roth JM. Cytogenetics of Genetic Counseling Patients in Pelotas, Rio Grande do Sul, Brazil. *The Genetics and Molecular Research Journal* 2004; 3(3): 303-08.
4. Aruna N, Purushottam RM, Rajangam S. 46,XX/46, XY Chimerism – A Case Report. *Journal of the Anatomical Society of India* 2006; 55 (1): 24-26.
5. Bromilow IM, Duguid J. The Liverpool chimera. *Vox Sanguinis*, 1989; 57: 147-149.
6. Watkins WM, Yates AD. A human dispermic chimaera first suspected from analyses of the blood group gene-specified glycosyl transferases. *Journal of Immunogenetics* 1981; 8: 113-28.
7. Schoenle E, Schmid W. 46,XX/46,XY Chimerism in a phenotypically normal man. *Human Genetics* 1983; 64: 86-89.
8. Yaron Y, Feldman B, Kramer RL. Prenatal diagnosis of 46,XY/46,XX mosaicism: a case report. *American Journal of Medical Genetic,s* 1999; 84: 12–14.