

Clinical Image

Large Cerebral Arachnoid Cyst

Md Atiquzzaman¹, Mohammad Omar Faruq², Mohammad Rabiul Halim³, Md Ashikuzzaman Sohan⁴

A 55-year-old normotensive, non-diabetic lady was admitted to an ICU in Dhaka with the complaints of gradual weakness of left side of body for 1 month. She had no history of fever, headache, vomiting, convulsion & head trauma. On examination, she was conscious, oriented, all cranial nerves were intact, pupils were bilaterally equal, normal sized and reacting to light. Muscle power was normal in right side of body but there was grade 4 weakness in left upper and lower limb, planter reflex was flexor on right, extensor on left side. A CT scan of head done prior to admission in this ICU was suggestive of a large arachnoid cyst. Eventually an MRI of brain done, which revealed a large arachnoid cyst in right fronto-parietal lobe. (Fig 1, 2 & 3)

Finally, a cysto-peritoneal shunting was done for continuous drainage of cystic fluid.

From 1st post-operative day (POD) onward, patient's neurological symptoms started to disappear, and on 3rd POD she was transferred out of ICU without any residual weakness in stable condition.

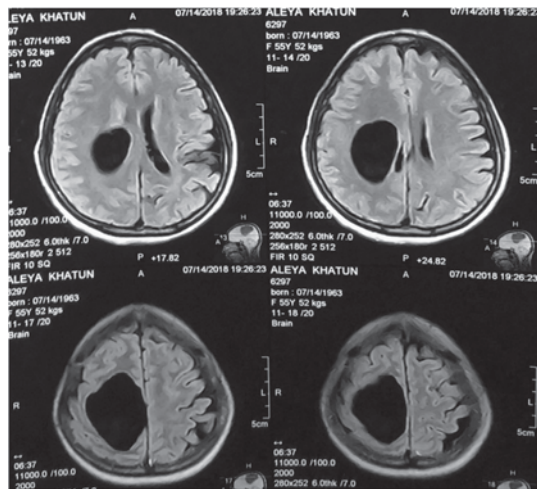


Figure 1: Axial FLAIR MR image showing a large arachnoid cyst in right fronto-parietal lobe.

1. Clinical Staff, General ICU, Asgar Ali Hospital.
2. Consultant, General ICU, United Hospital Limited.
3. Senior Clinical Staff, General ICU, Asgar Ali Hospital.
4. Medical Officer, ICU, Dhanmondi Clinic (Pvt.) Ltd.

Corresponding Author:

Dr. Md. Atiquzzaman
 MBBS
 Clinical Staff, General ICU, Asgar Ali Hospital
 111/1/A, Distillery Road, Gandaria, Dhaka-1204, Bangladesh.
 E mail: drazrinku@gmail.com
 Contact: +8801711939036

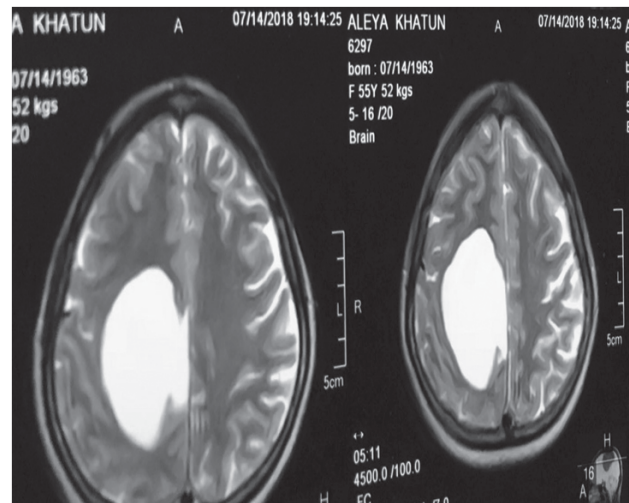


Figure 2: Axial T2 weighted MR image showing a large arachnoid cyst in right fronto-parietal lobe.

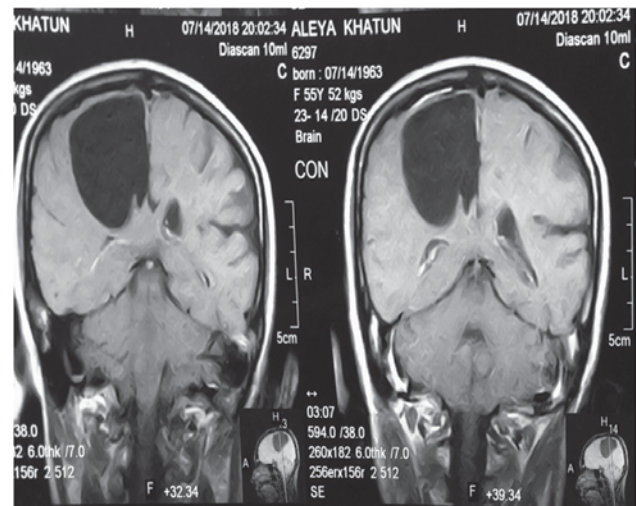


Figure 3: Coronal gadolinium enhanced T1 weighted MR image showing a large arachnoid cyst with no contrast enhancement in right fronto-parietal lobe.

Discussion

Arachnoid cysts are benign and the commonest cystic congenital abnormality of the brain. They constitute approximately 1% of intracranial masses; 50-60% occur in the middle cranial fossa. A small number of arachnoid cysts are acquired, such as those occurring in association with tumors or those resulting from adhesions occurring in association with leptomeningitis, hemorrhage, or surgery¹. They occur in the cerebrospinal axis in relation to the arachnoid membrane and that do not communicate with the ventricular system. They usually contain clear, colorless fluid

that is most likely normal cerebrospinal fluid; rarely, they contain xanthochromic fluid. Microscopic examination usually reveals a cyst wall that resembles normal arachnoid. Usually, arachnoid cysts are asymptomatic; even they are quite large. The most commonly associated clinical features are headache, calvarial bulging, and seizures; focal neurologic signs occur less frequently².

Arachnoid cysts also occur within the spinal canal; in such cases, they are commonly located dorsal to the cord in the thoracic region. Spinal arachnoid cysts are generally misdiagnosed, because symptoms are often nonspecific. Often, the cysts are an incidental finding on MRI^{1,9}.

Controversy surrounds the treatment of arachnoid cysts. Some advocate treating only the symptomatic cysts, whereas others believe that even asymptomatic cysts should be decompressed to avoid future complications. Surgical treatment options include either craniotomy, open fenestration of the cyst, stereotactic cyst aspiration, endoscopic cyst fenestration, or cysto-peritoneal shunt placement^{1,2,3}. Cysts that cause symptoms from cord compression; should be surgically excised, if possible¹⁰.

There is a wide differential diagnosis for both intracranial and intraspinal cystic lesions and arachnoid cysts have several mimics¹.

On CT scans, arachnoid cysts are characterized by sharp, nonenhancing borders; they are isodense to CSF. On a bone window, remodeling of the skull may be evident. Arachnoid cysts seldom calcify. On CT cisternography, arachnoid cysts may be seen to have a smooth outer surface, in contradistinction to epidermoid cysts, which typically have an irregular outer surface that is likened to the surface of cauliflower. Noncommunicating and slow-filling cysts are regarded as true arachnoid cysts, whereas communicating cysts are regarded as diverticula of the subarachnoid space^{1,4}.

MRI is the definitive diagnostic tool. On MRI, arachnoid cysts appear as well-defined nonenhancing intracranial masses that are isointense to CSF. Diagnostic confusion usually arises between arachnoid cysts and epidermoid cysts. They have similar characteristics on T1 and T2-weighted images, and neither shows enhancement with gadolinium. FLAIR imaging shows no signal arising from the CSF, therefore, FLAIR sequences demonstrate a low signal in arachnoid cysts that contain CSF; in epidermoid cysts, that signal is typically higher. There are occasions when an epidermoid cysts may appear low-intensity lesion on FLAIR. This dilemma is resolved with the use of diffusion weighted imaging (DWIs), on which the signal intensity of arachnoid cysts is low; epidermoid cysts remain bright. A large cisterna magna (mega cisterna magna) occasionally may be confused

with an arachnoid cyst. They both show CSF characteristics on T1-weighted, T2-weighted, DWI, and FLAIR sequences. However, an arachnoid cyst may demonstrate mass effect with an en bloc displacement of the cerebellum and vermis, normal-variant mega cisterna magna demonstrates no mass effect, and the cerebellum and vermis remain intact. MRI of spinal arachnoid cysts demonstrates an oval, sharply demarcated extramedullary mass that may cause spinal cord compression. The cyst is usually hyperintense to CSF on T2-weighted sequences because of the relative lack of CSF pulsation artifacts^{1,5,6,7,8}.

Every effort must be made to reliably detect arachnoid cysts as well as to be differentiated from the more serious cystic intracranial and intraspinal tumors. In asymptomatic larger arachnoid cysts, consideration should be given to the use of serial scans, because such cysts may enlarge over time; patients with such cysts may become candidates for surgery.

References:

1. Logan C, Asadi H, Kok HK, Looby S, O'Hare A. Arachnoid Cysts - Common and Uncommon Clinical Presentations and Radiological Features. *J Neuroimaging Psychiatry Neurol.* 2016; 1(2): 79-84.
2. Gustavo Pradilla, George Jallo. Arachnoid cysts: case series and review of the literature. *Neurosurg Focus.* 2007; 22 (2): 1-4.
3. Zeng L, Feng L, Wang J. Comparative study on two surgical procedures for middle cranial fossa arachnoid cysts. *J Huazhong UnivSciTechnolog Med Sci.* 2008; 28(4):431-4.
4. HarunYildiz, CuneytErdogan, RamazanYalcin, ZeynepYazici, BahattinHakyemez, MufitParlak, et al. Evaluation of Communication between Intracranial Arachnoid Cysts and Cisterns with Phase-Contrast Cine MR Imaging. *American Journal of Neuroradiology.* 2005; 26 (1): 145-151.
5. J S Tsruda, W M Chew, M E Moseley, D Norman. Diffusion-Weighted MR Imaging of the Brain: Value of Differentiating Between Extraaxial Cysts and Epidermoid Tumors. *American Journal of Roentgenology.* 1990 Nov; 155: 1059-1065.
6. Hakyemez B, Yildiz H, Ergin N, Uysal S, Parlak M. Flair and diffusion weighted MR imaging in differentiating epidermoid cysts from arachnoid cysts. *TaniGirisimRadyol.* 2003 ;9(4):418-26.
7. Dutt SN, Mirza S, Chavda SV, Irving RM. Radiologic differentiation of intracranial epidermoids from arachnoid cysts. *OtolNeurotol.* 2002;23(1):84-92.
8. Hu XY, Hu CH, Fang XM, Cui L, Zhang QH. Intraparenchymalepidermoid cysts in the brain: diagnostic value of MR diffusion-weighted imaging. *ClinRadiol.* 2008; 63(7):813-8.
9. Garg K, Borkar SA, Kale SS, Sharma BS. Spinal arachnoid cysts - our experience and review of literature. *Br J Neurosurg.* 2017; 31(2):172-178.
10. Hughes G, Ugokwe K, Benzel EC. A review of spinal arachnoid cysts. *Cleve Clin J Med.* 2008; 75(4):311-5.