

## Case Report

### Lipoma in Penis : A Rare Case Report

AHMED T<sup>1</sup>, KALAM MA<sup>2</sup>, MANNAN II<sup>3</sup>, SIMI MA<sup>4</sup>

#### Abstract

*In this article we report one case of lipoma of the penis in a twenty three years old young male. This site of lipoma is rare. A case of a young male patient who consulted for removal of a penile lump is presented. The small, regular, well-circumscribed pedunculated tumor localized on the ventral aspect of the penis was excised. The histopathological analysis showed a benign lipoma. A review of the literature showed lipoma of the penis to be very uncommon. For this reason, we were prompted to report this case.*

**Key Words:** Lipoma in penis, Penile lipoma

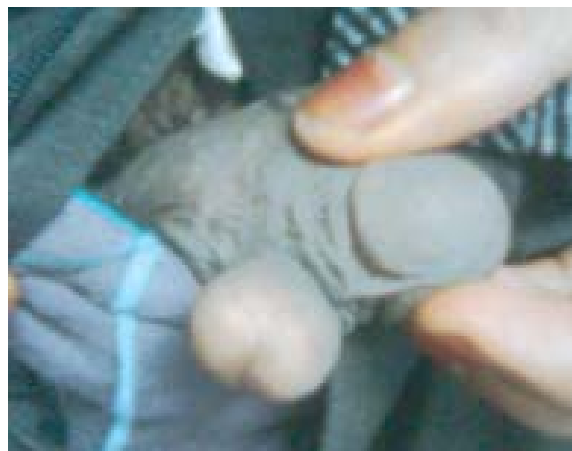#### Introduction

Lipoma is a benign tumour of adipocytes<sup>1</sup>. It is the most common form of soft tissue tumor in human body. They are frequently encountered in adults, and account for almost 5% of all soft tissue tumours<sup>2,3,4</sup>. They rarely present before the third decade of life and with slight gender predilection for males<sup>3</sup>. Most of the lipomas arise in the trunk that is 38%, while in the limbs is 35%. On the other hand 13% of the lipomas arise in the head and neck region while the oral cavity incidence is 1.0% - 4.5% of all benign oral lesions<sup>2</sup>. But lipoma in penis is extremely rare<sup>4</sup>. Most lipomas grow slowly and their exact aetiology is unknown but some implicated factors include trauma, infection, chronic irritation and hormonal alterations<sup>3,5,6</sup>. The tendency to develop a lipoma is not necessarily hereditary although hereditary conditions, such as familial multiple lipomatosis, may include lipoma development. The most common type is the 'superficial subcutaneous lipoma'. The characteristic appearance is a smooth surfaced, well circumscribed encapsulated nodular mass, yellowish pink cut margin covered by a readily vascular network<sup>3,6,7</sup>. Some published literatures claim that malignant transformation can occur<sup>2</sup>, while others say that this has yet to be convincingly documented<sup>3,8</sup>. Lipomas are rarely life-threatening but lipomas growing in internal organs can be more dangerous<sup>3</sup>. Common subcutaneous lipomas are not a serious condition.

If the lipoma develops in penis, it may cause sexual dysfunction by mechanical obstruction during penetration<sup>4</sup>.

#### Case Report

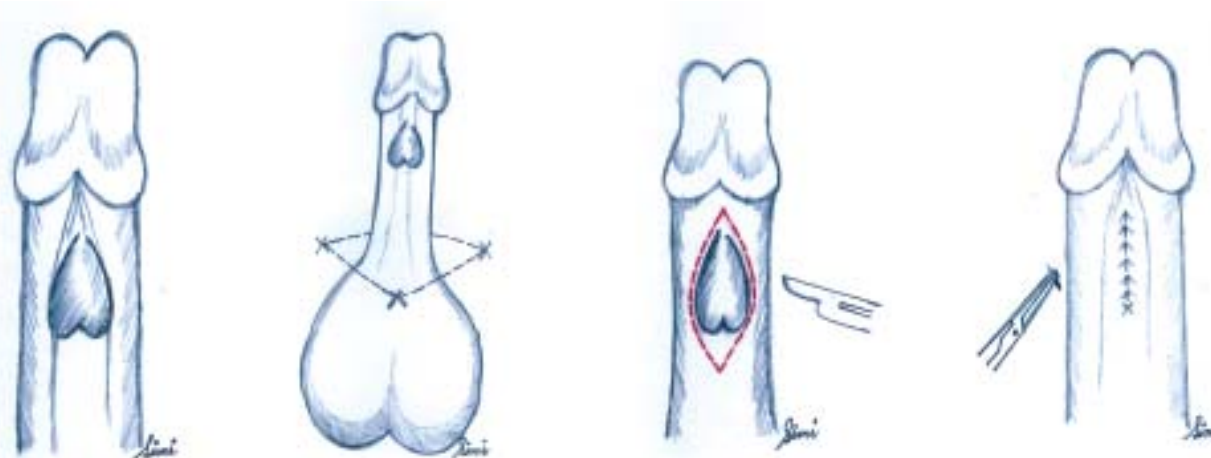
A twenty three years old married male patient presented at the surgical outpatient department with a small heart shaped swelling on the ventral aspect of the penile shaft with some sexual dysfunction due to mechanical obstruction for last 3 months following marriage. In the past, the lesion never caused any symptom but after marriage, although unchanged in size, he was affected due to difficulty in penetration. The pedunculated, regular, well-circumscribed & lobulated tumor on the dorsal penile aspect was slowly growing painlessly for last 9 to 10 years and was measuring about 2.5 cm X 2 cm. Investigation for other causes of sexual dysfunction was negative and he was suggested for surgical removal. Surgical excision of the lump was done along with overlying skin under penile block. Histopathological examination of the excised tumor showed that the mass was consisted of mature adipose cells revealed benign lipoma. The patient recovered from the mechanical dysfunction thereof and improves both aesthetically and psychologically.



**Fig.-1:** Showing the heart shaped lipoma in the ventrum of the penis.

1. Dr. Tanveer Ahmed, Assistant Registrar, Department of Plastic Surgery, Dhaka Medical College Hospital, Bangladesh
2. Professor Md. Abul Kalam, Professor and Head, Department of Plastic Surgery, Dhaka Medical College Hospital, Bangladesh
3. Dr. Iftekhar Ibne Mannan, Trainee, Department of Plastic Surgery, Dhaka Medical College Hospital, Bangladesh
4. Dr. Maliha Alam Simi, Medical Officer, Department of Paediatrics, Dhaka Medical College Hospital, Bangladesh.

**Correspondence :** Dr. Tanveer Ahmed, Assistant Registrar, Department of Plastic Surgery, Dhaka Medical College Hospital, Dhaka, Bangladesh. Email: tahimon@gmail.com, Mobile: +8801711320715.



**Fig.-2:** (Steps of operation in sketch): Showing the lipoma over the ventral surface of the penis at its distal part. Penile anaesthetic block application. An elliptical incision was applied with no. 15 blade along the long axis of the penis just around the base of the lipoma. After excision of the lipoma, penile skin was closed with 5-0 Poly Propylene suture. (Sketch by Dr. M.A. Simi)

### Discussion

Lipoma of the penis is a rare entity. To our knowledge, lipoma of penis has never before been reported from Indian subcontinent. Although asymptomatic and of low objective significance they often cause aesthetic and psychogenic problems as well as mechanical sexual dysfunction<sup>4</sup>. Here in the presented case of penile lipoma, it was responsible for sexual dysfunction. The penis comprises three main components, the dorsally situated two corpora cavernosa, and the ventrally lying corpus spongiosum which encloses the urethra. These components are covered by areolar tissues which are all covered by a skin layer. The skin of the penis is thin, darkish in color, and without any fat tissue beneath it. It is loosely connected to the penile shaft, which allows for easy movement over the shaft. This membrane passes backwards at the ventral part of the preputium and creates the frenulum, a longitudinal fold attached to the urethral meatus. Histologically fat cell is absent from all layers of the penis. So the development of penile lipoma is unusual. But the improvement of sexual function after excision justifies surgery which was done not only for functional reasons but for aesthetic as well.

### References

1. Bancroft LW, Kransdorf MJ, Peterson JJ, O'Connor MI. Benign fatty tumors: classification, clinical course, imaging appearance, and treatment. *Skeletal Radiol.* 2006 oct; 35 (10):719–33
2. Fregnani ER, Pires FR Falzoni R, Lopes MA et al. Lipoma of the oral cavity, clinical and histological classification and proliferate activity of 46 cases. *Int J Oral Maxillofac Surg.* 2003; 32:53-5.
3. Lucas RB. Tumours of adipose tissue. Pathology of tumours of adipose tissue. London: *Churchill Livingstone*; 1984:176-9.
4. Perimenis P, Liatsikos E, Athanasopoulos A et al. Penile lipomas, cause of sexual dysfunction. *International Urology and Nephrology.* 2002; 34:3-4.
5. Meraj S, Narasimhan G, Gerber E et al. Bladder wall lipoma. *Urology.* 2002; 60:164x–164xi.
6. Wallace D (December 1976). Lipoma of the corpus callosum. *J Neurol Neurosurg Psychiatry.* 39 (12):1179–85.
7. Chaitin BA, Goldman RL, Linker DG. Angiomyolipoma of penis. *Urology.* 1984; 23:305–306.
8. Khanna S. Epidermoid cyst of the glans penis. *Eur Urol.* 1991; 19:176–177.