

Original Article

Scalp Reconstruction Following High Voltage Electric Burn

HOSSAIN MZ¹, SARKER B², LENIN LK³, HANNA A⁴, DHAR LK⁵

Abstract:

Background: Scalp reconstruction following high voltage electric burn can be challenging. A useful Reconstructive algorithm is lacking. The purpose of this study was to evaluate our experience and to identify an appropriate reconstructive strategy.

Methodology: This was a prospective observational study, conducted in the Burn unit of Dhaka Medical College Hospital & Department of Burn & Plastic Surgery, Sir Salimullah Medical College & Mitford Hospital over a period of five years. Reconstructive procedures, independent factors and outcomes were evaluated.

A total of 7 procedures were performed in 30 patients. Techniques for reconstruction included skin grafting, outer table drilling & skin grafting, Bipedicule flap, Single rotation flap, Double opposing rotation flap, Transposition flap, Tissue expansion & primary closure.

Conclusion: Important tenets for successful management of scalp defects are durable coverage, adequate debridement, preservation of blood supply, and proper wound drainage. Local scalp flaps with skin grafts remain the mainstay of reconstruction in most instances.

Key Words: Electric burn, scalp defect, local flap, reconstruction.

Introduction:

The scalp is unique as structure, shape and location. It is highest point of the body, most exposed and usually uncovered by clothing. These factors make it vulnerable burn injuries specially electric burns. Being exposed, mild degree of scarring is easily noticeable and lead to disfigurement. On the other hand the skin of the scalp lacks laxity and primary closure of wounds greater than 2 cm is often not possible. Anatomically, it is described as an organ based on a rigid, flat aponeurosis and consisting in thick skin, penetrated by hair, nourished by a rich vascular network, situated in the subcutaneous tissue¹. The scalp has a rich vascular supply; the ability to withstand wounds of greater tension than other regions, and often has hair that can camouflage resulting scars or asymmetries. Nevertheless,

most of the scalp is relatively inelastic; repair of even small defect is difficult and is ideally reconstructed with hair-bearing skin. These properties compromise the ease of effective reconstruction and affect the surgeon's ability to reconstruct defects in this area. Therefore the decision-making process behind a successful outcome requires a solid knowledge of anatomy, a clear evaluation of the defect and the knowledge of a variety of reconstruction options available. Multiple reconstructive options exist that includes, primary wound repair, healing by secondary intention, and the use of skin grafts, local tissue flaps, regional myocutaneous flaps, and micro vascular free flaps. While considering reconstructive options the plan must always be tailored to the individual patient's needs and due attention be given to the aesthetic outcome that specially includes preservation of the hairline and hair follicle orientation, scar camouflage, avoidance of alopecia, and secondary restoration of alopecia.^{2,3,4,5}

Tissue expansion is also one of the most important armamentaria for aesthetic scalp reconstruction after burn⁶. Tissue expanders are silicone envelopes that have self-sealing injection ports and at weekly intervals, saline is progressively injected through a remote injection port and it passes into the expander space, which then enlarges thus allows the surgeon to generate additional amounts of precious tissue to replace the defected tissue.

1. Dr. Md. Zakir Hossain, Assistant Professor, Burn and Plastic Surgery, Sir Salimullah Medical College & Mitford Hospital, Dhaka.
2. Dr. Bidhan Sarker, Assistant professor, Plastic Surgery, NITOR.
3. Dr. Lutfar Kader Lenin, Assistant professor, Burn and Plastic Surgery, Dhaka Medical College Hospital.
4. Dr. Ayesha Hanna, Registrar, Burn & Plastic Surgery, Sir Salimullah Medical College & Mitford Hospital, Dhaka.
5. Dr. Limon Kumar Dhar, Medical officer, Burn and Plastic Surgery, Dhaka Medical College Hospital.

Correspondence : Dr. Dr. Md. Zakir Hossain, Assistant professor, Burn and Plastic Surgery, Sir Salimullah Medical College & Mitford Hospital, Dhaka.

However, the application of tissue expanders carries inherent complications such as wound infection, extrusion of the envelope from the implantations site due to unhealed wound margins or flap necrosis, that develop as a result of ischemia following the expansion of the envelope.⁷⁻¹⁰

The objective of our study is to see the outcome of different reconstructive procedures performed in high voltage electric burn injuries involving the scalp.

Material and methods:

This prospective observational study was conducted in the Burn unit of Dhaka Medical College Hospital and Burn & Plastic Surgery Department of Sir Salimullah Medical College & Mitford Hospital from July 2007 to October 2012. During the study period 30 scalp defects were managed. Patients were included in the study after obtaining an informed consent, all the study variables were collected on pre designed pro forma such as age, sex, procedure performed and complications noted. The data was compiled, computed through SPSS 17.

Results:

Among 30 patients; 22 were male and 08 were females, with male to female ratio of 5:1. Most of the patients age ranged from 20-30 years. The mean size of the defects in its longest dimension was 4.50 cm. Bone was exposed in 28 cases. All patients underwent through surgical debridement.

Among 30 patients, 28 patients had injuries to other sites of the body. The Single rotation flap (Figure-1) was the most common procedure performed (26.67%).while Bipedicle flap (Figure-2) was the 2nd commonest procedure performed in this series of patients (Table-I). Scoring of galea required in 05 cases and back cut required in 03 cases to facilitates the repair of scalp. In 03 cases of small defects, wounds were covered by rotation flap without skin grafting to the donor site.

Among the 08 cases of single rotation flap, 05 cases required skin grafting in the donor site. All the cases of Bipedicle flaps, double opposing rotation flaps (Figure-3) and transposition flaps (Figure-4) required skin grafting in the donor area. The tissue expander technique was used in 1 patient.

The postoperative complications (Table-II) seen in this series includes discharging sinus in 2 cases, exposure of bone (Figure-5) in 2 cases, Partial Flap necrosis in 01 case, Partial Graft loss (Figure-6) in 01case and Wound infection in 01 case.

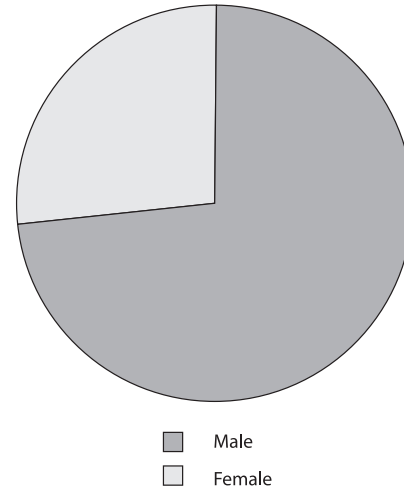


Chart : 01 : Pie chart showing male female ratio

Table-I

Age Incidence of Patients

Age of patients (In years)	No of patients
< 10	01
10-20	03
21-30	14
31-40	10
>40	02

Table-II

Types of Procedures Performed

Type of procedure	No of patients
Skin grafting only	02
Outer table drilling & skin grafting	01
Outer table decortication & skin grafting	02
Single Rotation flap	08
Double opposing rotation flap	04
Bipedicle flap	07
Transposition flap	03
Tissue expansion & primary closure	01
Sequestrum removal with grafting over the dura	02

Table-III

Complications of Surgery

Complications	No of Patients
Discharging sinus	02
Exposure of bone	02
Partial Flap necrosis	01
Partial Graft loss	01
Wound infection	01

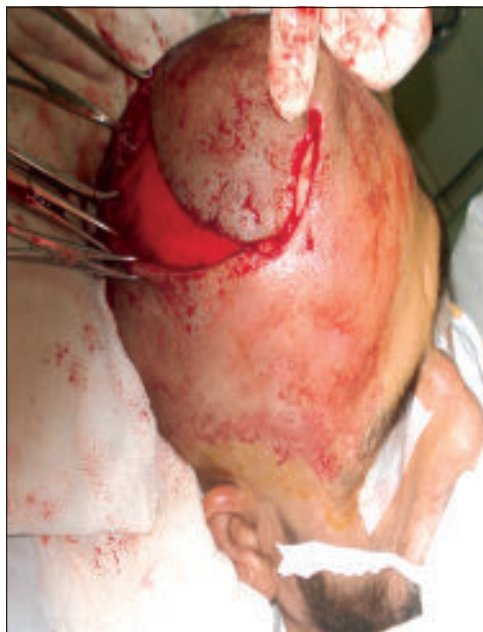

Fig.-1: *Rotation flap*

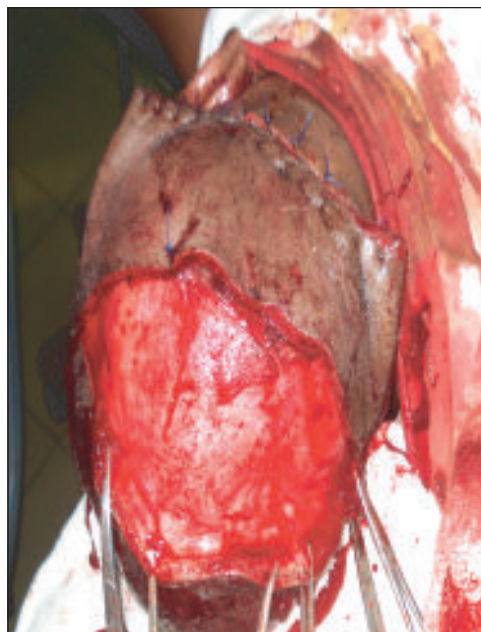


Fig.-2: *Wound is covered by bipedicle flap*

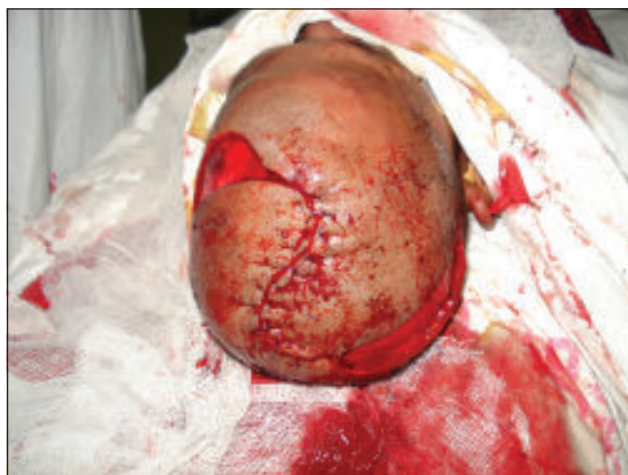

Fig.-3: *Double opposing rotation flap*

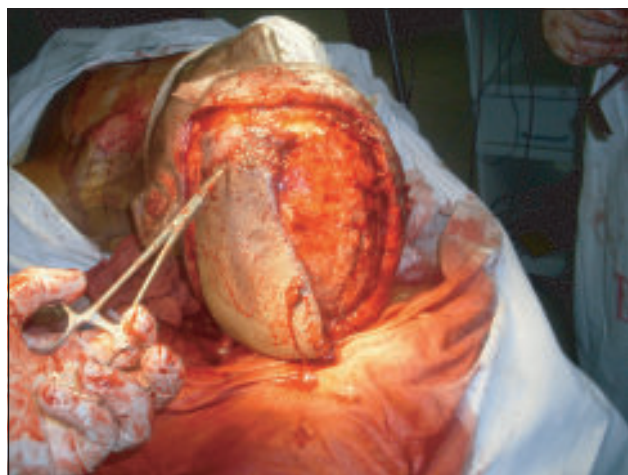


Fig.-4: *Transposition flap*

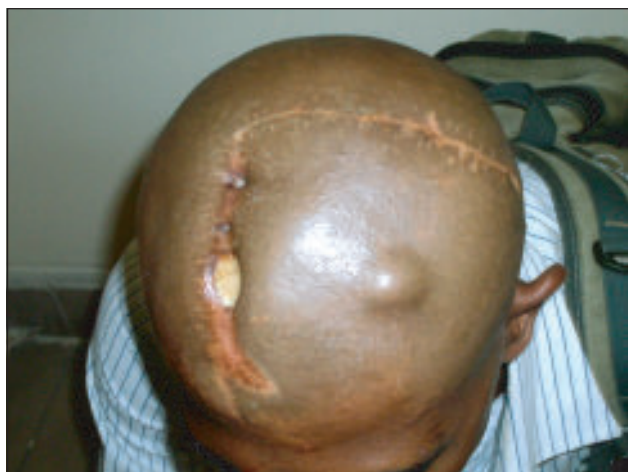

Fig.-5: *Exposure of bone*

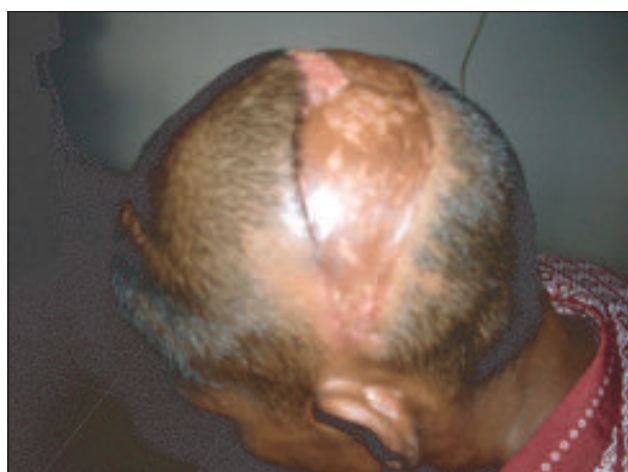

Fig.-6: *Partial skin graft loss*

Discussion:

The management of scalp defects remains a continuous challenge to the reconstructive surgeon worldwide 1, 3.

Most of the patients in our study were males. This reflects the fact that male while performing most of outdoor activities are more prone to electric burn injuries, and females of our society remain at home for domestic affairs are largely protected.

A multi staged surgical approach followed in all the patients. In the initial stage, wound debridement was performed in all the cases. Multiple dressings required before definitive procedure. Tetanus prophylaxis was ensured.

Single rotational flaps were performed in majority (08) of patients. These flaps were raised based on major vessels. The flaps were raised through the sub galeal plane preserving the periosteum. In some patients outer table drilling was performed and it was the case when pericranium was not intact and also the local flap was not possible and outer table drilling then made the bed for graft possible. In case of linear defects, Bipedicule flaps and double opposing rotation flaps were used. In cases of circular defects, rotation flaps were used. In case of very large defect, transposition flaps and /or skin grafting were performed. Tissue expander was used to correct the baldness over the scar developed following electric burn injury. Bone reconstruction was not performed in those cases where dura was covered by skin grafts. In case of outer table decortication & skin grafting, graft was lost partially which was healed by secondary intension. In case of forehead wounds, flaps were selected very carefully avoiding the hair bearing flaps.

The morbidity in all of these cases was not so much, however few of the complications like Discharging sinus, Exposure of bone, Partial Flap necrosis, Partial Graft loss and Wound infection were present. In one case of discharging sinus, cause was presence of sequestrum underneath the flap. The sequestrum was removed and flap re insetted and healed completely. Decortication of dead bone, Re rotation and advancement of flap was done in bone exposure patients. Bone drilling and later skin grafting was performed in flap necrosis. Partial Graft loss wound was healed by secondary intension. Wound infection respond well to the conservative management that includes antiseptic dressings and use of antimicrobial agents but resulting in broad scar.

Similar studies were performed by Abdul Razzak Memon and his associates in Hyderabad 11. In their study of scalp reconstruction, multiple factors were responsible for scalp defects. On the other hand, we considered only the electric burn patients. By their study, Skin grafting alone or in combination with other technique was the most common

procedure for repair of the scalp defects. In our study, Rotation flap was the commonest procedure to cover the scalp defect, and Bi- pedicle flap was the second commonest procedure performed.

In another study, Newman and his colleagues 5 performed scalp reconstruction in 64 patients over 15 years, the defects were caused by multiple factors and the techniques of reconstruction were Primary closure, Skin grafting, local and distal flaps. In our study, we did not performed any distal flap.

Conclusion:

Adequate surgical debridement, meticulous surgical technique and selection of flaps are the mainstay of management. In this study, rotation flap and skin grafting were the preferable forms of reconstruction. Careful analysis of the defect and local tissues can help tailor the method of reconstruction and result in satisfactory closure in a majority of patients.

References:

1. Tamas C, Popa L, Turluc D, Morosanu C, Lazar M. Surgical reconstruction in scalp defects. *Clinics of Plastic and Reconstructive Surgery*. 2005. 1(2); 83-86.
2. Lisa M. Earnest, Patrick J. Byrne. Scalp Reconstruction. *Facial plastic surgery clinics of North America*. May 2005 13(2): 345-353
3. Blackwell KE, Rawnsley JD. Aesthetic considerations in scalp reconstruction. *FPS*. 2008; 24(1):11-21.
4. García del Campo JA, García de Marcos JA, del Castillo Pardo de Vera JL, García de Marcos MJ. Local flap reconstruction of large scalp defects. *Med Oral Patol Oral Cir Bucal*. 2008 Oct 1;13(10):E666-70.
5. Newman MI, Hanasono MM, Disa JJ, Cordeiro PG, Mehrara BJ. Scalp reconstruction: a 15-year experience. *Ann Plast Surg*. 2004 May;52(5):501-6
6. Fan J, Yang P. Aesthetic reconstruction of burn alopecia by using expanded hairbearing scalp flaps. *Aesthetic Plast Surg*. 1997 Nov-Dec;21(6):440-4.
7. Halpern M, Adams C, Ratner D. Galeal hinge flaps: a useful technique for immediate repair of scalp defects extending to periosteum. *Dermatol Surg*. 2009 Jan;35(1):127-30.
8. Pasyk KA, Hassett C. Quantitative analysis of the thickness of human skin and subcutaneous tissue following controlled expansion with silicone implant. *Plast Surg* 1986;92:127.
9. Revis D. Tissue expansion. <http://www.emedicine.com/ent/topic708.htm>. Accessed on August 26, 2010
10. Cunha MS, Nakamoto HA, Herson MR, Faes JC, Gemperli R, Ferreira MC. Tissue expander complication in plastic surgery: A 10 year experience. *Rev Hosp Clin Fac Med* 2002; 57: 93-7.
11. Memon AR, Kumar M, Shaikh BF, Surgical reconstruction of scalp: Medical channel, October-December, 2010; Vol: 16, No. 4: P-578-581.