

# Cardiac Hydatid Cyst: First Ever Documented Case in Bangladesh

Md. Saiful Hoque Talukder<sup>1</sup>, Subash Chandra Mandal<sup>2</sup>, Md. Shafiqul Islam<sup>3</sup>, Md. Monzur Hossain<sup>4</sup>, Md. Mujibur Rahman Rony<sup>5</sup>, Zayin Zawad Khan<sup>5</sup>, Md. Mesbah Uddin<sup>4</sup>, ANM Kibria<sup>6</sup>, Abdur Rahim<sup>7</sup>, Abdul Momen<sup>8</sup>, Md. Wahiduzzaman Bhuyian<sup>9</sup>

### Abstract:

Hydatid cystic disease results from infection with the larval or adult form of the *Echinococcus*

*Granulosus* (tapeworm). Cardiac involvement is seen in 0.5% to 2% of patients with hydatid disease and involvement of the right atrium (RA), main pulmonary artery (MPA) and right pulmonary artery (RPA) are very rare. In this case a 22-yr-old farmer woman from Raigong, Sirajgong, Bangladesh presented to the Shahid Ziaur Rahman Medical College hospital, Bogra with the complaints of breathlessness for 10 months; haemoptysis and chest pain for last 3 months. CT scan of the chest showed cystic lesion on right hilar region with right sided pulmonary inflammatory lesion. CT

guided FNAC revealed benign right bronchogenic cyst. Echocardiography showed right atrial (RA) thrombus. CT angiogram report showed complete occlusion of right pulmonary artery (RPA) with thrombus, main pulmonary artery (MPA) was partially occluded with thrombus & thrombus in right atrium (RA). Under cardiopulmonary bypass, a multiloculated mass was removed from RA and a cyst like structure removed from MPA and RPA. Histopathological report of the biopsy specimen revealed hydatid cyst and presence of *Echinococcus* Ab confirmed the diagnosis of Hydatid disease.

*Keywords:* Hydatid Cyst, Cardiac, Bangladesh

(*Bangladesh Heart Journal* 2017; 32(2) : 125-129)

1. Professor, Dept. of Cardiac Surgery, NICVD, Dhaka, Bangladesh.
2. Associate Professor, Dept. of Cardiac Surgery, NICVD, Dhaka, Bangladesh.
3. Assistant Professor, Dept. of Cardiac Surgery, NICVD, Dhaka, Bangladesh.
4. Assistant Registrar, Dept. of Cardiac Surgery, NICVD, Dhaka, Bangladesh.
5. MS Resident, Dept. of Cardiac Surgery, NICVD, Dhaka, Bangladesh.
6. Associate Professor, Dept. of Thoracic Surgery, NIDCH, Dhaka, Bangladesh.
7. Assistant Professor, Dept. of Thoracic Surgery, NIDCH, Dhaka, Bangladesh.
8. Associate Professor, Dept. of Cardiology, NICVD, Dhaka, Bangladesh.
9. Associate Professor, Dept. of Radiology & Imaging, NICVD, Dhaka, Bangladesh.

**Address of Correspondence:** Md. Saiful Hoque Talukder, Professor, Department of Cardiac Surgery, National Institute of Cardiovascular Diseases, Dhaka, Bangladesh. Phone: +8801711285452, Email: saiful.talukder@yahoo.com

### Introduction

Hydatid disease is a zoonotic parasitic infection caused mainly by *Echinococcus granulosus* & other subtypes. Dogs, cats & foxes are primary carriers of this parasite. Cattle, goat, sheep & human can be infected as intermediary carriers when eat unwashed or uncooked vegetables or swallows the eggs of parasite. Embryo of the parasite inserts into the circulation from intestine and can involve every organ<sup>1,2,3</sup>.

This infection commonly involves liver through portal vein, but if embryos bypass liver, they reach the lungs via the inferior vena cava. They can also involve other organs like heart<sup>2</sup>.

The frequency of cardiac involvement is less than 2%<sup>4,5</sup>. Intracardiac tumours, congenital cysts and aneurysms are in differential diagnosis of this lesion<sup>6,7</sup>. Left ventricle is the most common site of cardiac involvement<sup>1</sup>. But rarer in right side of the heart. Solitary cardiac cyst may remain

asymptomatic for a long periods, or can be discovered after serious and even fatal conditions. Rupture remains the major life threatening complication and may result in anaphylactic shock. Cardiac tamponade, systemic or pulmonary embolism, chest pain, valvular regurgitation, and in exceptional cases arrhythmias can reveal hydatid cysts.

The diagnosis of cardiac hydatid disease is based on the combination of clinical suspicion, serologic tests and cardiac imaging. Echocardiography is highly sensitive and specific tool for the diagnosis of hydatid cysts<sup>8</sup> and positive serological tests can help the diagnosis of this disease.

Here we introduce a rare 1<sup>st</sup> ever documented case of hydatid cyst with cardiac involvement in Bangladesh and discuss the important points about the disease.

### Case presentation

Mrs. Basona, a 22-yr-old farmer, non diabetic & normotensive woman from Raigong, Sirajgong, Bangladesh was presented to the Shahid Ziaur Rahman medical college hospital, Bogra with the complaints of progressive exertional dyspnea for 10 months, hemoptysis and chest pain for last 3 months. Her symptoms were deteriorated day by day. She had no history of pulmonary TB. She had history of taking oral contraceptive for 8 years. She had only one child of 8 months of age. Her family and social history were negative. She was referred to National Institute of Diseases of the Chest and Hospital (NIDCH) for better management. After complete evaluation in NIDCH she was diagnosed as a case of Right bronchogenic cyst with thrombus in the Right Atrium (RA), Main Pulmonary Artery (MPA) and Right Pulmonary Artery (RPA). Main pulmonary artery & right pulmonary artery are partially & totally occluded respectively by thrombi. Then she was referred to National Institute of Cardiovascular Diseases (NICVD) for better management.

On general examination, all the vital signs were within normal limits. On cardiac and respiratory system examination, only there was diminished breath sound in right side with no added sounds & murmur. Other systemic examination revealed no abnormality. In laboratory tests, Complete hemogram, Serum Electrolytes, RBS, CRP were within normal limits. Chest X ray showed right hilar rounded dense opacity (fig.1). Electrocardiogram showed no ischaemic change and revealed sinus tachycardia. Echocardiography showed right atrial (RA) & IVC thrombus, moderate PAH (PASP- 47mm Hg) with good LV systolic function.

CT scan of the chest showed cystic lesion on right hilar region with right sided pulmonary inflammatory lesion. CT guided FNAC revealed benign right bronchogenic cyst. CT Pulmonary angiogram report showed thrombi in the Right Atrium (RA), Main Pulmonary Artery (MPA) and Right Pulmonary Artery (RPA) and oligemic right lung with

consolidation in the hilar region of the right lung (Fig: 2,3,4). Main pulmonary artery & right pulmonary artery were partially & totally occluded respectively by thrombi. Ultrasonography of whole abdomen was normal.

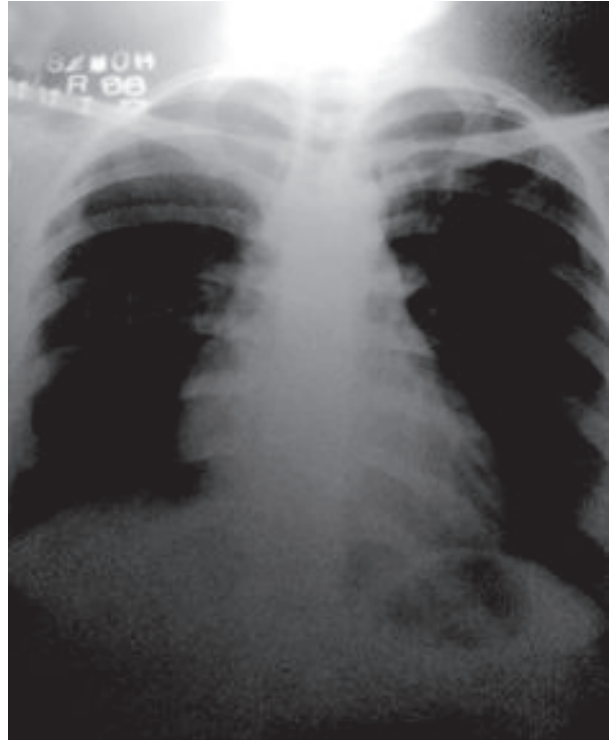


Fig.-1: Chest X-ray before operation showing Right hilar mass (red arrow mark).

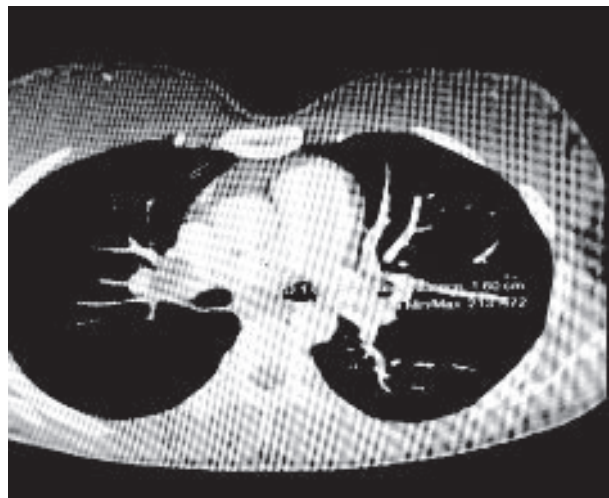
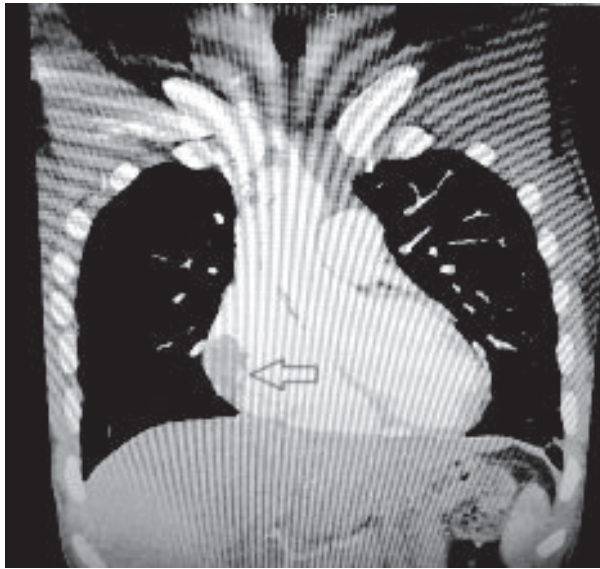
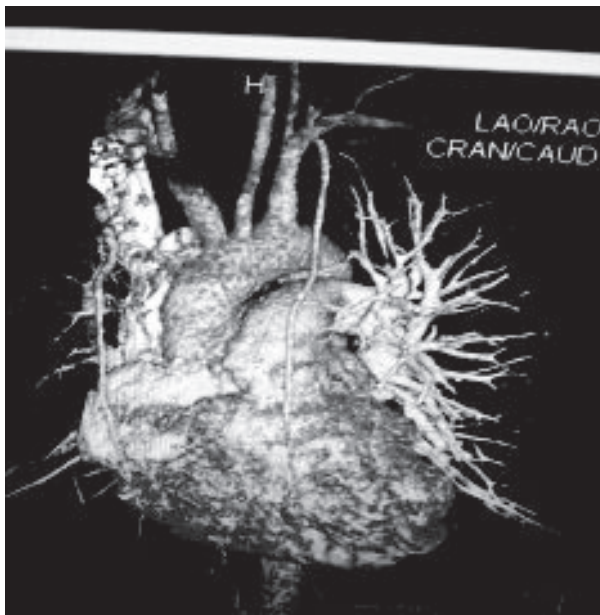


Fig.-2: CT pulmonary Angiogram showing filling defect is seen in the right hilum with evidence of complete occlusion of RPA & partial occlusion of MPA.



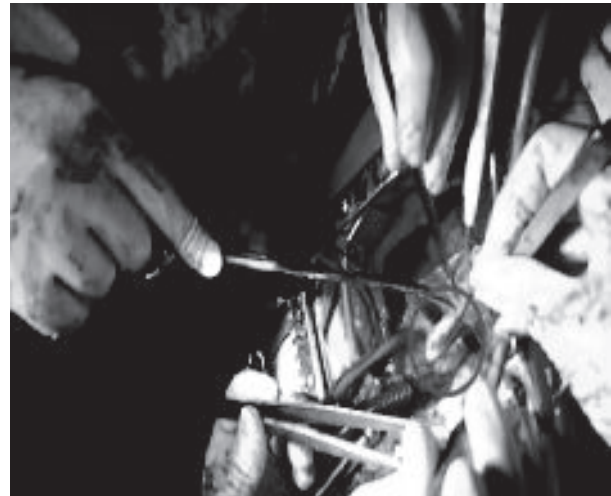**Fig.-3:** CT pulmonary Angiogram showing filling defect in contrast filled right atrium (Left arrow mark).



**Fig.-4:** VRT (Volume Rendering Image) showing vascular tree of the heart and great vessels.

The patient was operated on urgent basis. Under general anesthesia midline sternotomy was done. The operation was performed by establishing Cardiopulmonary bypass (CPB) and arresting the heart with cold blood-antegrade cardioplegia. Per operatively, a mass was seen in the right atrium and its right wall was found adherent to adjacent pericardium and mediastinal pleura. Then, right

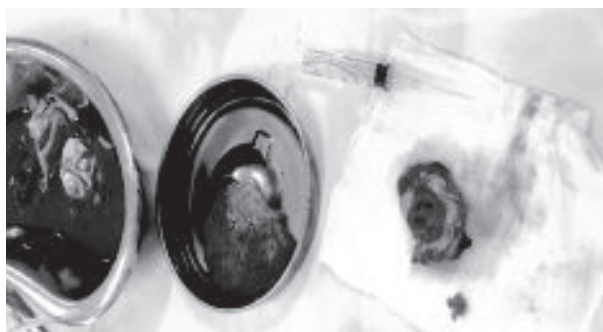atriotomy was done. After opening the right atrium, a mass was found which looked like amultiloculated ruptured cyst. Then suspicion of hydatid cyst arose. After that hypertonic saline soaked gauze & mops are used for prevention of spillage & anaphylactic shock. The mass invaded the pericardium & adjacent pleura. It was excised along with adjacent unhealthy atrial wall and adherent pericardium & pleura (Fig: 5).



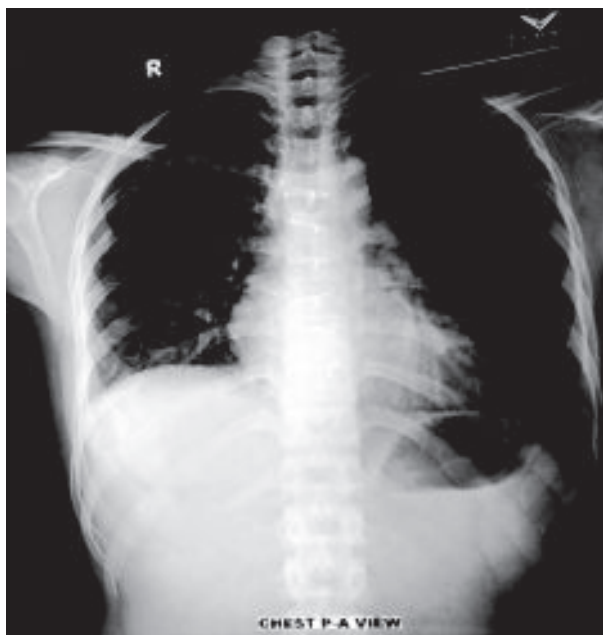
**Fig 5:** Operative photo clip showing excision of right atrial cystic mass. (Red Circle).

The MPA was opened & a smooth surfaced mass protruding into it through the RPA was found. A considerable part of RPA between aorta & SVC was incised open. A smooth surfaced tubular structure was found to occupy whole of the RPA, the right end of which could not be negotiated. The structure was cut open & a clear fluid within it was sucked out. The structure was double layered with outer opaque thick layer & inner white thin layer. After further suction & manipulation, the cystic part of the structure extending into the right upper lobe branch of RPA along with MPA totally came out. Then the cystic mass occupying the hilar region of right lung disappeared. The specimen was collected in a kidney dish (Fig: 6). Excised right atrial wall was reconstructed with pericardial patch and different atriotomy wounds were repaired accordingly. Patient was weaned from CPB smoothly. The specimen was sent for histopathology and histopathological diagnosis was hydatid cyst. The diagnosis was confirmed by positive Echinococcus

Ab test in blood. The post-operative course was uneventful. Repeat chest X-ray was done on 10<sup>th</sup> postoperative day and no radiopaque shadow was found in the right hilar region (Fig: 7). The patient was discharged on 12<sup>th</sup> postoperative day and prescribed with Albendazole for 3 months. The patient was also advised for periodic follow up.



**Fig.-6:** Excised tissue from RA, MPA & RPA.



**Fig.-7:** Normal chest X-ray after operation  
(Note: Hilar mass is absent after operation)

### Discussion

Echinococcosis was firstly described in the works of Hippocrates in the 4th century AD. The overall incidence of Echinococcus infection is 0.4 per 100,000 persons. Humans are an accidental intermediary host. Its symptom depends on the size and site of infestation. Hydatid cysts are commonly found in the liver (50%–70% of cases), lungs (5%–30%), muscles (5%), bones (3%), kidneys (2%), spleen (1%) and brain (1%)<sup>1,2</sup>. Isolated cardiac involvement is rare and occurs in only 0.02-2% of cases<sup>5</sup>. It is reported from nearly all geographic areas of Bangladesh but cardiac hydatid cysts are not yet reported.

The growth of hydatid cyst is usually slow and asymptomatic<sup>3,6</sup> and discovered coincidentally at postmortem or when an ultrasound or CT scan is done for

some other condition<sup>3</sup>. Just about 10% of patients with cardiac hydatid cyst are symptomatic<sup>6</sup>. Involvement of the heart can occur from the systemic or pulmonary circulation or as a direct extension from adjacent structures. The coronary circulation is the main pathway by which the parasitic larvae reach the heart<sup>7</sup>. Because of rich coronary blood supply, the left ventricle is the site of cardiac hydatid cysts in 55% to 60% of cases. Less frequently involved are the right ventricle (10%–15%), pericardium (7%), pulmonary artery (6%–7%), left atrium (6%–8%), right atrium (3%–4%), and interventricular septum (4%)<sup>1,8,9,10,11</sup>. Initially, the cyst grows slowly between the cardiac fibers and causes no sign or symptom. Later it may cause pericardial pain, dyspnoea, invade the surrounding structure, obstruct the blood flow and also invade the conductive system of heart and cause cardiac arrhythmia or block<sup>6,12</sup>. Some cases can mimic acute coronary syndrome<sup>13</sup>. Our case presented with the complaints of progressive exertional dyspnea, hemoptysis and chest pain.

In most of the cases, patient developed tachycardia or ventricular arrhythmias<sup>1,14</sup>. Our case presented with sinus tachycardia. Although the serologic reactions for hydatid cyst provide essential information, their sensitivity is not high and parameters frequently do not correspond to the morphological changes of the disease<sup>14</sup>. Chest radiographs usually show a normal cardiothoracic ratio<sup>14</sup>.

Echocardiography findings vary according to the sites of the cysts<sup>8</sup>. Echocardiography is the simple and useful diagnostic tool of cardiac hydatid cysts<sup>8</sup>. Most of the cases revealed as intra-myocardial tumour on Echocardiography<sup>1,12</sup>. But our report revealed as thrombus burden in the LA, MPA & RPA.

Computed tomography and MRI provide further information, such as the extent and anatomic relationships of the cysts<sup>1,5</sup>. The presence of calcification in cystic lesion in echocardiography and MRI can be helpful to distinguish it from other cardiac cystic lesions<sup>6,15</sup>. Other helpful findings in MRI are presence of daughter cysts, and membrane detachment<sup>1</sup>.

Cardiac surgery is the treatment of choice for most cases of cardiac hydatid cyst; however, the technique of surgery can be different<sup>13,14</sup>. The clinical presentation is usually insidious but there is always the lethal hazard of cyst perforation. Early diagnosis and an integrated treatment strategy are crucial. The results of surgical treatment of heart echinococcosis are better than the conservative strategy. Extraction of the cyst combined with chemotherapy in both peri and post operative aiming to decrease the recurrences, consists the Lejeune method of encountering this medical entity<sup>14</sup>. Inoperable patients require long-term therapy with Albendazole. The most important major complication is the

rupture of the cyst, which can trigger an anaphylactic shock or tamponade, systemic or pulmonary embolization and compression of coronary branches<sup>14</sup>. Scolicidal solutions such as iodine, ethanol, methylene blue or hypertonic saline can be used to reduce the risk of leakage of fluid from cyst during cardiac surgery<sup>15</sup>. In our patient, despite previous rupture of the hydatid cyst into the right atrium, there was no life-threatening complication such as anaphylactic reaction due to leakage of cystic fluid into the blood stream occurred. Albendazole therapy (400 mg twice daily) is typically prescribed for at least 4 days preoperatively and for 4 to 12 weeks postoperatively<sup>10,14,15</sup>.

### Conclusion

This is the 1<sup>st</sup> & only diagnosed and operated cardiac hydatid cyst case in Bangladesh. In this patient, Cardiac MRI was not done due to financial constrain. Early diagnosis and surgico-medical treatment is the mainstay of treatment for cardiac hydatid disease. In endemic areas, hydatid cyst should be considered in differential diagnosis of heterogeneous echogenic lesions on even if the serologic tests are negative.

### Ethical considerations

Ethical issues (Including plagiarism, informed consent, misconduct, data fabrication and/or falsification, double publication and/or submission, redundancy, etc.) have been completely observed by the authors.

### Acknowledgements

The authors declare that there is no conflict of interests.

### References

1. Elhadj IZ, Boukhris M, Kammoun I, Halima AB, Addad F, Kachboura S. Cardiac hydatid cyst revealed by ventricular tachycardia. *J Saudi Heart Assoc.* 2008; 26(1): 47-50.
2. Chatterjee K.D. Phylum Platyhelminthes: class Cestoidea. *Parasitology, Protozoology and helminthology*: 12th ed. Calcutta .1980; 121-27.
3. Williams NS, Bulstrode CJK, O'Connell PR. *Surgery in the tropics.* Bailey & Love's Short Practice of Surgery: 25th ed. London. 2008; 56-59.
4. Tekbas EO, Tekbas G, Atilgan ZA, Islamoglu Y, Cil H, Yazici M. Left ventricle hydatid cyst mimicking acute

- coronary syndrome. *Journal Infect Dev Ctries.* 2012; 6(7): 579-83.
5. Khosravi A, Taghipour H, Fanaei SA, Assar O, Ghyasy MS, Mirlohi SM. Heart hydatid cyst close to the left descending artery in a thirteen-year-old boy. *Iran Red Crescent Med J.* 2014; 16(9): e15164.
6. Yildiz CE, Sinan UY, Yildiz A, Cetin G, Kucukoglu S. A Case of Isolated Cardiac Hydatid Cyst that Mimics Lymphoproliferative Malignancy. *Echocardiography.* 2015; 32(6): 1036-39.
7. Canpolat U, Yorgun H, Sunman H, Aytemir K. Cardiac hydatid cyst mimicking left ventricular aneurysm and diagnosed by magnetic resonance imaging. *Turk Kardiyol Dern Ars.* 2011; 39 (1): 47-51.
8. Ohri S, Sachdeva A, Bhatia M, Shrivastava S. Cardiac hydatid cyst in left ventricular free wall. *Echo Res Pract.* 2015; 2 (1): K17-K19.
9. Ugurlucan M, Sayin OA, Surmen B, Cinar T, Yekeler E, Dursun M. Images in cardiovascular medicine. Hydatid cyst of the interventricular septum. *Circulation.* 2006; 113:e869-e870.
10. Poorzand H, Teshnizi MA, Baghini VS, Gifani M, Gholoobi A, Zirak N. Giant cardiac hydatid cyst with rare adhesions. *Sweden H. Assoc J.* 2008; 62(5): 341-4.
11. Bhatia M, Sunman H, Yildiz A. Cardiac hydatid cyst, a rare case. *Hellenic J Cardiol.* 2009; 55(3): 260-64.
12. Abtahi F, Mahmood Y. Myocardial Hydatid Cyst: An Uncommon Complication of Echinococcal Infection. *Int Cardiovasc Res J.* 2010; 2(1): 58-61.
13. Ceviz M, Becit N, Kocak H. Infected cardiac hydatid cyst. *Heart.* 2001; 86(5): E13.
14. Tsigkas G, Chouchoulis K, Apostolakis E, Kalogeropoulou C, Koutsogiannis N, Koumoundourou D. Heart echinococcus cyst as an incidental finding: early detection might be lifesaving. *J Cardiothorac Surg.* 2015; 5:124.
15. Tabesh H, Ahmadi T H, Ameri S. Unusual Presentation of Interventricular Hydatid Cyst: A Case Report. *Iran J Public Health.* 2015; 44(1): 130-33.