

## Carotid body Tumour with Hypoglossal Nerve Palsy- A Case Report

Kaisar Haroon<sup>1</sup>, Tania Taher<sup>2</sup>, Shafiqul Alam<sup>3</sup>, Naila Huq<sup>4</sup>, Sk. Sader Hossain<sup>5</sup>

---

### Abstract:

**Objective:** Carotid body tumour is a rare tumour. This is a case report of carotid body tumour of the right side involving the right hypoglossal nerve with MRI appearance and pathological features. The objective is to present a case of Hypoglossal nerve palsy due to carotid body tumour involving the right carotid artery bifurcation.

**Method:** A 18-year old male presented with a well-defined swelling of his right neck, increasing hoarseness, and left ward tongue deviation on protrusion present for two years CT neck and MRI were

done. The tumour was identified and the patient underwent surgery. His Histopathology report commented it to be carotid body tumour.

**Result:** The patient showed significant improvement after surgery. His tongue deviation improved and his hoarseness of voice had been begun to improve.

**Conclusion:** Carotid body tumours are benign lesion mimicking other pathology. High level of suspicion, imaging and careful resection is important for avoiding complications.

*Keywords:* Carotid body tumour, chemodectoma, hypoglossal nerve palsy, schwannoma, deviation of tongue

---

(Bangladesh Heart Journal 2019; 34(1): 68-72)

### Introduction:

Carotid body tumor (CBT) is a rare lesion of the neuroendocrine system. The carotid body was first anatomically described by Albrecht Von Haller in 1743<sup>1</sup>. Carotid body tumors, with an incidence of less than 0.5% of all tumors, are rare neoplasms arising from the paraganglion cells of the carotid body<sup>2</sup>. Carotid body tumors (CBT) are a rare entity that should be considered in evaluating every lateral neck mass<sup>3</sup>. Carotid chemodectomas or carotid body tumors are rare neoplasms, generally benign, slow-growing and frequently asymptomatic<sup>4</sup>. Hallett reported 153 carotid body tumours between 1935 and 1985, a span of fifty years<sup>5</sup>.

The carotid body is located on the posterior aspect of the carotid bifurcation. These paired, reddish-brown, ellipsoid structures are approximately 3 × 5 × 1.5 mm, with an average weight of 12 mg.<sup>2</sup> They usually present in the neck, anterior to the sternocleidomastoid muscle at the level of the hyoid bone, near the carotid bifurcation and can be pulsatile due to their juxtaposition with the carotid artery.<sup>4</sup> The carotid body originates from mesoblastic and neural components. The neural components are derived from neural crest ectoderm as sympathogonia, which further differentiate into sympathoblasts or chromaffinoblasts<sup>6</sup>.

### Incidence:

Between 1949 and 1985 there were 84 patients. Of the 64 patients with a skull base tumor, 46 were female and 18 male<sup>7</sup>. Twenty patients with carotid body tumors treated in our institution over a period of 50 years, 1941-1991<sup>8</sup>. William's review comprises 33 tumors in 30 patients treated surgically from 1956 through 1990 at two private teaching hospitals in Denver<sup>9</sup>. Patetsio had

- 
1. Assistant Professor, Dept of Neurosurgery, NINSH
  2. Assistant Professor, Dept of Paediatrics, HFRC Medical College Hospital
  3. Associate Professor, Dept of Neurosurgery, NINSH
  4. Associate Professor, Dept of Neuropathology, NINSH
  5. Professor, Dept of Neurosurgery, NINSH

**Address of Correspondence:** : Dr. Kaisar Haroon, Assistant Professor, Department of Neurosurgery, NINS. Email: kaisar298@gmail.com, Phone :01711196577

---

DOI: <https://doi.org/10.3329/bhj.v34i1.41910>

Copyright © 2017 Bangladesh Cardiac Society. Published by Bangladesh Cardiac Society. This is an Open Access articles published under the Creative Commons Attribution-NonCommercial 4.0 International License (CC BY-NC). This license permits use, distribution and reproduction in any medium, provided the original work is properly cited and is not used for commercial purposes.

treated thirty-four tumors in 29 patients between 1971 and 2001. There were 10 men and 19 women<sup>10</sup>. In Patet's series, in the group of 41 patients twenty-four of the patients were women and 17 were men. There was an equal incidence of involvement of the right and left carotid bodies; two patients had bilateral tumors.<sup>11</sup>

Wang stated between 1973 and 1998. Twenty-nine patients with 36 carotid body tumors were identified. There were 16 men and 13 women. The age of patients varied from 10 to 78 years. There were 22 right-sided tumors and 14 left sided tumors. Seven patients had bilateral tumors. 3 patients had CN X deficits, and 2 patients had CN XII deficits<sup>2</sup>. Kraus reported, from June 1979 through June 1987, 15 patients were treated for carotid body tumors at the Cleveland (Ohio) Clinic Foundation. Resection and ligation of the internal carotid artery were required in one case<sup>12</sup>.

In 1971, Shamblin introduced a classification system based on tumors size. They classified small tumors that could be easily dissected away from the vessels as group I. Group II (7 of their cases) included paragangliomas of medium size that were intimately associated and compressed carotid vessels, but could be separated with careful subadventitial dissection. Group III consisted of (5 of their cases) tumors that were large and typically encased the carotid artery requiring partial or complete vessel resection and replacement<sup>13</sup>.

#### Report of the Case:

A 18-year old male presented with a well-defined swelling of his right neck, increasing hoarseness, and leftward tongue deviation on protrusion present for two years. He complained of difficulty in eating and deglutition for six months. He had no history of prolonged fever or night sweats. On physical examination there was a right lateral neck mass, extending from the superior aspect of the sternocleidomastoid muscle to the angle of the mandible with concomitant right tongue hemiatrophy and impairment of lingual mobility (Fig. 1). The lesion was firm to hard, non-tender and mobile horizontally but not cephalocaudally. It was not attached to the underlying tissue. There was a transmitted impulse from the tumour. Neurological examination revealed hypoglossal nerve palsy with fasciculation and wasting of right side of the tongue and deviation to the left on protrusion. The function of the cervical sympathetic chain was intact. No palpable cervical lymph nodes were present. The patient's past medical history was unremarkable. His fiberoptic laryngoscopy revealed that his rt. vocal cord was fixed.

Computed tomography (CT) scan with contrast showed a well-defined 4.9x3.5 cm mass, located between the internal carotid artery and the external carotid artery splaying the bifurcation and compressing the internal

jugular vein (Fig. 1). Intravenous injection of contrast medium also demonstrated the tumour to be vascular.

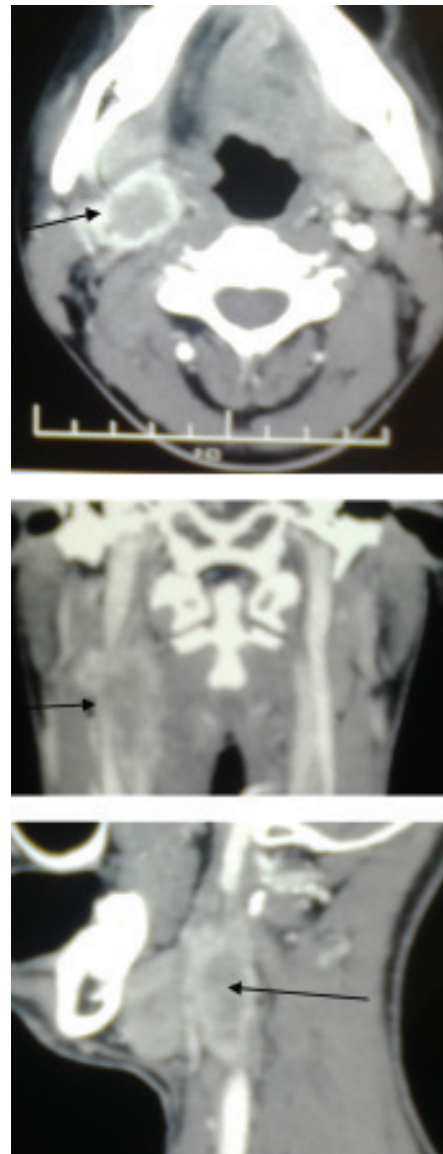
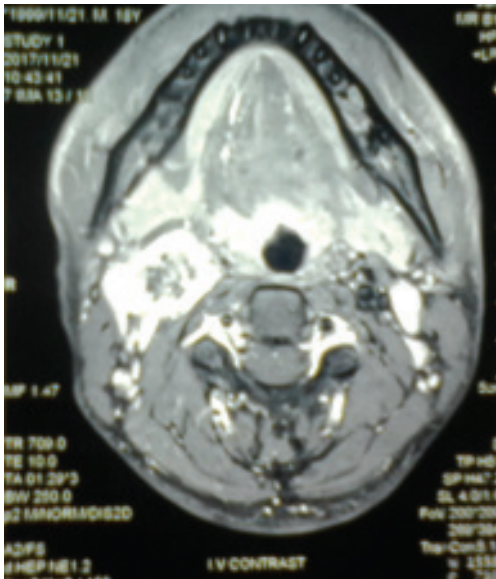

Fig.-1: CT Scan:: Contrast CT scan

Magnetic resonance imaging (MRI) scan revealed a contrast enhancing mass within the right carotid canal extending from the angle of the mandible to the carotid bifurcation (Fig. 2). Fine needle aspiration cytology (FNAC) was performed. CT guided FNAC, there was atypical tumour cell in lymphoid background. They had commented that it was suspicious of neurogenic tumour.

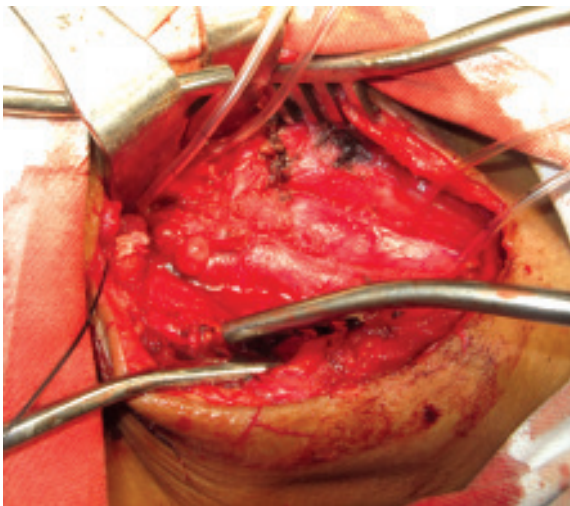
At the time of the operation, it was determined that the tumour was located around the bifurcation, the vagus



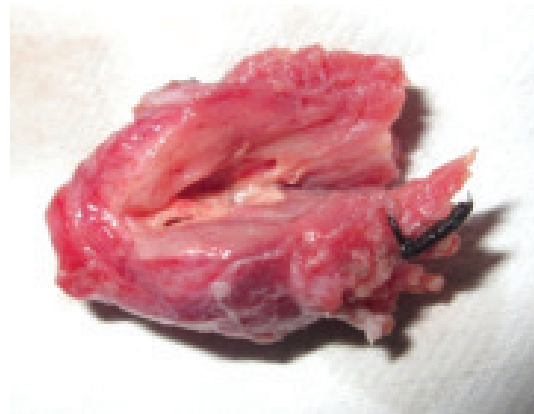**Fig.-2: MRI with Contrast axial**

nerve was intact. The lesion was densely adherent to the carotid arteries and the internal jugular vein was compressed. The right hypoglossal nerve was severely adherent to the tumour. Adequate vascular control was taken around the tumour. The mass was encapsulated and could be resected enbloc since the vagus nerve was not coursing through the tumour but was passing under the tumour capsule. There was no flow through the arteries after the control was released. So, the tumour, along with the involved vessel was resected.

On gross examination, (Fig 3 & 4) the tumors were well-circumscribed and may had a pseudocapsule. The cut surface was typically solid with a smooth, rubbery texture but had displayed some areas of hemorrhage.



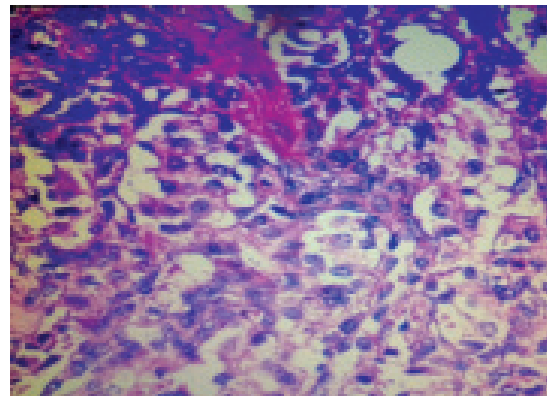
**Fig.-3: Intraoperative view:**



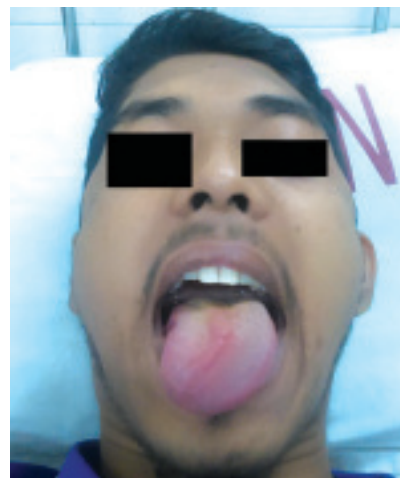**Fig.-4: Tumour: The excised tumour**

**Histopathological Exam: (Fig 5)**

Microscopic sections of the carotid tumor contained lobules of glomic tissue, comprised of multiple clustered nests of chief cells surrounded by a thin rim of sustentacular cells embedded in a collagenous reticular stromas.

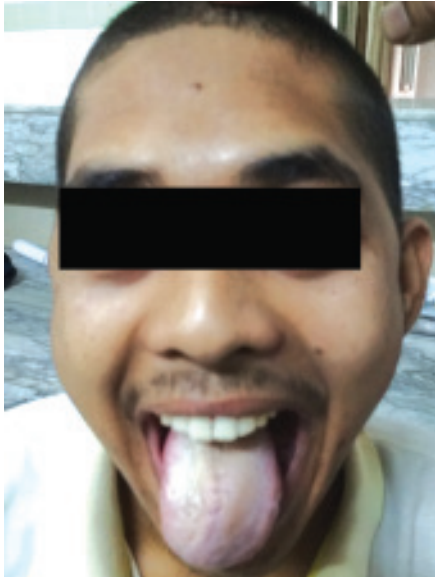

**Fig.-5: Histopathology: H&E preparation**



**Fig 6: Preop**

Patient's postoperative course was uneventful and 1 month later the mobility of the tongue was improved. His voice was not back to normal, but hoarseness had diminished. His difficulty in deglutition had improved.



**Fig.-7:** Post op

#### **Discussions:**

In a series of Leonetti, all 16 patients underwent complete tumor removal. No patients suffered a stroke or major postoperative hemorrhage<sup>14</sup>. Sanghvi has advocated Radiotherapy postoperatively in cases in which tumor is left behind, especially in tumors extending to the base of the skull<sup>6</sup>.

Luna Ortiz reviewed 69 CBT cases in 66 patients. Age ranged from 18 to 94 years (mean = 50.2 years). Thirty-six (54%) patients lived at an altitude higher than 2200 m above sea level. Forty-six (70%) patients were subjected to surgery, 7 (10.6%) to radiotherapy, 1 (1.5%) to surgery followed by radiotherapy, and 13 (19.6%) did not accept any treatment at all. From the 47 surgeries, 44 (93.6%) corresponded to subadventitial resections, and the other three (6.3%) patients required vascular reconstruction. One patient (2%) was also subjected to hemithyroidectomy due to a papillary carcinoma found at the time of paraganglioma resection.<sup>15</sup>

Kenneth described post-operative complications like vascular Injury, baroreflex failure and Cranial Nerve Injury<sup>16</sup>. Andersons series of the thirteen definitive cases, one patient had ligation of the carotid artery prior to excision of the tumor<sup>17</sup>. This is what was followed in our case.

In Bernard's series between 1973 and 1984, five patients underwent excision of a carotid body tumor without operative mortality, cranial nerve palsy, cerebrovascular accident, or recurrence<sup>18</sup>. In our patient no new deficit had occurred.

Surgical management is still the only curative treatment, but carotid body tumor resection remains a surgical challenge and is associated in more than 15% of cases with cranial nerve injuries, with a high risk of vascular complications<sup>19</sup>.

#### **Conclusion:**

Carotid body tumor is an infrequently diagnosed but curable lesion if resected without metastatic or residual disease.<sup>10</sup>. Early surgical treatment is recommended in almost all patients after preoperative evaluation and detection of multifocal tumors. Surgical excision of small tumors was safe and without complication, but resection of Shamblin 3 tumors can be challenging.

#### **References:**

1. Knight TT, Gonzalez JA, Rary JM, et al. Current concepts for the surgical management of carotid body tumor. *The American Journal of Surgery* 2006;191(1):104-10.
2. Wang SJ, Wang MB, Barauskas TM, et al. Surgical Management of Carotid Body Tumors. *Otolaryngology-Head and Neck Surgery* 2000;123(3):202-06.
3. McIlrath DC, ReMine WH. Carotid-Body Tumors. *Surgical Clinics of North America* 1963;43(4): 1135-44.
4. Rallis G, Mourouzis K, Maltezos C, et al. Hemiatrophy of the tongue caused by an extensive vagus nerve schwannoma masquerading as a carotid chemodectoma. *Journal of maxillofacial and oral surgery* 2015;14(1):366-69.
5. Hallett JW, Nora JD, Hollier LH, et al. Trends in neurovascular complications of surgical management for carotid body and cervical paraganglionmas: A fifty-year experience with 153 tumors. *Journal of vascular surgery* 1988;7(2):284-91.
6. McGuirt W, Harker LA. Carotid body tumors. *Archives of Otolaryngology* 1975;101(1):58-62.
7. Powell S, Peters N, Harmer C. Chemodectoma of the head and neck: results of treatment in 84 patients. *International Journal of Radiation Oncology\* Biology\* Physics* 1992;22(5):919-24.

8. Sanghvi VD, Chandawarkar RY. Carotid body tumors. *Journal of Surgical Oncology* 1993;54(3):190-92.
9. Williams MD, Phillips MJ, Nelson WR, et al. Carotid body tumor. *Archives of Surgery* 1992;127(8):963-68.
10. Patetsios P, Gable DR, Garrett WV, et al. Management of Carotid Body Paragangliomas and Review of a 30-year Experience. *Annals of Vascular Surgery* 2002;16(3):331-38.
11. Pettet JR, Woolner LB, Judd Jr ES. Carotid body tumors (chemodectomas). *Annals of surgery* 1953;137(4):465.
12. Kraus DH, Sterman BM, Hakaim AG, et al. Carotid body tumors. *Archives of Otolaryngology-Head & Neck Surgery* 1990;116(12):1384-87.
13. Davidovic LB, Djukic VB, Vasic DM, et al. Diagnosis and treatment of carotid body paraganglioma: 21 years of experience at a clinical center of Serbia. *World Journal of Surgical Oncology* 2005;3(1):10.
14. Leonetti DJP, Donzelli DJJ, Littooy DFN, et al. Perioperative strategies in the management of carotid body tumors. *Otolaryngology-Head and Neck Surgery* 1997;117(1):111-15.
15. Luna-Ortiz K, Rascon-Ortiz M, Villavicencio-Valencia V, et al. Carotid body tumors: review of a 20-year experience. *Oral Oncology* 2005;41(1):56-61.
16. Hu K, Persky MS. Treatment of head and neck paragangliomas. *Cancer Control* 2016;23(3)
17. Anderson R, Scarcella JV. Carotid body tumors. *The American Journal of Surgery* 1963;106(5):856-59.
18. Bernard RP. Carotid body tumors. *The American Journal of Surgery* 1992;163(5):494-96.
19. Makeieff M, Raingard I, Alric P, et al. Surgical management of carotid body tumors. *Annals of surgical oncology* 2008;15(8):2180-86.