

Thoracic Endovascular Aortic Repair (TEVAR): A Case Report

G.M. Mokbul Hossain¹, AHM Bashar², Mohammad Enamul Hakim³, Md. Fidah Hossain⁴, Nirmal Kanti Dey⁵, Abdullah Al Mamun⁶, Swadesh Ranjan Sarker⁷, Ashfaq Arif⁸, Naresh Chandra Mandal⁹

Abstract:

Thoracic aortic aneurysm (TAA) is generally a disease of the elderly which remains mostly asymptomatic. It is often detected incidentally with imaging studies of the chest done for other reasons. We present a 55-year-old smoker, normotensive and non-diabetic male patient who was diagnosed as a case of TAA and treated by endovascular means with thoracic endovascular aortic repair (TEVAR) technique. Due to small caliber femoral artery, thoracic endograft was deployed through a

Dacron graft conduit of 10 mm diameter which was anastomosed to the common iliac artery. It was a hybrid procedure done in cardiac catheterization laboratory under general anesthesia. Completion angiogram revealed good technical success with no endoleak or neurological deficit. Patient improved symptomatically after TEVAR.

Keywords: Aortic; Endovascular; Dacron graft

(Bangladesh Heart Journal 2019; 34(2): 146-150)

Introduction:

Aortic diseases, including aortic aneurysms, are the 12th leading cause of death in the United States.¹ Although aneurysm of the abdominal aorta (AAA) and ascending aorta are more common, those of the descending thoracic aorta (TAA) and thoracoabdominal aorta (TAAA) are not rare. TAA and TAAA have an estimated incidence of 5.9 cases per 100,000 person-years.² A study by Clouse and others suggests that the incidence is increasing.³ During the last 5 years, the mortality for non-ruptured and ruptured TAAs in the US population aged 55 years and above ranges from only 0.1 to 2.8 and 0.2 to 3.2 per 100,000, respectively. Surgical repair of TAA is associated with a high morbidity and mortality.

Aortic aneurysm is an emerging vascular problem in our country. In the recent years, there has been an increasing trend in the detection of aortic aneurysm cases because of sophisticated investigation tools like CT Scan, MRI etc. Most aortic aneurysms are asymptomatic. These

are often incidentally detected during plain X-ray chest, abdominal ultrasonogram, CT scan or MRI.

Case:

Mr. X aged about 55 years who was a smoker, normotensive and non-diabetic presented with low thoracic back pain. CT scan of the chest identified a large saccular aneurysm in the descending thoracic aorta at the level of 10th – 11th thoracic vertebra. Diameter of the sac was about 6.6 mm. Endovascular treatment was planned and thin-slice contrast CT scan with reconstruction was performed for precise measurements and customization of the endograft.

Procedure:

A hybrid approach was planned for this case with arrangements for surgical procedure in the cathlab. This was necessary because the right common femoral artery was of narrow caliber with a diameter of only 6mm which would not accommodate a large vascular access sheath for the deployment of the 22F compatible Thoracic endograft.

Department of Vascular Surgery, National Institute of Cardiovascular Disease (NICVD), Dhaka.

Address of Correspondence:

DOI: <https://doi.org/10.3329/bhj.v34i2.44447>

Copyright © 2017 Bangladesh Cardiac Society. Published by Bangladesh Cardiac Society. This is an Open Access article published under the Creative Commons Attribution-NonCommercial 4.0 International License (CC BY-NC). This license permits use, distribution and reproduction in any medium, provided the original work is properly cited and is not used for commercial purposes.

Steps:

1. Under general anesthesia, retroperitoneal laparotomy was done in right lower abdomen and control of right common iliac artery (CIA) was taken.
2. Percutaneous vascular access through left common femoral and left brachial artery.
3. Dacron tube graft of 10 mm diameter was anastomosed to CIA.
4. Descending thoracic aortogram was done through left femoral artery using marker pigtail catheter.
5. Marker pigtail catheter confirmed location with length of lesion as well as the proximal and distal landing zone.
6. After removing the marker pigtail catheter, an angled tip diagnostic wire was introduced in the coeliac trunk through left femoral approach.
7. A 22F access sheath was introduced through the Dacron graft in the right CIA.
8. Thoracic endograft (Valiant Captiva, Medtronic, USA) was introduced through the 22F access sheath and positioned across the TAA against the proximal and distal landing zones.

9. Once the position of the prosthesis was confirmed, it was deployed slowly excluding the sac.
10. Post dilatation was done using compliant balloon (Reliant, Medtronic, USA).
11. Completion angiogram revealed good visualization of the endograft and obliteration of sac and absence of any endoleakage.
12. Dacron tube graft was ligated and divided just distal to anastomosis with right CIA.
13. Laparotomy was closed in layers.
14. Patient was extubated.

Hardware used:

- Thoracic endograft (26 mm×100mm, Valiant Captiva, Medtronic, USA)
- Lunderquist stiff wire (.035"×260cm, Cook, USA)
- Marker pigtail catheter
- Vascular access sheath (22F)
- Compliant balloon
- Straight Dacron graft (10mm)

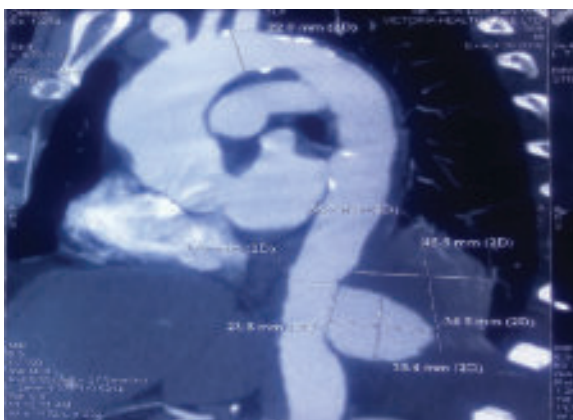


Fig.-1: CT Angiogram

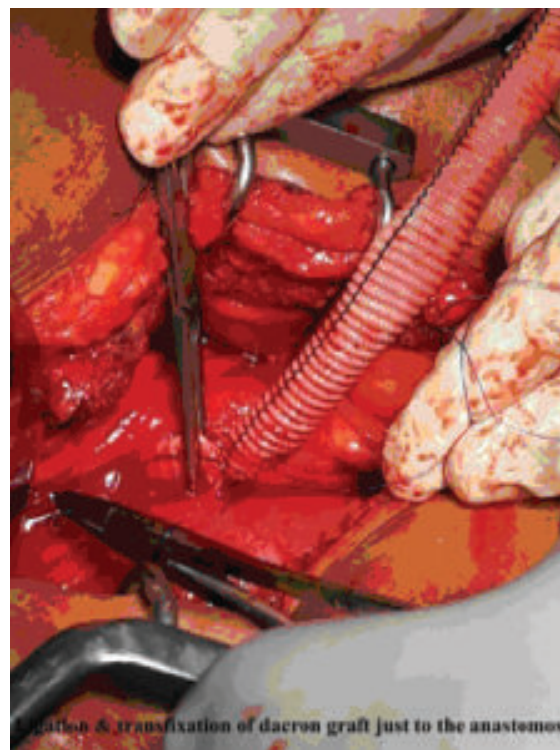


Fig.-2: Retroperitoneal Laparotomy

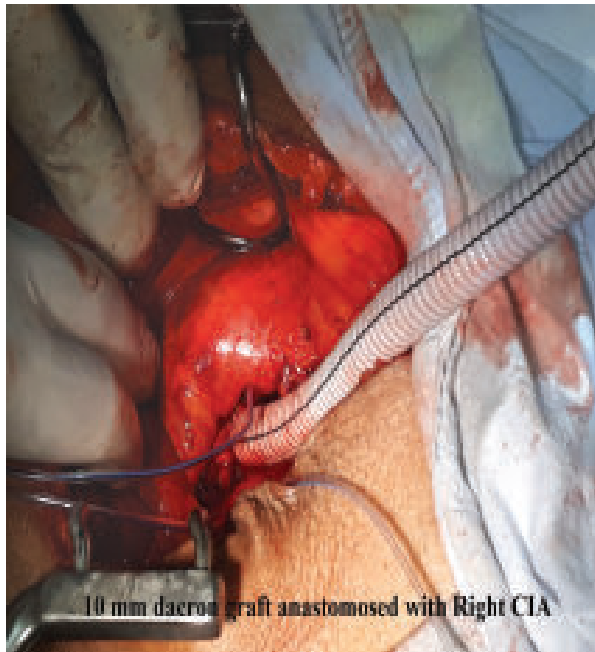

Fig.-3: 10 mm dacron graft anastomosed with right CIA

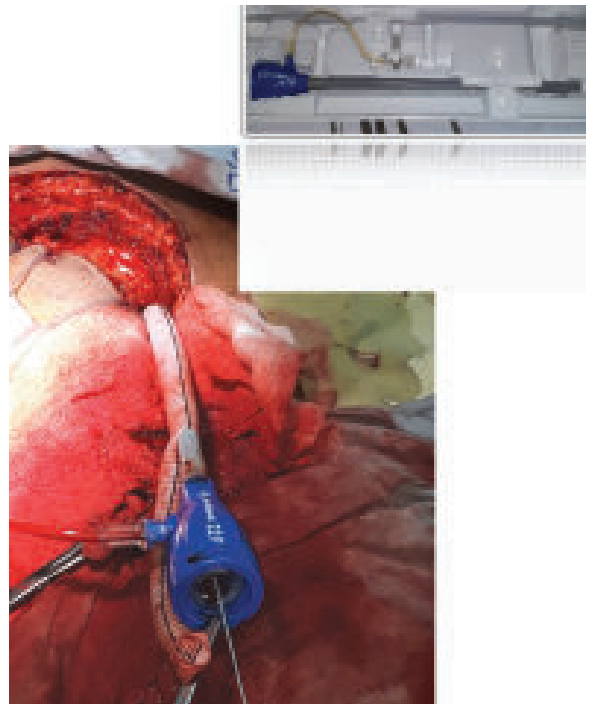


Fig.-4: Retroperitoneal Laparotomy

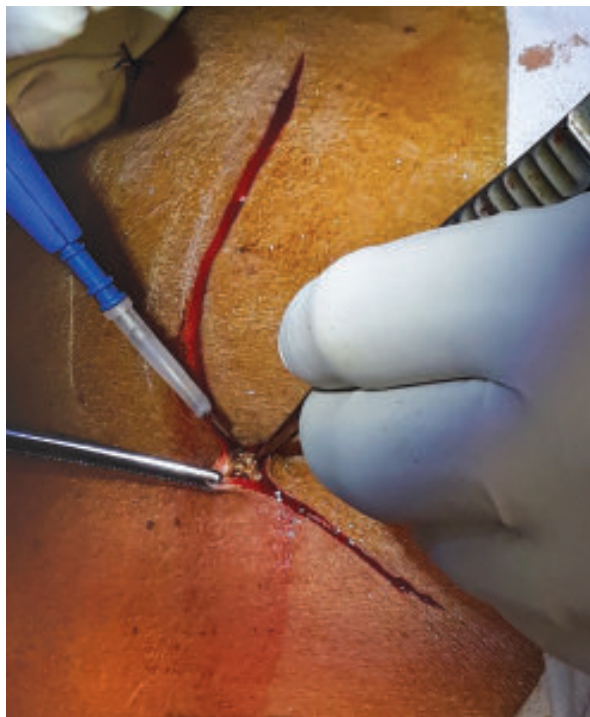

Fig.-5: Ligation and transfixation of dacron graft just distal to the anastomosis

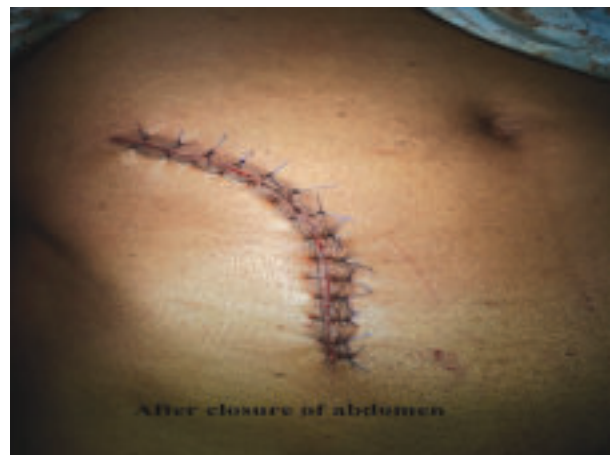

Fig.-6: Closure of abdomen

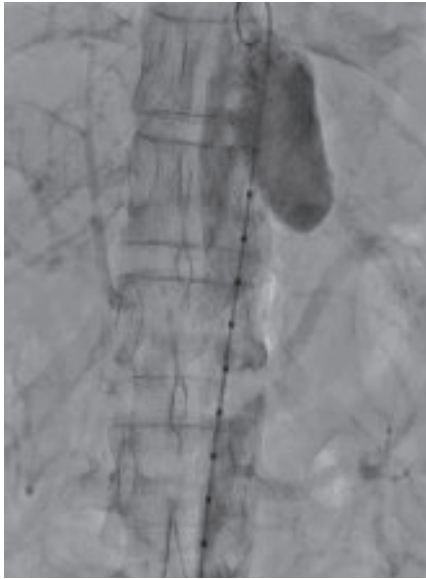

Fig.-7: Before Procedure

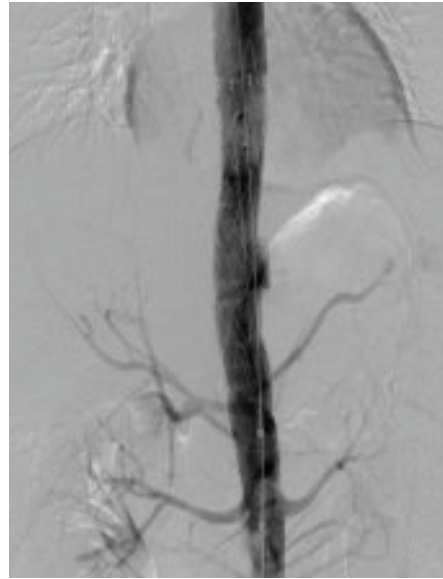

Fig.-8: After Procedure

Discussion:

Endovascular procedure is a less invasive and cosmetic alternative to open surgical treatment. It requires little or no incision and hospital stay is short. On the other hand, open repair requires large thoracotomy which subjects the patient to significant surgical trauma. Therefore, in elderly patients, TEVAR has virtually replaced open surgery in the treatment of TAA. Open surgery is considered in younger patients with longer life expectancy and low surgical risk. TEVAR is indicated when aneurysm diameter exceeds 5 cm, has a saccular morphology, when the patient is symptomatic irrespective of size of the aneurysm and when the aneurysm expands rapidly.

Endovascular aneurysm repair is different from angioplasty for stenosis or occlusion of artery. Precise measurement of the lesion using CT angiogram with 1mm axial cut is mandatory to customize the endograft and thereby prevent complications like endoleakage and migration which may result from undersizing of the device. At least 2 cm proximal & 2cm distal landing zone is needed for proper fixation of endograft. Post dilatation is always with compliant balloon. Aortic angulation more than 60° is a contraindication for TEVAR.

US Food and Drug administration pivotal trial revealed 98% technical success for TEVAR which means delivery of the endograft to the intended location with satisfactory exclusion of the aneurysm and no type I or II endoleaks. Recent trials report a 30-day mortality of 1% to 2% in case of TEVAR which is significantly less than 7%

mortality for open surgical repair.^{4, 5} Complications of TEVAR, like those of all endovascular procedures, can be divided into a general category common to all operative interventions and a procedure-specific category. General complications are not well detailed, and the FDA trials focused on combined trial-specific safety endpoints, which made individual complication rates difficult to determine. At any rate the incidence of major or serious adverse events strongly favors TEVAR over open repair in the three regulatory trials that compared similar metrics. As expected in a population with advanced age and atherosclerotic disease, cardiopulmonary complications dominated the early morbidity, although frequency and severity were less than open repair.^{6,7} For example, the STARZ trial reported a cardiovascular complication rate of 15.6% (TEVAR) and 44.3% (open repair) with an identical incidence of pulmonary complications (15.6% vs. 44.3%).⁶ The incidence of major or serious adverse events and other secondary measures, such as blood loss and hospital stay, were strongly in favor of TEVAR.

A procedure-specific complication of TEVAR is spinal cord ischemia (SCI) resulting in paraplegia, the incidence of which ranges between 2-10%⁸. Unfortunately, SCI detection protocol like somato-sensory and motor evoked potential monitoring and cord protection measures such as spinal fluid drainage, hypothermia, blood pressure management etc. have not been able to significantly reduce the incidence of this complication. Studies are on-going to better understand and prevent TEVAR associated SCI and paraplegia.

Reference:

1. Underlying Cause of Death 1999-2014 on CDC WONDER Online Database, released 2015. Data are from Multiple Cause of Death Files, 1999-2014, as compiled from data provided by the 57 vital statistics jurisdictions through the Vital Statistics Cooperative Program. At: <http://wonder.cdc.gov/ucd-icd10.html>. Accessed May 5, 2016.
2. Bickerstaff LK, Pairolero PC, Hollier LH, Melton LJ, Van Peenen HJ, Cherry KJ. Thoracic aortic aneurysms: a population-based study. *Atherosclerosis*. 1982;15:29.
3. Clouse WD, Hallett JW Jr, Schaff HV, Gayari MM, Ilstrup DM, Melton LJ III. Improved prognosis of thoracic aortic aneurysms: a population-based study. *JAMA*. 1998;280:1926–1929.
4. Jordan WD. Results of a prospective multicenter trial of CTAG thoracic endograft. *J Vasc Surg*. 2015;61:589–595.
5. Illig KA. One-year outcomes from the international multicenter study of the Zenith Alpha Thoracic endovascular graft for
6. Matsumura JS, Cambria RP, Dake MD, et al. International controlled clinical trial of thoracic endovascular aneurysm repair with the Zenith TX2 endovascular graft: 1-year results. *J Vasc Surg*. 2008;47:247–257.
7. Bavaria JE, Appoo JJ, Makaroun MS, et al. Endovascular stent grafting versus open surgical repair of descending thoracic aortic aneurysms in low-risk patients: a multicenter comparative trial. *J Thorac Cardiovasc Surg*. 2007;133:369–377.
8. Etz DC, Luehr M, Aspern KV, et al. Spinal cord ischemia in open and endovascular thoracoabdominal aortic aneurysm repair: new concepts. *The Journal of cardiovascular surgery*. 2014;55:159–68.