

Aneurysm of Left Atrial Appendage: Report of two repaired cases

Sharifuzzaman M¹, Azad MAK², Prodip.K.Biswas³, Momen, A⁴, Choudhury NAH⁵, Shahreen K⁶, Biswas A⁷, Sarmin S⁶

Abstract:

Left atrial appendage aneurysm is a rare heart defect; Most often diagnosed incidentally but may be potentially hazardous when presented with a systemic embolization or arrhythmia. So early diagnosis and treatment is indicated. We have successfully operated

two cases of left atrial aneurysm in recent past and sharing our experiences through this case reports.

Key words: Left atrium (LA), Left atrial appendage (LAA), aneurysm, embolization.

(Bangladesh Heart Journal 2021; 36(2): 158-163)

Introduction:

Left Atrial Appendage aneurysm (LAAA) is a very uncommon anomaly, where there is out pouching of LAA, either diffuse or localize. It is also named as heart's 'Fifth Chamber'¹, or 'Third Ventricle'². Although controversy exists on what constitutes a true LAAA, there is universal consensus on its treatment plan. It can present at any age, even detected in fetuses^{3,4} and have wide range of presentation, from absolutely asymptomatic to palpitation^{5,6}, heart failure⁷, embolism^{8,9,10}, mitral regurgitation¹¹, even chronic hiccups¹². Surgical excision offer best treatment¹³

Here we discuss two cases, presented over a two year period, and treated with surgical excision with expected outcome.

First Case:

This was an 18 years old female, presented with a month long history of palpitation and chest pain. She was in

functional class I. Physical examination revealed her pulse rate of 90 bpm and a BP of 100 over 50 mmHg. Thyroid was of normal size.

ECG showed normal sinus rate of 100bpm. A Chest X-ray showed cardiomegaly of LV type and a CT ratio of 0.65. Other lab investigation findings were normal including thyroid function test.

Transthoracic echocardiography showed a giant cavity communicating with LA. It measured 60x90 mm. The neck of the sac was about 20mm. There was no echo contrast noted within the cavity. Left ventricle was of normal size with intact function. left atrium was not dilated. Visceral pericardium was intact and rest of the study was normal.

She was taken to surgery and procedure performed through right sub-mammary incision and femoral

-
1. Professor, Cardiac Surgery, National Heart Foundation Hospital & Research Institute.
 2. Assistant professor Pediatric Cardiac Surgery, National Heart Foundation Hospital & Research Institute
 3. Registrar, Cardiac Surgery, National Heart Foundation Hospital & Research Institute.
 4. Associate professor, Cardiology, National Institute of Cardio-Vascular Disease. Dhaka
 5. Assistant professor pediatric cardiology National Heart Foundation Hospital & Research Institute.
 6. Registrar, pediatric cardiology, National Heart Foundation Hospital & Research Institute.
 7. Assistant professor, Sher-E-Bangla Medical College Hospital ,Barisal.
- Address of Correspondence: Dr. M.Sharifuzzaman, Professor, Pediatric Cardiac Surgery, National Heart Foundation Hospital & Research Institute, 26/4 Darus Salam Road, Mirpur- 1, Dhaka-1216, Bangladesh. Mobile –01819264022, email-msharifuzzaman@gmail.com

DOI: <https://doi.org/10.3329/bhj.v36i2.56043>

Copyright © 2017 Bangladesh Cardiac Society. Published by Bangladesh Cardiac Society. This is an Open Access articles published under the Creative Commons Attribution-NonCommercial 4.0 International License (CC BY-NC). This license permits use, distribution and reproduction in any medium, provided the original work is properly cited and is not used for commercial purposes.

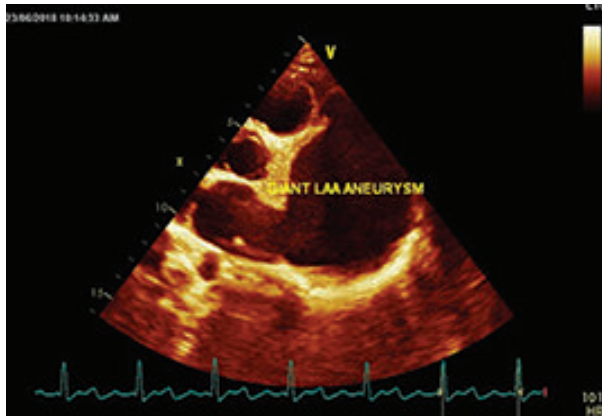


Fig.-1: Giant aneurysm of LAA

cannulations for arterial return and inferior vena caval drainage. SVC cannula was drained through separate incision. Aneurysmal sac was clearly seen through this incision. After cardioplegic arrest and classical LA opening and pathology identified from within the LA cavity. Mitral valve was found competent. There were no thrombus and aneurysmal cavity was obliterated plication from inside and left atrial appendage orifice was separated with a piece of glutaraldehyde treated pericardium. LA closed and rest of the procedure completed uneventfully. Post-operative course was smooth and echo showed absence of LA aneurysm and good LV function and no pericardial effusion. There was sinus rhythm in ECG. Her follow up at 3 months and 1 year showed normal ECG, CXR, Echo and no symptoms.

Second Case:

This was 13 kg; 5 years old male referred to our hospital for evaluation of palpitation and suspected LAAA. He was otherwise a playful young child with moderate growth

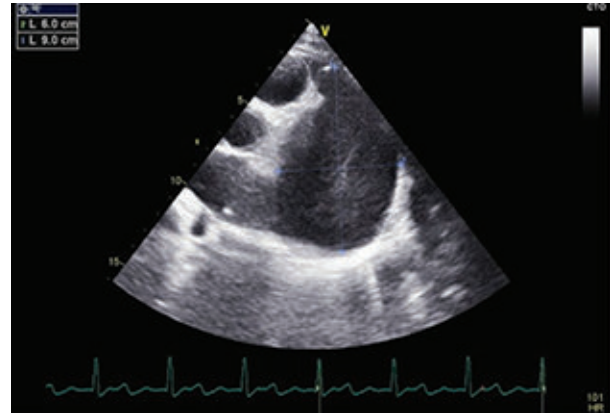


Fig.-2: Large sac measuring 90mmX60mm.

failure. Physical examination revealed a pulse rate of 100, BP of 89/70mmHg, dynamic precordium and an apical holosystolic murmur. Thyroid was not enlarged. Other clinical findings were unremarkable. ECG showed mostly normal sinus rhythm intervened by occasional atrial fibrillation

Chest X-Ray revealed a shadow flanking with LV border, encroaching on the left lung field with a CT ratio over 0.65. Enlarged Left atrium can be determined by identifying double right sided shadow. There was prominence of hilar pulmonary vasculature too.

Echo revealed giant LA aneurysm with spontaneous echo contrast and hugely dilated LA. The Sac was connected through a wide neck. There was moderate Mitral regurgitation due to dilated annulus with prolapsed of AML. The LV was significantly dilated with good biventricular systolic function and moderate diastolic dysfunction. The PA pressure was normal. Other findings were unremarkable.

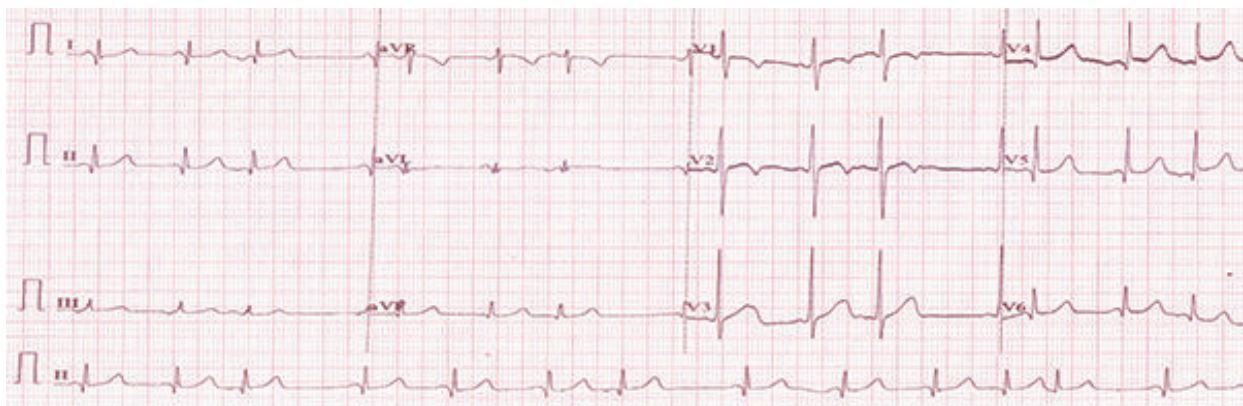


Fig.-3: Atrial fibrillation

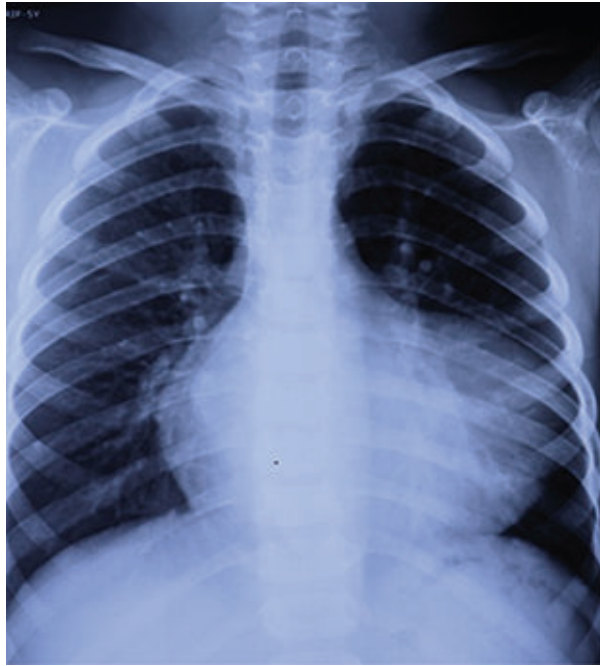

Fig.-4: CXR. Double right border

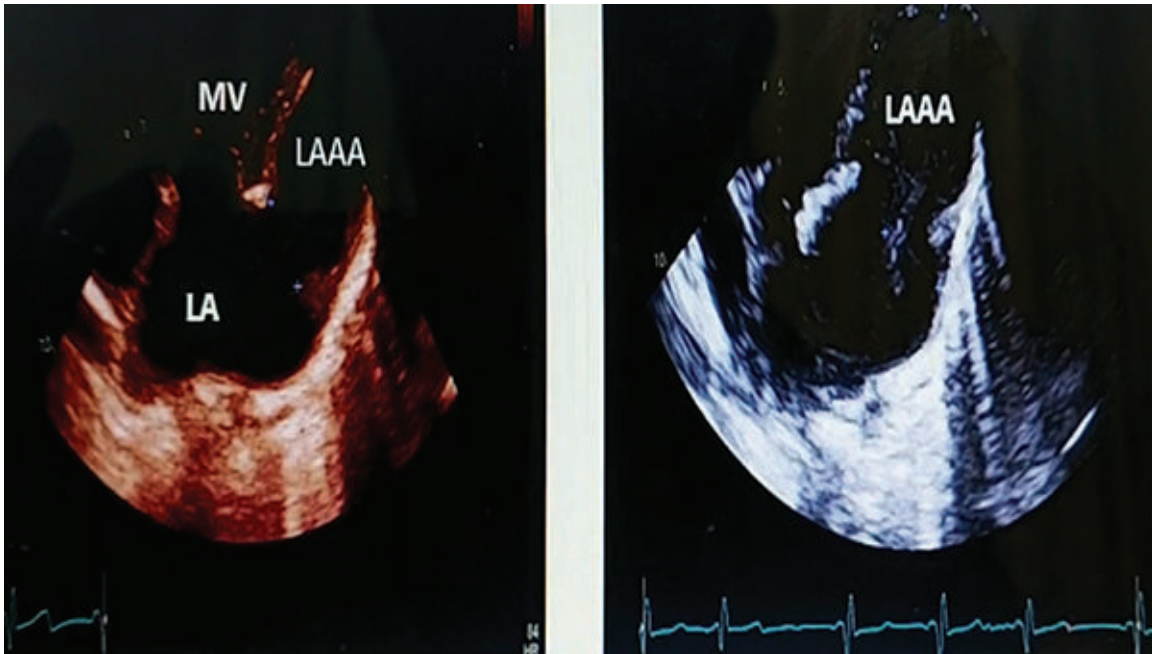


Fig.-5: Echo revealed Sac parallel to LV with large neck with LA.

Contrast CT revealed hugely dilated left atrium with one big aneurysm in the left atrial appendage with thrombus formation (65.3mmX35.9mmX45mm). Left atrium was hugely dilated. The sac was lying parallel and on the left side of left ventricle, Coronary arteries pursued a normal course.

Surgical excision was planned through median sternotomy and on CPB. At operation large aneurysmal sac was noted lying parallel to LV and was lying free of any adhesion to surrounding structure.

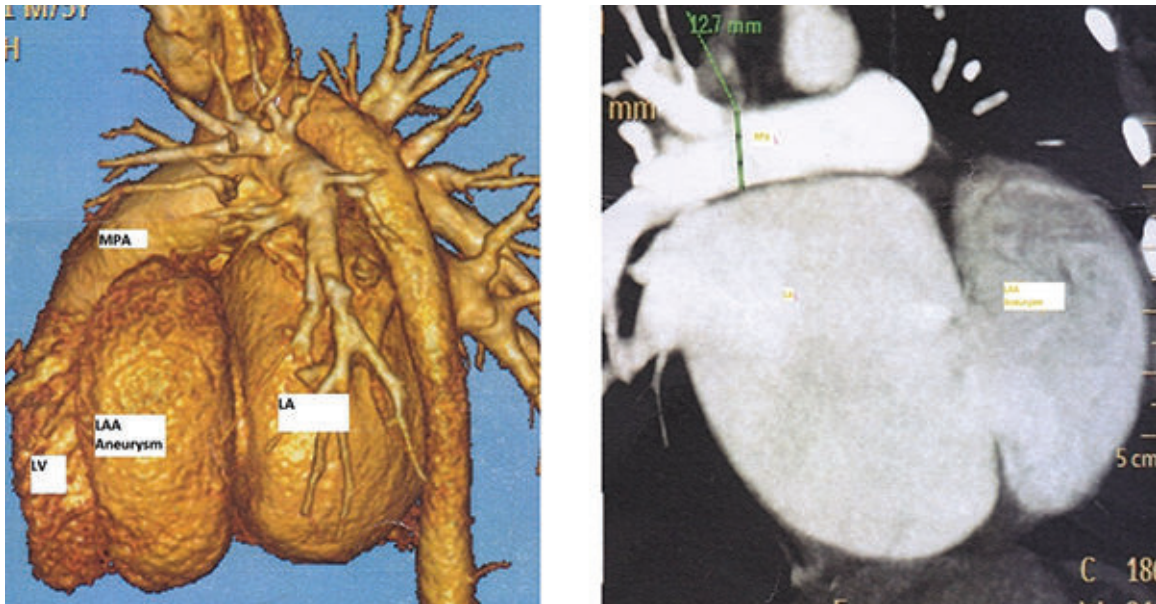


Fig.-6: Dilated left atrium appendage aneurysm

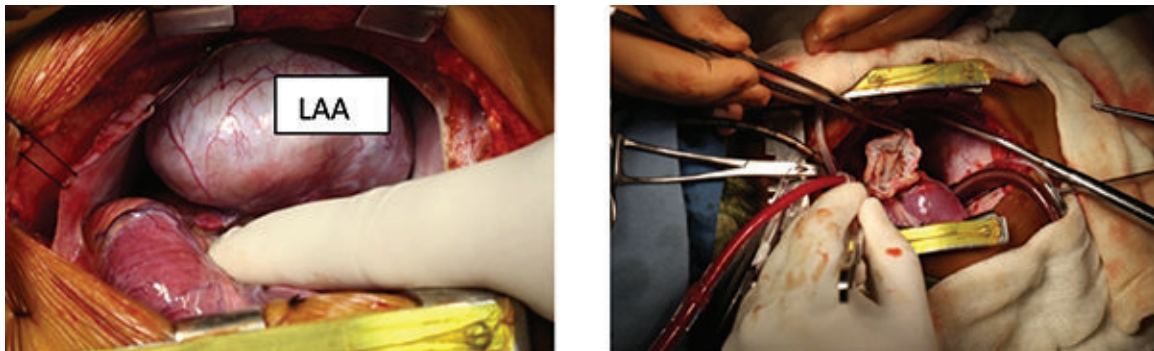


Fig.-7: Per operative findings

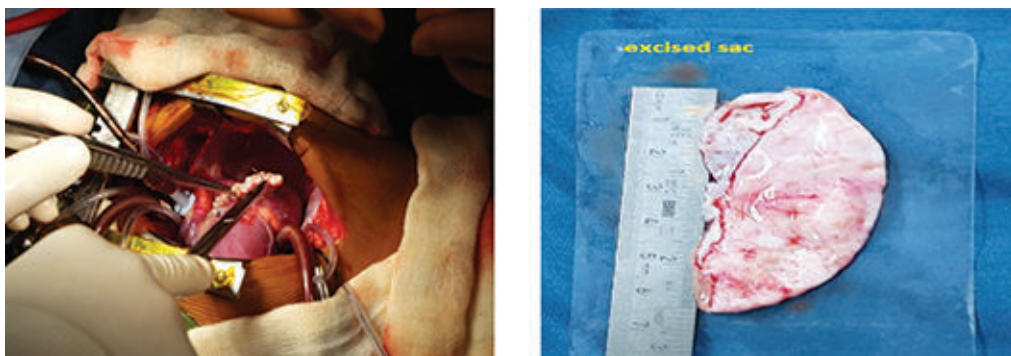

Fig.-8: Surgical resection of aneurysmal sac

Aortic and bi-caval cannulation was performed for Cardiopulmonary bypass. The procedure was performed on an arrested heart. We were able to put a large clamp at the neck of the sac and excise it. Later the large neck was roofed with a pericardial patch. Next, the LA was entered through classical incision. There were signs of jet lesion on posterior LA wall with thinning of its wall, but no thrombus was noted. Mitral valve was found leaking and annulus dilated, which was repaired and electrocautery MAZE procedure was done to electrically isolate the atriums, rest of the procedure was uneventful. LA size was surgically reduced.

Discussion:

Although it is a rare entity, number of reported cases are increasing. So far over 100 cases have been reported in the literature¹⁴. The exact definition of true LAA aneurysm are divergent¹⁵. In literature¹⁶, a diagnostic criterion for congenital LAAA was proposed that includes,

1. LA chamber should be of normal size.
2. The sac should have clearly defined communication with LA cavity, and
3. It should be located intra-pericardially with resultant distortion of the adjoining LV wall.

These outpouching are thought to be due to dysplasia of pectinate muscle and usually do not affect the whole auricle. But from studied literature, it becomes clear that the above definition falls short in many of the claimed cases. Cases have been claimed secondary to extra pericardial herniation, or in mitral Regurgitation, or in patients with supra-ventricular tachycardia. LAAA was also reported to be associated with congenital heart disease. These are included in acquired type of LAAA¹⁵.

The 1st case fulfills the criteria of congenital origin as the aneurysmal sac in her case was intra-pericardial had normal LA dimension and no MR. In the 2nd case, the sac was large, intra-pericardial location with part of the normal auricle visible at the base. The remarkable thing about the 2nd case is the presence of moderate MR and a very large LA. Whether this is congenital or acquired remains uncertain, but can be an altogether separate entity, where giant LA and LA Appendage aneurysm co-exist from birth.

Although most patients present in 3rd decade of life with no gender difference¹⁴, our cases presented earlier, one male child presented at 5yrs. and the other female at 18yrs. of age.

Most common symptom among reviewed patients were reported to be palpitation in 44.6% cases, followed by dyspnea on exertion in 28.7% cases, and chest pain in

11.9% of cases¹⁴. In both of our cases, palpitation was a common symptom. Beside this, the older one had chest pain and the younger one had shortness of breath on exertion. ECG in the older patient showed normal sinus tachycardia but the kid showed rhythm disturbance and AF interval of normal sinus rhythm.

There was no feature of thrombo-embolism in either of these cases, although there was CT finding in one case one suggesting thrombus within the cavity. The reported incidence of thrombo-embolism is about 6%¹⁴. Once the diagnosis is made, it is customary to proceed with surgical excision, as it offers excision of pathology and removal of symptom¹⁵.

Medical management is also reported to delay surgery for avoiding operative risk¹⁷. Catheter ablation also been reported in a patient with paroxysmal AF and a congenital giant LAA who was successfully treated by percutaneous pulmonary vein antrum isolation (PVAI)¹⁸. Surgery is focused on excision of the sac and Correct any added pathology, like closure of neck repair of mitral valve, anti-arrhythmia procedure.

Median sternotomy was noted to be the preferred procedure although left thoracotomy and minimally invasive endoscopic resection has been reported, even without cardiopulmonary bypass¹⁹. Our first case was done through right sub-mammary cosmetic incision. It could have been done through left thoracotomy. We were anticipating closure of sac with possible LA reduction. Cosmesis was also kept in mind as the patient demanded little scar. As the patient was a young girl the thoracotomy was preferred although LA reduction was not deemed necessary on table. TEE confirmed complete collapse of the cavity as was in pre-discharge echo. For the second case, median sternotomy and CPB was performed. After cardioplegic arrest, sac was excised and neck closed with a piece of pericardium and resected margin over sewn. LA reduction not done in spite of large LA to prevent possible distortion of growing pulmonary veins. Electrocautery lesions were produced around the LAA orifice to isolate auricular foci. LA remained as a very large cavity as documented in post-operative echocardiography.

Mitral valve repair was done - a cleft closure in P2 segment and posterior annuloplasty performed using Paneth-Hetzer technique. There was tethering of the posterior mitral leaflet caused AML to appear prolapsed.

After follow up both patients were asymptomatic and with sinus rhythm. Patient with large LA and mitral regurgitation need further follow-up to see progress in LA reduction and persistence of mitral competency, which was trace at discharge.

Conclusion:

Although left atrial appendage aneurysm is a rare heart defect, early diagnosis and prompt surgical resection can bring good outcome as in our cases.

Reference:

1. Tigen KM, dogan CE, Guler A, et al: The dangerous fifth chamber; the congenital left atrial appendage aneurysm. *Cardiovas J Afr* 2012;23:e3-e4.
2. Ulucam M, Muderrisoglu H, Sezgin A: Giant left atrial appendage aneurysm: the third ventricle!. *Int J cardiovasc Imaging*. 2005;21:225-230.
3. Fountain-Dummer RR, Wiles HB, Shuler CO, Bralley SM, Shirali GS. Recognition of left atrial aneurysm by fetal echocardiography. *Circulation*. 2000;12:2282-83.
4. Cho MJ, Park JA, Lee HD, et al: Congenital left atrial aneurysm diagnosed by fetal echocardiography. *J Clin Ultrasound* 2010; 38:94-96.
5. Washgal AB, Applebaum A, Crystal P, et al : Atrial tachycardia as the presenting sign of a left atrial appendage aneurysm. *Pacing Clin Electrophysiol* 2000; 23:283-285.
6. Conradi G, Deetjen A, Mollmann S, et al: Symptomatic atrial fibrillation as the first symptom of a giant left atrial aneurysm. *Clin Res cardiol* 2006;95:614-616.
7. Awasthy N, Tomar M, Radhakrisnan S, Shrivastava S, Iyer KS: symptomatic giant left atrial aneurysm in a child: a rare entity. *Images in Pediatric Cardiology*.
8. Hall J, Dobbs RH: Cerebral emboli from aneurysm of left atrial appendage. *Proc R Soc Med* 1969;62:911.
9. Tidake A, Gangurde P, Mahajan A. Congenital left atrial appendage aneurysm associated with a systemic embolism. *Cardiol Young* 2015;25:597-9
10. Nezafati MH, Hayanou HN, Kahrom M, Khooei A, Nezafati P. Five chambered heart: case of a huge left atrial appendage aneurysm. *Cardiovascular Pathology* 34 (2018) 43–45.
11. Kawata M, Imanaka k, Matsuoka T, et al: Left atrial aneurysm causes severe mitral regurgitation and heart failure: report of a successfully treated case. *J Thorac Cardiovasc Surg* 2012;143:e17-e18.
12. Asfalou I, Boumaaz M, Raissouni M, Sabry M, Benyass A, Zbir EM. Huge left atrial aneurysm revealed by chronic hiccups. *J Saudi Heart Assoc* 2017;29:293-296.
13. Burke RP, Mark JB, Collins JJ, Cohen LH. Improved surgical approach to left atrial appendage aneurysm. *J Cardiac Surg* . 1992;7:104-7.
14. Bin Wang, He Li, Li Zhang, Lin He, et al. Congenital left atrial appendage aneurysm. A rare case report and literature review. *Medicine*. 2018;97:2
15. Ayral MR, Hakim FA, Ghimire S, et al. Left atrial aneurysm: A systematic review of 82 cases. *Echocardiography*. 2014;00:1-8.
16. Foale RA; Gibson T.C; Guyer D.E; Gillan L; King M.E; Weyman A.E. Cong aneurysm of left atrium. *Circulation*. 1982; 66:1065-1069
17. Valentino MA, Danaf AJ, et al. Giant left atrial appendage aneurysm: A case of mistaken identity. *Journal of Cardiology Cases*. 2017;15:129-131.
18. Hof IE, Wildbergh TX, Van Driel VJ, et al. Atrial fibrillation with a giant left atrial appendage can be successfully with pulmonary vein antrum isolation. 2012;20:179-81.
19. Vagefi PA, Choudhury M, Hilgenberg ADs. Excision of an aneurysm of the left atrial appendage. *J thorax Cardiovasc Surg*. 2007;133:822-3.