

## A Rare Case Series: Cardiac Myxoma and their Versatile Presentation

Poppy Bala<sup>1</sup>, A. Q. M. Reza<sup>2</sup>, M. Atahar Ali<sup>3</sup>, Nighat Islam<sup>4</sup>, Mahmood Hasan Khan<sup>5</sup>, Abeeda Tasnim Reza<sup>5</sup>.

---

### Abstract:

**Background:** Although rare, cardiac myxomas are the most common primary cardiac tumor with an incidence of 0.5 per million per year. Clinical presentation is variable and ranges from intracardiac obstruction, embolization to the pulmonary and systemic circulation, heart failure or constitutional symptoms. Surgical resection is the only effective treatment to prevent its debilitating and catastrophic complication.

**Case summary:** Here, three atypical presentations as well as three different locations of cardiac myxomas were reported. First one is a rare case of ST-elevated myocardial infarction due to myxoma that originated from the left ventricle. One case involved right sided myxomas with pulmonary embolism. The third case involved huge left atrial myxoma combined with recurrent syncope. All three cases were almost

misdiagnosed due to their atypical presentation. Echocardiography was the primary tool for detecting and diagnosing these cases. Subsequently all three patients underwent successful resection of myxoma. We also review clinical presentations and diagnostic characteristics of cardiac myxomas.

**Conclusion:** Rare cardiac myxomas may have various clinical and imaging features. Physicians especially other non-cardiologist must increase their awareness of this disease and engage in the early diagnosis. Echocardiography is the diagnostic procedure of choice. The long-term survival after surgical resection is excellent and recurrence is rare.

**Keywords:** Cardiac tumor, Atrial myxoma, Ventricular myxoma, Echocardiography, Imaging, • Case report

---

(Bangladesh Heart Journal 2024; 39(1): 63-68)

### Introduction:

Myxoma is the most common non-malignant primary cardiac tumor with an estimated incidence of 0.5 per million per year<sup>1</sup>. Typically, it is diagnosed by echocardiography. However, certain myxomas have rare features such as rare sites of attachment, coexistence with other heart disease, multiple masses, recurrent masses, severe calcification, familial masses and necrosis of the myxoma that are likely

to lead to misdiagnosis. We report three rare cases of cardiac myxoma and review relevant literature.

### Case Descriptions:

#### Case 1:

A 50-year-old man presented with an-hour history of sudden onset of severe central chest pain and

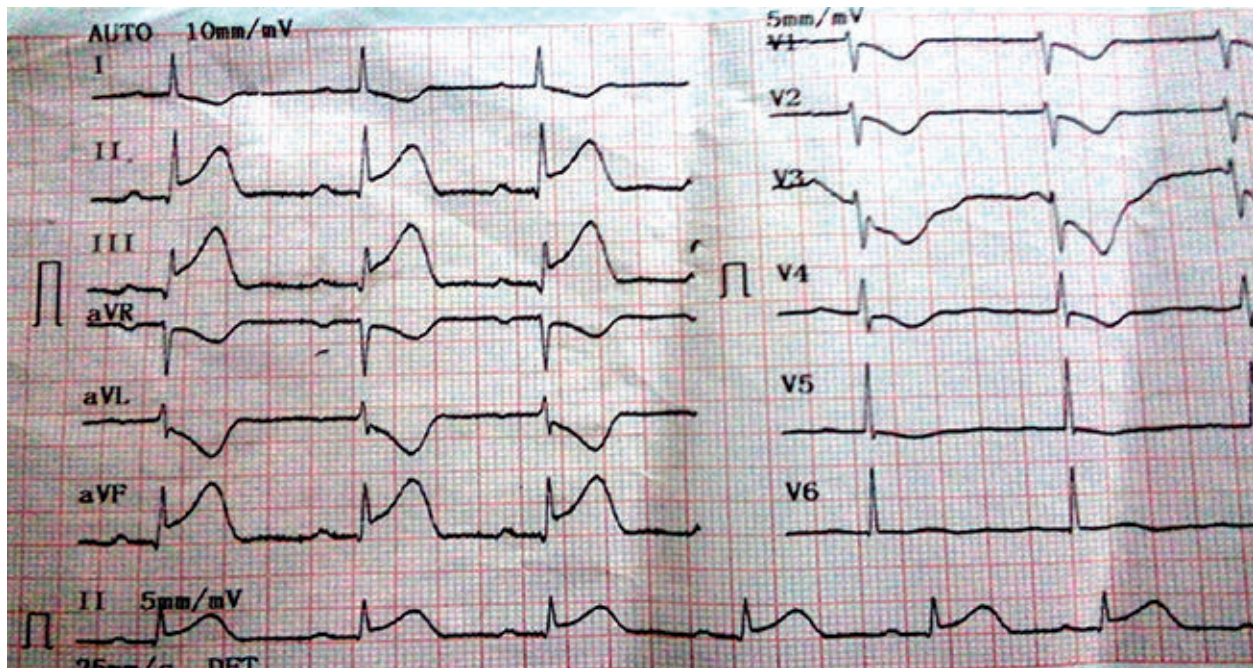
- 
1. Senior Specialist, Electrophysiology and Heart Failure Department, Evercare Hospital, Dhaka, Bangladesh.
  2. Senior Consultant, Department of Cardiology, Evercare Hospital, Dhaka, Bangladesh.
  3. Senior Consultant, Electrophysiology and Heart Failure Department, Evercare Hospital, Dhaka, Bangladesh.
  4. Consultant, Department of Non-invasive Cardiology, Evercare Hospital, Dhaka, Bangladesh.
  5. Associate Consultant, Department of Cardiology, Evercare Hospital, Dhaka, Bangladesh

**Address of Correspondence:** Dr. Poppy Bala, MBBS, MD Cardiology (NICVD),FACC, Fellowship in EPS and Pacing, Senior Specialist of Electrophysiology and Heart Failure Department, Evercare Hospital, Dhaka, Bangladesh. Mob. number: 01711635863, Email. drpoppybala@gmail.com

---

DOI: <https://doi.org/10.3329/bhj.v39i1.70723>

Copyright © 2017 Bangladesh Cardiac Society. Published by Bangladesh Cardiac Society. This is an Open Access articles published under the Creative Commons Attribution-NonCommercial 4.0 International License (CC BY-NC). This license permits use, distribution and reproduction in any medium, provided the original work is properly cited and is not used for commercial purposes.



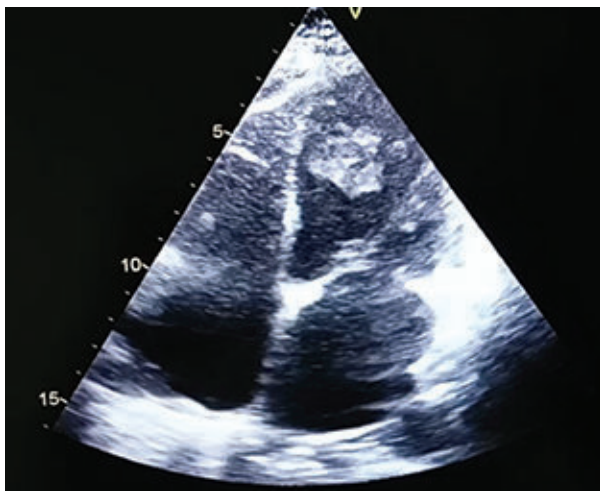
**Fig.-1:** 12 lead ECG shows Acute ST-elevation MI inferior.

diaphoresis. Patient was hypotensive and pulse rate was 60 beat per minutes. Electrocardiogram demonstrated normal sinus rhythm with ST-T-wave elevation in lead II, III and aVF (Fig. 1). Laboratory investigations were remarkable for leucocytosis and elevated troponin. Transthoracic echocardiogram demonstrated wall motion abnormalities and multiple myxomatous masses in left ventricle attached to interventricular septum. Coronary angiography demonstrated no significant

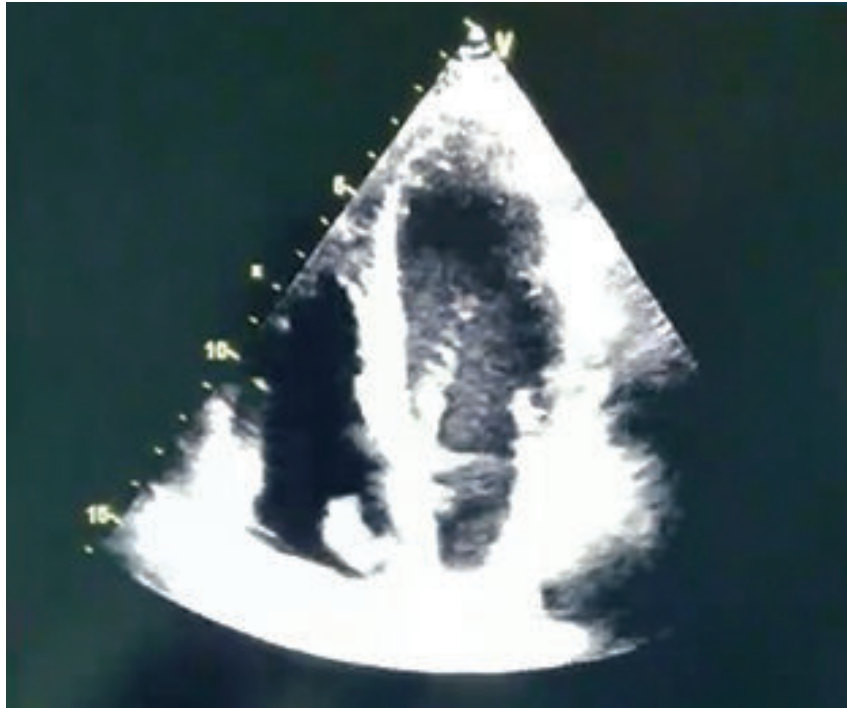
coronary artery disease. In the absence of obstructive lesion, normal coronaries and presence of myxoma, it's a possibility of myxoma embolization to the coronary arteries as the cause of her troponin elevation and wall motion abnormality. Subsequently he underwent successful resection of the ventricular myxoma.

#### Case 2:

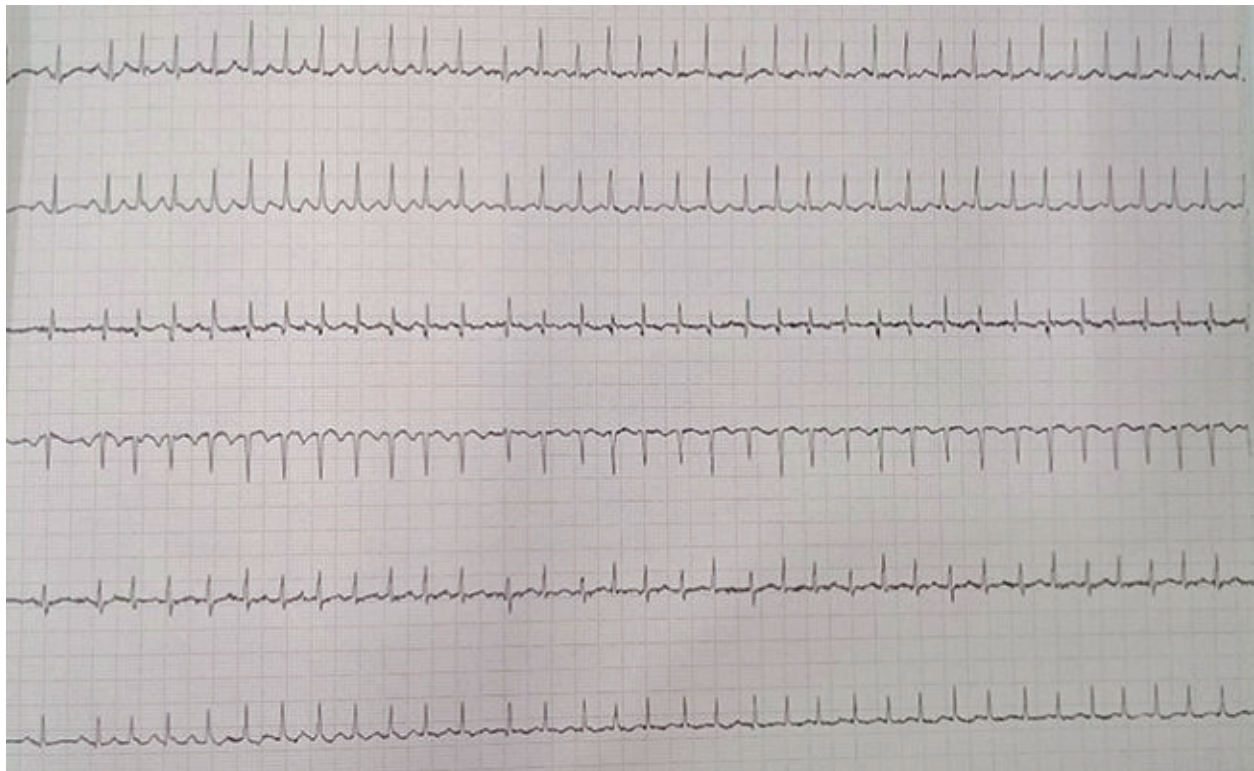
A 35 year old housewife was admitted with progressive exertional dyspnoea for the last three weeks and palpitation. She did not admit to pain at any site nor to hemoptysis. There was nothing relevant in the past history. On admission, the pulse rate was 160 beats/minute and irregular in rhythm (Fig. 4). Blood pressure, measured in the left arm, was 90/60 mmHg. There were no murmurs. Chest radiography was unremarkable. The electrocardiogram showed atrial fibrillation with fast ventricular rate. Immediately pharmacological cardioversion was done which reverted AF to sinus rhythm. But still dyspnea persisted. D-dimer, troponin I, pro- BNP and other blood parameters were normal. Echocardiography showed the presence of a medium size myxoma attached to intra-atrial septum in right atrium and not prolapsing through the tricuspid valve (Fig 3). CT scan showed filling defect in pulmonary arteries (Fig.5). Patient was sent for surgery.



**Fig.-2:** 2D Echocardiography showing left ventricular Myxoma attached to interventricular septum.



**Fig.-3:** 2D Echocardiography showing right atrial Myxoma attached to upper part of interatrial septum.



**Fig.-4:** 12 lead ECG atrial fibrillation with fast ventricular rate

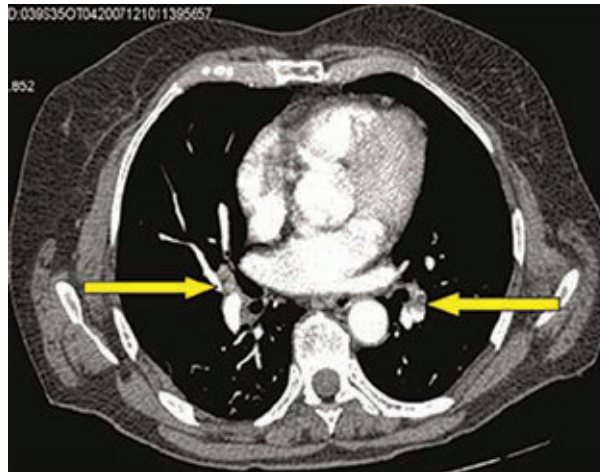


Fig.-5: CT scan shows filling defect in pulmonary arteries.

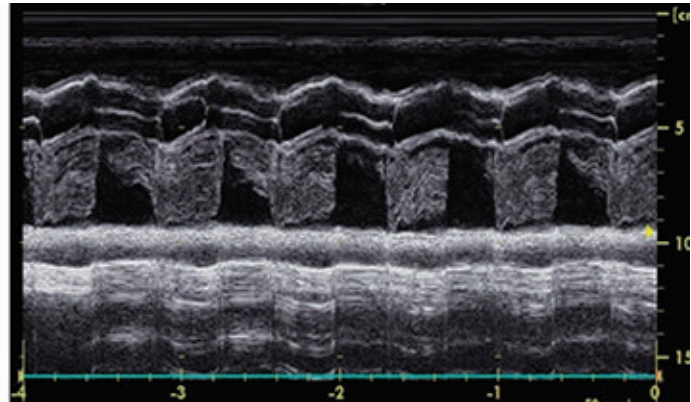
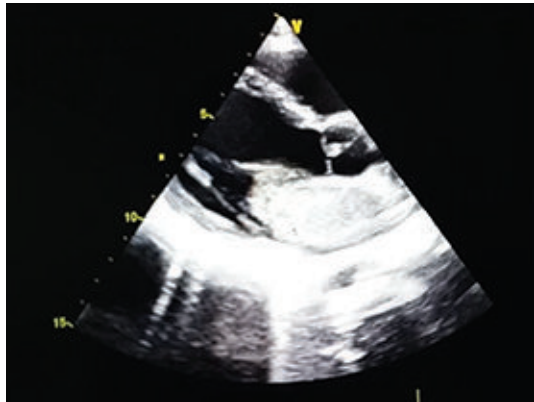


Fig.6 and 7: 2D and M mode echocardiography showing large myxoma occupying most of the LA.

### Case 3:

A 45-year-old diabetic, hypertensive woman with a longstanding history of exertional dyspnea admitted into the hospital with complaints of recurrent loss of consciousness. Previously she was evaluated neurologically and did repeat CT scan of brain, which was unremarkable. Constitutional symptoms such as arthralgia, myalgia, and weight loss were also present. On physical examination bilateral pedal oedema was noted and mid diastolic murmur and pan systolic murmur in mitral area. The electrocardiogram showed left bundle branch block. Chest X-ray revealed mild cardiomegaly. Echocardiography revealed a large myxoma occupying in two third of the left atrium, which was attached to inter atrial septum and move towards left ventricle during diastole, producing mitral valve obstruction. Left the cardiac chambers were dilated and interventricular septum paradoxical in motion. Moderate LV systolic

dysfunction was present. There was Grade II mitral regurgitation (MR) - and mild pulmonary artery hypertension (PAH). The patient was diagnosed with LA myxoma and scheduled for surgical resection.

### Discussion:

Cardiac tumors represent 0.2% of all tumors, secondary and metastatic form are 20 to 40 times more common than primary tumors<sup>2</sup>. Among primary cardiac tumors, 75% are benign and 50% are myxoma with an incidence of 0.0017% in general population<sup>2-4</sup>. Most common site of myxoma is in left atrium (75%) followed by right atrium (18%), 5% in both atria & the ventricle and more rarely in aorta, pulmonary artery, ventricles vena cava or even in other organ<sup>3-5</sup>. The majority of cardiac myxomas are sporadic and mostly occur as an isolated lesion in middle-aged women<sup>6</sup>. The differential diagnosis formed between thrombus and rhabdomyoma<sup>7</sup>.

Signs and symptoms caused by myxomas depends on mobility, size, shape, location, growth rate; pedicle length; tumor activity; the shedding of debris (or lack thereof); intra-tumoral bleeding, degeneration, and/or necrosis; as well as physical activity and body position. Most of the patient present with the one or more symptoms of classical triad of intracardiac obstruction to blood flow, thromboembolic events and constitutional symptoms. Constitutional symptoms consist of shortness of breath, fever, anemia, fatigue, joint pain, weight loss, and even cachexia and other systemic reactions <sup>8</sup>.

Here, first case involved a myxoma attached to the interventricular septum of left side. The incidence of coronary artery embolization from atrial myxoma resulting in MI is rare (0.06%) (9); occurrence with left ventricular myxoma is even rarer. Low occurrence is may be due to the coronary apertures form a right-angled junction within the aortic root, which allows some level of protection of the coronaries by the aortic valve cusps <sup>9</sup>. A study by Braun et al. <sup>10</sup>, 40 cases of myxoma-related MI were reviewed and it was noted that the right coronary artery is most commonly involved and up to one-third of documented coronary angiogram was normal. The reason behind having a normal coronary angiogram in patients with myxoma and acute MI is still not clearly known. It was suggested hypothesis is that the high rate of spontaneous recanalization after the myxomatous embolization from myxoma <sup>11-13</sup>.

Most myxomas are soft and friable. Our second case involved a patient with pulmonary embolism caused by right atrial myxoma. RA myxoma may present with a feature of obstructed tricuspid valve or pulmonary embolism. Common site of origin in right atrium is fossa ovalis or base of interatrial septum. Most common manifestation is dyspnea (80%) and right sided heart failure but patients may also present with atypical chest pain, palpitation pulmonary embolism, hemoptysis and syncope <sup>14</sup>.

Last case involved a patient with a long medical history of shortness of breath and recurrent syncope. The long list of reported symptoms and signs includes chest pain, dyspnea, orthopnea, fever, malaise and fatigue, weight loss, cough, palpitation, cyanosis and clubbing, Raynaud's phenomenon, arthralgia, myalgia, muscle weakness, loss of hair, dizziness, fainting, aphasia, peripheral embolism, syncope, transient ischemic attack (TIA), cerebrovascular accident (CVA), sudden cardiac death and heart failure <sup>1,15,16</sup>. These symptoms may accompany the change in body position. Recent studies suggest that myxomas produce and release interleukins

into the blood circulatory system, which may be responsible for the wide spectrum of systemic inflammatory or autoimmune problems. Constitutional symptoms may be related to the production of interleukin 6 (IL-6), a principal mediator of the acute phase protein response <sup>17</sup>. In our case mitral regurgitation can cause dyspnea. LV inflow obstruction causing low cardiac output was the reason behind recurrent syncope. It was easily mistaken as TIA in the absence of abnormality in CT scan.

Two-dimensional echocardiography and color Doppler are the most common approaches used to diagnose myxoma and detect hemodynamic changes. In some cases, cardiac computed tomography or magnetic resonance imaging are recommended. Certain conditions must be distinguished from myxoma, such as thrombi, other primary cardiac tumors (eg, cardiac rhabdomyoma, sarcoma, vascular tumor, mitral valve papillary fibroelastoma), metastases, and vegetations. The gold standard for diagnosis remains pathological evidence <sup>1,6</sup>. Myxomas should be surgically removed as soon as they are diagnosed. Surgical excision of myxoma include large resection of their pedicle to prevent recurrence <sup>1</sup>. After surgery patients' symptoms usually disappear. Recurrence after the surgical resection of primary lesions has been observed in 1 to 4% of sporadic cases and 12 to 22% of familial cases <sup>18</sup>.

#### **Conclusion:**

Cardiac myxomas may have various clinical and imaging features. Clinicians and echo- cardiographer must increase their awareness of this disease. Early diagnosis and prompt surgical resection are essential to prevent further major complication.

#### **References:**

1. MacGowan SW, Sidhu P, Aherne T, Luke D, Wood AE, et al. Atrial myxoma: national incidence, diagnosis and surgical management. (1993) *Ir J Med Sci* 162: 223-226.
2. Arruda MV, Braile DM, Joaquim MR, Soares MJ, Alves RH. Resection of left ventricular myxoma after embolic stroke [in English and Portuguese]. *Rev Bras Cir Cardiovasc*. 2008; 23:578-80.
3. Diaz A, Di Salvo C, Lawrence D, Hayward M. Left atrial and right ventricular myxoma: an uncommon presentation of a rare tumour. *Interact Cardiovasc Thorac Surg*. 2011;12:622-3.
4. Vale Mde P, Freire Sobrinho A, Sales MV, Teixeira MM, Cabral KC: Giant myxoma in the left atrium:

- case report [in English and Portuguese]. *Rev Bras Cir Cardiovasc.* 2008;23:276-8.
5. Croti UA, Braile DM, Souza AS, Cury PM. Right ventricle and tricuspid valve myxoma [in Portuguese]. *Rev Bras Cir Cardiovasc.* 2008;23:142-4.
  6. Van Gelder HM, O'Brien DJ, Staples ED, Alexander JA. Familial cardiac myxoma. *Ann Thorac Surg* 1992;53:419-424.
  7. Jang KH, Shin DH, Lee C, Jang JK, Cheong S, Yoo SY. Left atrial mass with stalk: thrombus or myxoma? *J Cardiovasc Ultrasound.* 2010; 18:154-6.
  8. Strecker T, Agaimy A, Zelzer P, Weyand M, Wachter DL. Incidental finding of a giant asymptomatic right atrial tumor. *Int J Clin Exp Pathol* 2014; 7:4528-4530.
  9. Lehrman KL, Prozan G, Ulyot D. Atrial myxoma presenting as acute myocardial infarction. *Am Heart J* 1985;110:1293-1295.
  10. Braun S, Schrotter H, Reynen K, Schwencke C, Strasser RH. Myocardial infarction as complication of left atrial myxoma. *Int J Cardiol* 2005;101:115-121.
  11. Al Zahrani IM, Alraqtan A, Rezk A, Almasswary A, Bella A. Atrial myxoma related myocardial infarction: case report and review of the literature. *J Saudi Heart Assoc* 2014;26:166-169.
  12. Rath S, Har-Zahav Y, Battler A, Agranat O, Neufeld HN. Coronary arterial embolus from left atrial myxoma. *Am J Cardiol* 1984;54:1392-1393.
  13. Hashimoto H, Takahashi H, Fujiwara Y, Joh T, Tomino T. Acute myocardial infarction due to coronary embolization from left atrial myxoma. *Jpn Circ J* 1993;57:1016-1020.
  14. Vidne B, Atsmon A, Aygen M, Levy MJ. Right atrial myxoma: case report and review of the literature. *Isr J Med Sci* 1971; 7: 1196-200.
  15. J. Robert, M. Brack, S. Hottinger, A. Kadner, and H.-R. Baur, "A rare case of left ventricular cardiac myxoma with obstruction of the left ventricular outflow tract and atypical involvement of the mitral valve," *European Journal of Echocardiography*, vol. 10, no. 4, pp. 593-595, 2009.
  16. F. O'Rourke, N. Dean, M. S. Mouradian, N. Akhtar, and A. Shuaib, "Atrial myxoma as a cause of stroke: case report and discussion," *Canadian Medical Association Journal*, vol. 169, no. 10, pp. 1049-1051, 2003.
  17. G. Watts, D. Sadashivan, V. Gopalan, and S. Sharma, "Left atrial myxoma presenting with acute pancreatitis," *The Internet Journal of Thoracic and Cardiovascular Surgery*, vol. 8, no. 2, 2007.
  18. Reynen K. Cardiac myxomas. *N Engl J Med* 1995; 333:1610-1617.