

Parathyroid Adenoma - Surgical Challenge in a Crippling Condition

Dey BK^a, Al-Amin Z^b

Abstract

Background: Primary hyperparathyroidism (PHPT) is associated with either an adenoma or hyperplasia of chief cells of the parathyroid gland. It may occur sporadically, as a single autosomal dominant familial disorder, or as a part of the autosomal dominantly transmitted complex of multiple endocrine neoplasia (MEN). PHPT is relatively rare in children and adolescents. It is a condition characterized by an inappropriate excess of parathyroid hormone (PTH) secretion.

Method: This study was carried out in the Department of Otolaryngology and Head-Neck Surgery, BIRDEM General Hospital, Dhaka, Bangladesh from July 2009 to June 2015. A total 35 patients of different age group of both sex were included in this study. Preoperative localization test, including sestamibi scan, ultrasound or both were done for all patients.

Result: The total number of patients were 35 which included 19 males (54.29%) and 16 females (45.71%). The age of the patients varied from 18 to 65 years (average 40.90 years). All of these patients underwent operative removal of the adenoma. Serum PTH levels were above normal (>53 pg/ml) in all patients and ranged from 65 to 700 pg/ml. Serum calcium levels were above normal (>11 mg%) in most cases and ranged from 10.4 to 14.8 mg%. In our study, 25 patients (71.42%) had high calcium levels with the ten cases were at upper normal. Serum phosphate (PO₄) levels were on an average 1.8 (lower normal). In view of the raised calcium levels, the PTH was estimated followed by either sonography or CT scan. Serum PTH levels (85-700 pg/ml) were very high in 18 cases, high in 11 cases (65-85 pg/ml) and upper normal in 6 cases (59-64). In our study after operation, 13 patients developed hypocalcaemic state and required intravenous calcium at operation day and first post operative day, and rest of the patient's hypocalcaemic state corrected by oral calcium supplement. In our study temporary hypocalcaemia was very common and reported recurrent laryngeal nerve injury was less than one percent.

Conclusion: In parathyroid adenoma bone resorption causes recurrent bone fractures leading to a crippling condition. Preoperative localization of parathyroid adenoma with the help of sestamibi scan, surgical expertise need to remove the tumor and post operative calcium level management with the help of endocrinology department are necessary for successful management of parathyroid adenoma.

Key words: Primary hyperparathyroidism, adenoma, parathormone, hypercalcaemia, Tc-99m-sestamibi scintigraphy.

(BIRDEM Med J 2017; 7(2): 138-142)

Author Information

- a. Dr. Badhon Kumar Dey, Registrar, Department of Otolaryngology & Head-Neck Surgery; BIRDEM; Dhaka.
- b. Dr. Zaheer Al-Amin; DLO (Eng); FRCS (Ire); FRCS (Ed); Professor & Head, Department of Otolaryngology & Head-Neck Surgery; BIRDEM; Dhaka.

Address to corresponding: Prof. Zaheer Al Amin, Professor & Head, Department of Otolaryngology & Head-Neck Surgery; BIRDEM; Dhaka. email: alizaheeralamin@gmail.com

Received: November 25, 2016 **Accepted:** February 28, 2017

Introduction

In 1852, Sir Richard Owen first described the parathyroid glands while performing necropsy on a rhinoceros. In 1879, Sandström described human parathyroids. In 1925, Mandl performed the first parathyroidectomy in Vienna. The patient was initially symptom free but developed recurrent bone problems 6 years later PHPT is the most frequent cause for hypercalcemia. The incidence of PHPT ranges from 50

to 500 for 100,000 population.¹ PHPT is relatively rare in children and adolescents. The incidence is increased with age and women are affected twice as much as men.² In most cases, PHPT is caused by a solitary adenoma, while in 10% of cases there is primary hyperplasia, and multiple adenomas are the cause in 4% of the cases. In 1% of the cases the etiology of hyperparathyroidism is carcinoma of the parathyroid, cyst, lipoadenoma or lipohyperplasia.³

The treatment of choice for PHPT is surgery. Adenomas are removed or all abnormally enlarged parathyroid glands are biopsied (frozen section). Hyperplasia usually affects all four parathyroid glands and requires their removal. Some parathyroid tissue is retained and reimplanted surgically where it will continue to produce parathyroid hormone and regulate blood calcium levels. Carcinoma of the parathyroid glands (very rare, <1%) requires removal of the affected gland and involved adjacent soft tissue and regional lymph nodes.

Indications for parathyroidectomy include PHPT and symptomatic secondary or tertiary hyperparathyroidism (approximately 5% of patients with renal disease). Although the predominating trend during most of the 20th century was to perform surgery in asymptomatic patients to prevent complications, that recommendation may be changing. In 1991, a National Institutes of Health (NIH) consensus conference published guidelines for parathyroidectomy in asymptomatic patients. However, a recent survey among endocrine surgeons demonstrated that more than 72% of parathyroidectomies were performed in patients referred primarily for incidental hypercalcemia. Recent literature has suggested a survival advantage in patients undergoing parathyroidectomy versus those who were observed.

Most patients with HPT are classified as asymptomatic, careful questioning usually can elicit symptoms related to hypercalcemia. These symptoms are related to nephrocalcinosis, cholelithiasis, chronic pancreatitis, peptic ulcer disease, osteoporosis, and depression. Less commonly, metastatic calcifications may develop in the cornea, conjunctiva, and joints (gout, pseudogout). Although they still may be encountered, brown tumors, osteitis fibrosis cystica, pathologic fractures, and other severe bony complications.⁴

Indications for surgery in asymptomatic patients with primary HPT (1991 NIH Consensus Conference) are as follows.⁵ Markedly elevated serum calcium

concentration (>11.5 mg/dL), previous episode of life-threatening hypercalcemia, reduced renal function (creatinine clearance [CrCl] reduced by 30% compared with age-matched control subjects), radiologic evidence of kidney stones or nephrocalcinosis, a 24-hour urine calcium level greater than 400 mg, reduction in bone density greater than 2 standard deviations for age-, gender-, and race-matched control subjects, medical surveillance not suitable or desirable.

Methods

From July 2009 to June 2015, 35 patients were identified in the department of Otolaryngology and Head-Neck surgery, BIRDEM, Dhaka as suffering from PHPT due to parathyroid adenoma. Only those patients were included in whom suspicion was raised either on symptomatology, biochemical investigations or other imaging modalities like sonography or CT scan. Isotope imaging was performed to either confirm or rule out the same. Among the host of presenting symptoms varying from non-specific symptoms like generalized weakness to specific symptoms like renal stones or backache and noted that nephrocalcinosis was found in about half of the clinical presentations. All patients had an estimation of serum calcium (Ca), serum parathormone (PTH), serum phosphate (PO₄) and bone imaging.

Results

The total number of patients were 35 which included 19 males (54.29%) and 16 females (45.71%). The age of the patients varied from 18 to 65 years (average 40.90 years). All of these patients underwent operative removal of the adenoma. The biochemical study which revealed, serum PTH levels were above normal (>53 pg/ml) in all patients and ranged from 65 to 700 pg/ml. Serum calcium levels were above normal (>11 mg%) in most cases and ranged from 10.4 to 14.8 mg%. In our study, 25 patients (71.42%) had high calcium levels with 10 cases (28.57%) were at upper normal. Serum phosphate (PO₄) levels were on an average 1.8 (lower normal). In view of the raised calcium levels, the PTH was estimated followed by either sonography or CT scan. Serum PTH levels (85-700 pg/ml) were very high in 18 cases, high in 11 cases (65-85 pg/ml) and upper normal in 6 cases (59-64 pg/ml).

Clinical Features

The clinical manifestations of HPTH encompass bony changes, renal complications, gastrointestinal (GI) symptoms and possible neurological deterioration (Table-I).

Table I. Clinical features of the study subject

Symptoms	Frequency	%	Duration
Pain back and leg	18	56.25	3 months-6years
Generalized weakness	16	50	1 months-4years
Inability to walk	11	34.37	1 year-4 years
Stone passer	7	21.87	3 years-13 years
Spontaneous fracture femur	7	21.87	2 years-6 years
Fracture radius	7	21.87	2 months-2years
Weight loss	6	18.75	3 years-8 years
Swelling forearm (Brown tumour)	2	6.25	3 months
Sweating	1	3.12	6 months
Abdominal cramp, vomiting & loose stool	2	6.25	1day

Imaging techniques

X-Rays: Among 35 patients 25 (71.42%) cases had positive X-ray findings but 10 (28.57%) cases were normal. X-ray findings does not always correlate with the serum calcium level.

Table II. Radiological features of the study subjects

X-ray findings	Frequency	Ca level (mg/dl)
Nephrocalconosis with renal calculi with finger and toe	6	13
Nephrocalcinosis with Brown tumor forearm	2	11.88
Finger and toe (sub periosteal erosion)	4	12.5
Nephrocalcinosis	8	11.8-13.7
X-ray skull (pepper-pot appearance)	5	14 -14.3

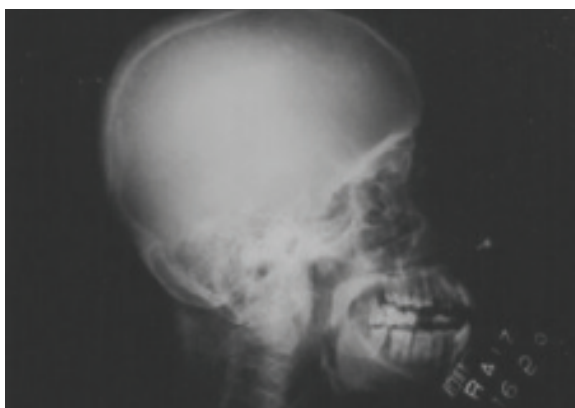

Figure 1. X-ray Skull (lateral) shows diffuse trabecular resorption, giving a granular ‘salt and pepper’ appearance. Loss of distinction between the outer and inner tables of the skull is seen.

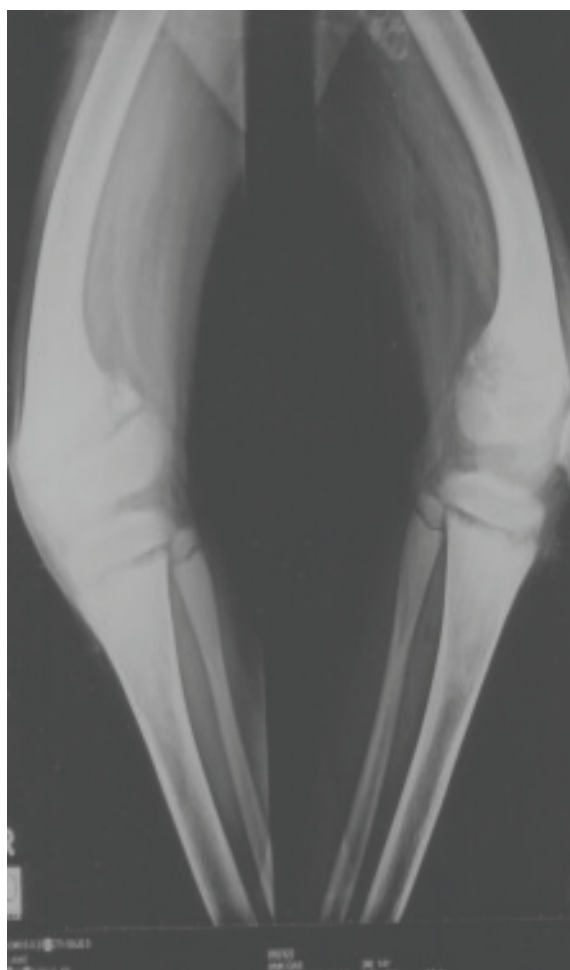

Figure 2. X-ray of left knee joint including lower half of femur & upper half of tibia and fibula shows metaphyseal dysplasia in the lower end of femur, both tibia and fibula. Bowing of both femur (Coxa vera) deformity noted.

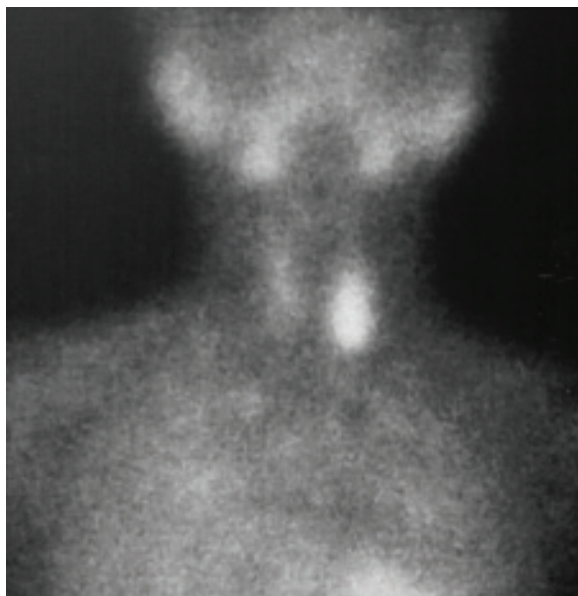


Figure 3. Parathyroid Scintigraphy shows tracer uptake is increased in the lower pole of the left lobe. Delayed image after 2.5 hours show increased tracer uptake in the lower pole of the left lobe of the thyroid gland

Per-operative findings

Once a suspected adenoma is located, carefully and completely remove it by gentle blunt dissection and ligating the vascular pedicle. Forward the gland to the pathologist for frozen section identification. An adenomatous parathyroid gland is confirmed by being hypercellular and having less adipose tissue relative to a normal parathyroid gland; therefore, identify the remaining glands and obtain a biopsy sample of a healthy gland for comparison.

Left inferior – 14 (One extra)

Right inferior – 7

Left superior – 6

Right superior – 7

Failed – 1

Twelve glands (37.5% of the total and 63.15% of the inferior pole glands) were quite far from the inferior pole of thyroid, one of which was extra. The size of the largest specimen was 6.5 x 3.5 cm – wt. 14 gm and the smallest was 6mm x 5mm – wt. 700 mg (average: 4.5 gm).

Table III. The time of commencement of post operative Ca supplement as well as pre-operative serum Ca level of different cases.

Pre operative serum Ca level (mg%)	Number of cases	The time of commencement of post operative Ca supplement
10.72	6	IV same night
11.42	7	IV 1 st post op
13.7	3	2 nd post op
12.5	4	3 rd post op
13	2	4 th post op
14	1	5 th post op
13	1	6 th post op

There was no definite relationship between pre op. Ca level & the time of starting the supplement but the lower pre op. Ca level goes more favor of early replacement and most cases can be managed with 500-1000mg. tds dose. PTH levels became normal within several weeks after surgery, once calcium homeostasis has stabilized. All the patients had been discharged within 6th to 32nd post operative days (average 14 days).

Discussion

The goal of treatment of hyperparathyroidism (most common cause being parathyroid adenoma) is to restore the patient to a normocalcemic euparathyroid state, to relieve symptoms and to prevent or possibly reverse complications of the disease. Resection of this parathyroid adenoma is the most effective treatment⁶.

Accurate preoperative detection and localization of parathyroid adenomas is of utmost importance in patient care, not only in improving the outcome but also in shortening the duration of operation and thereby lowering the morbidity as well.⁶

The various noninvasive imaging modalities other than radionuclide scintigraphy available for the preoperative detection and localization of parathyroid adenoma are ultrasonography, computed tomography and magnetic resonance imaging.

With high resolution real time ultrasonography, 50% of the parathyroid adenomas can be accurately localized. As it is cheap and rapid, it is usually recommended as the initial investigation. However, cervical adenomas that cannot be located by ultrasonography tend to weigh less than 200 mg and lie more medially behind the trachea or inferiorly behind the clavicular heads. Solitary

low echogenic follicular thyroid adenoma or rare thyroid cyst can present a diagnostic problem in hyperparathyroidism. The overall success rate achieved by CT in a previously unexplored patient is 75%.⁷ CT is usually successful in the low cervical adenomas, but only 50% of the mediastinal adenomas can be detected. The sensitivity of MRI is greatest in the mediastinum, where ectopic abnormal glands are found (Sensitivity ranging from 50%-88%) compared to 70% sensitivity in the neck. MRI can locate parathyroid tumors larger than 1 cm but can not distinguish small hyperplastic glands and though it performs better than CT but cannot precisely distinguish thyroid from adjacent parathyroid tumors.

A successful parathyroidectomy depends on the identification and the resection of the whole of parathyroids in hyperactivity. The surgical approach in I HPTH patients has evolved over the years. Resection of obviously enlarged parathyroid glands with or without biopsy of the remaining glands is performed. From the common presentation of nephrolithiasis to the relatively lower prevalence of asymptomatic hyperparathyroidism, surgical treatment of the parathyroid adenoma is associated with low renal failure rate, low mortality and low morbidity.

Conclusion

In this study observation revealed, parathyroid adenoma occurs more in male. Serum PTH level and serum Ca level were above normal in all patients. There was no relationship between pre-operative Ca level and time of starting the supplement but, the lower pre-operative Ca level goes more favor of early replacement and temporary hypocalcaemia was very common. No hungry

bone syndrome happened. Successful management of parathyroid adenomas requires the combined skills of the internist, endocrinologist, pathologist and surgeon. Improvement after operation is quite remarkable and breathtaking in some cases and the morbidity of the procedure is insignificant so it is a very rewarding surgery in a potentially crippling situation. Expertise need to be developed and referral is mandatory with obvious collaboration of endocrine department.

Declaration: This paper was presented in the 10th SAARC ENT Congress in Dhaka, Bangladesh, 2016

References

1. Bhansali A, Masoodi SR, Reddy KS, Behera A, das Radotra B, Mittal BR, et al. Primary hyperparathyroidism in North India: A description of 52 cases. *Ann Saudi Med* 2005; 25: 29-35
2. Kollars J, Zarrong AE, Rodeberg D. Primary hyperparathyroidism in pediatric patients. *pediatrics* 2005; 115: 974-980.
3. George P, Philip NP, Pawar B. Radiographic Appearance of Primary Hyperparathyroidism with Atypical Parathyroid Adenoma. *Internet Intern Medi* 2006; 6(2): 1-5.
4. Bailey BJ, Calhoun KH, Friedman N. *Atlas of Head Neck Surgery-Otolaryngology*. Vol 2. 2nd edition. Philadelphia: Lippincott Williams and Wilkins 2001: p 1018
5. O'Doherty MJ, Kettle AG, Wells P, Collins RE, Coakley AJ. Parathyroid imaging with t technetium-99m-sestamibi: preoperative localization and tissue uptake studies. *J Nucl Med* 1992; 33: 313-18.
6. Andersen PE, Cohen JI, Everts EC: Unilateral parathyroid exploration. *Arch Otolaryngol Head Neck Surg* 1998 Sep; 124(9): 1052-54.
7. Mozes MF, Soper WD, Jonasson O, Lang GR: Total parathyroidectomy and autotransplantation in secondary hyperparathyroidism. *Arch Surg* 1980; 115(4): 378-85.