

Case Report

Dengue-Chikungunya Co-Infection: A Case Report from 2017-Chikungunya Outbreak in Dhaka, Bangladesh

Haque HF^a, Rahim MA^b, Mahiuddin N^c, Amin MG^d, Afroz F^a, Afroze SR^a, Musa AKM^e

Abstract

A case of dengue virus and chikungunya virus co-infection is reported here. The patient had fever, severe generalized bodyache, arthritis as well as drowsiness. Laboratory investigations showed dengue-chikungunya co-infection. The objective of our report is to emphasize the co-existence of dengue and chikungunya in a clinical case and to aware the clinicians about chikungunya and dengue co-infection.

Key words: Bangladesh, chikungunya, co-infection, dengue fever, outbreak.

(*BIRDEM Med J* 2018; 8(1): 72-74)

Introduction

Chikungunya virus (CHIKV) and dengue virus (DENV) are the arboviruses currently circulating in Southeast Asia, Central and West Africa, the Pacific Islands and the Americas and their transmissions can occur simultaneously.¹ Among them chikungunya is emerging in Bangladesh whereas dengue is endemic.² DENV is the most relevant arbovirus in terms of morbidity, mortality and socioeconomic impact, threatening more than 2.5 billion individuals worldwide.³ It belongs to the *Flaviviridae* family, genus *Flavivirus* and is composed by four closely related serotypes (DENV 1, 2, 3, 4). On the other hand, CHIKV belongs to the *Togaviridae* family and genus *Alphavirus*.⁴

Author Information

- Dr. Hasna Fahmima Haque, Farhana Afroz, Samira Rahat Afroze, Registrar, Department of Internal Medicine, BIRDEM General Hospital and Ibrahim Medical College, Dhaka, Bangladesh.
- Dr. Muhammad Abdur Rahim, Assistant Professor, Department of Nephrology, BIRDEM General Hospital and Ibrahim Medical College, Dhaka, Bangladesh.
- Dr. Najeeb Mahiuddin, RMO, Department of Internal Medicine, BIRDEM General Hospital and Ibrahim Medical College, Dhaka, Bangladesh.
- Dr. Mohammad Gaffar Amin, Assistant Professor, Department of Cardiology, Dhaka Medical College, Dhaka, Bangladesh.
- Dr. AKM Musa, Professor and Head, Department of Internal Medicine, BIRDEM General Hospital and Ibrahim Medical College, Dhaka, Bangladesh.

Address of Correspondence: Dr. Hasna Fahmima Haque, Registrar, Department of Internal Medicine, BIRDEM General Hospital, Dhaka, Bangladesh. Email: drfahmimahaque@gmail.com

Received: December 16, 2017 **Accepted:** December 17, 2017

Case Report

A previously ambulant 75-year-old diabetic and hypertensive gentleman presented with high grade, continued fever, severe bodyache as well as drowsiness for 5 days. The patient also had severe pain in both knee joints, resulting in difficulty to move his legs and eventually he became bed bound.

The patient was drowsy, dehydrated, tachycardic and pyrexia. There was tenderness, increased local temperature and restricted movement of both knee joints.

Investigations showed haemoglobin 10.9 g/dl, erythrocyte sedimentation rate (ESR) 59 mm in 1st hour, normal total and differential white cell counts and a low platelet (62000/cmm) count. Anti-chikungunya IgM, anti-dengue IgM and IgG became positive while anti-chikungunya IgG was negative. Findings of x-ray of knee joints were suggestive of osteoarthritis.

He was treated with paracetamol, antiemetics and intravenous normal saline and discharged after 5 days of admission in afebrile state.

Discussion

Among the mosquito-borne viral infections, chikungunya and dengue are the two most rapidly spreading infections of global concern. *Aedes aegypti* and *Aedes albopictus* are the usual vectors for chikungunya, which are also responsible for transmission of dengue, hence well explains concurrence or co-incidences of dengue and chikungunya in endemic regions (Figure 1).² High rates of chikungunya-dengue co-infection have been reported in literature.⁵

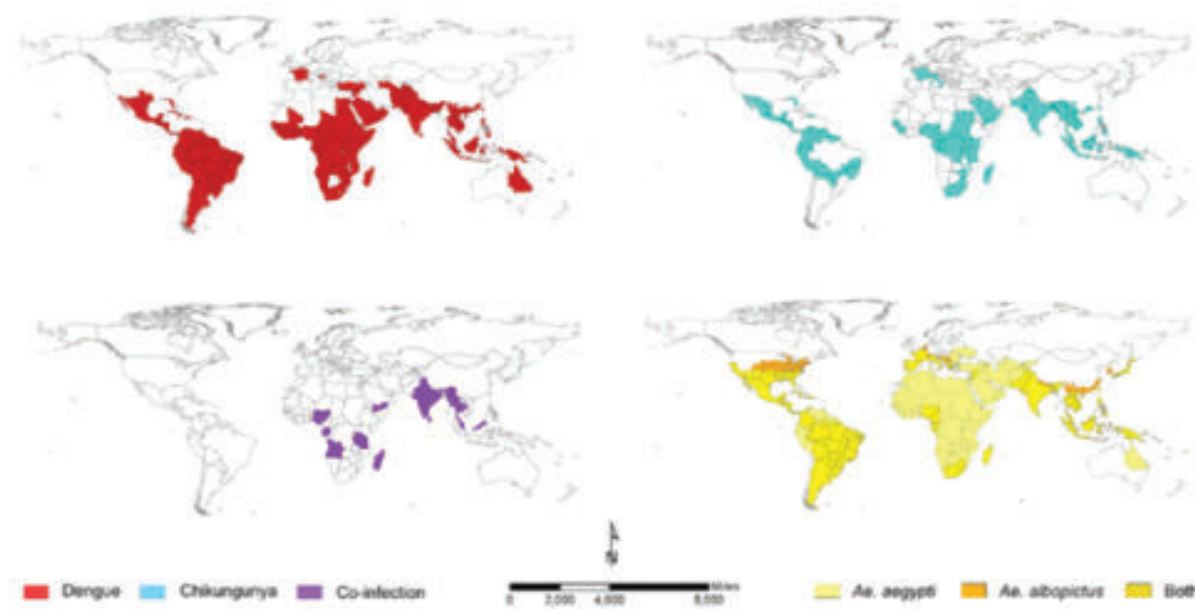


Figure 1. The global distributions of endemic/epidemic dengue (top left) and chikungunya (top right) and reports of co-infection (bottom left) as well as the principal vectors of both arboviruses, *Aedes aegypti* and *Aedes albopictus* (bottom right) [Adopted from Furuya-Kanamori et al. *BMC Infectious Diseases* 2016;16:188]

During an outbreak, clinical and epidemiological criteria may need to make a probable diagnosis of chikungunya and dengue fever, but confirmation requires fulfillment of laboratory criteria irrespective of clinical presentation.⁶ CHIKV and DENV usually cause a self-limited, febrile illness that is generally associated with arthralgias and myalgias.⁶ In our case, the patient had high grade, continued fever along with arthritis of both knees. Leucopaenia and thrombocytopaenia favour dengue whereas lymphopaenia and raised ESR favour diagnosis of chikungunya.^{7,8} Our patient had normal leucocyte count and thrombocytopenia.

Regarding further laboratory work-up, reverse-transcriptase polymerase chain reaction (RT-PCR) may be done in first week and IgM may appear after day 5 of symptom onset and last for weeks to months in both dengue and chikungunya.⁸ Both the anti-chikungunya IgM and anti-dengue IgM were positive in our case. We treated him with paracetamol, antiemetics and intravenous normal saline. Exclusion of dengue is more important than establishing chikungunya during febrile periods, as patients may require non-steroidal anti-inflammatory drugs (NSAIDs) in case of chikungunya, which is not advocated during dengue infection.^{2,9}

Dengue and chikungunya infections continue to co-exist in our country and there is substantial overlap in clinical presentation between these infections.^{2,8,10} So, clinicians should use simple clinical and laboratory criteria to predict these infections for appropriate management.

Prevention of dengue and chikungunya infection is also necessary like other vector borne diseases and by taking appropriate public health measures the burden of chikungunya and dengue infections can be reduced in Bangladesh.

Conflict of interest: Nothing to declare.

References

1. Edward T, Signor LCC, Williams C, Donis E, Cuevas LE, Adams ER. Co-infections with Chikungunya and Dengue Viruses, Guatemala, 2015. *Emerging Infectious Diseases* 2016;22:2003-5.
2. Rahim MA, Uddin KN. Chikungunya: an emerging viral infection with varied clinical presentations in Bangladesh: Reports of seven cases. *BMC Res Notes* 2017;10:410.
3. Bhatt S, Gething PW, Brady OJ, Messina JP, Farlow AW, Drake JM, et al. The global distribution and burden of dengue. *Nature* 2013;496:504-7.

4. Lecoin MP, Luplertlop N, Surasombatpattana P, Liégeois F, Hamel R, Thongrunkiat S, et al. Dengue and Chikungunya Coinfection – The Emergence of an Underestimated Threat. Available from <http://dx.doi.org/10.5772/64426> (accessed Nov. 30, 2017)
5. Saswat T, Kumar A, Kumar S, Mamidi P, Muduli S, Debata NK, et al. High rates of coinfection of Dengue and Chikungunya virus in Odisha and Maharashtra, India during 2013. *Infect Genet Evol* 2015;35:134-41.
6. Directorate General of Health Services (DGHS), Ministry of Health & Family Welfare. Government of People's Republic of Bangladesh. Bangladesh National Guideline on Clinical Management of Chikungunya Fever; 2017.
7. Chevillon C, Briant L, Renaud F, Devaux C. The chikungunya threat: an ecological and evolutionary perspective. *Trends Microbiol* 2008;16:80-88.
8. Ahmed JU, Rahim MA, Uddin KN. Emerging Viral Diseases. *BIRDEM Med J* 2017; 7(3):224-32.
9. Weaver SC, Lecuit M. Chikungunya virus and the global spread of a mosquito-borne disease. *N Engl J Med* 2015;372:1231-39.
10. Rahim MA, Zaman S, Sultana N, Islam A, Uddin KN. Chikungunya–dengue co-infection during pregnancy requiring preterm Caesarean section: first case report from Bangladesh. *Trop Doc* 2017 (First Published Dec 13, 2017). DOI: 10.1177/0049475517747431.