

## Case Report

---

# Ulcerative Colitis in a Bangladeshi Child: A Case Report

Hoque N<sup>a</sup>, Ahmed S<sup>b</sup>, Zaman T<sup>c</sup>

### Abstract

**Introduction:** *Ulcerative colitis (UC) is a chronic idiopathic inflammatory disorder of colon. Ulcerative colitis is uncommon in tropics and sub-tropics. We describe a case of pediatric ulcerative colitis with successful treatment. A 4-years-old girl who presented with passage of loose bloody stool, abdominal pain and mild arthralgia along with significant weight loss. Her height was 95 cm, and weight was 13 kg. Diagnosis was confirmed by colonoscopy and histopathology. Treatment was thereafter started with parenteral steroid initially then oral steroid and mesalamine. The patient is now on remission and is on regular follow up. UC is rare in Bangladesh, especially in children. Several conditions like infective colitis, allergic colitis, Meckel's diverticulitis, Crohn's disease, etc. may mimic the features of UC. So, if a child presents with recurrent bloody diarrhea, UC should be considered as a differential diagnosis.*

**Keyword:** *Bangladeshi Child, Ulcerative Colitis.*

*(BIRDEM Med J 2019; 9(1): 89-94)*

### Introduction

Ulcerative colitis (UC) is a chronic relapsing inflammatory condition of the colon, extending continuously from the rectum proximally to a varying degree. Typically, UC is suspected in a patient presenting with bloody diarrhea, tenesmus, abdominal pain, fatigue and weight loss. The incidence of pediatric-onset UC is roughly 15% to 20% of patients of all ages with UC, in most North American and European regions.<sup>1-3</sup> Children and adults develop similar symptoms however children often present with more extensive disease.<sup>4</sup> Childhood-onset UC is extensive in 60% to 80% of cases, twice as often as in adults. Because disease extent has been consistently associated with disease severity, it is not surprising that pediatric-onset UC has a worse disease course, with a 30% to 40% colectomy rate at 10 years, as compared with 20% in adults.<sup>4,5</sup> Children also have unique age-related considerations, such as growth,

puberty, nutrition and bone mineral density (BMD) accretion during adolescence, as well as differing psychosocial needs and development.

There is no available data regarding the incidence and prevalence of UC in Bangladesh. It is rare in children of Bangladesh. The diagnosis, management, course and prognosis of the disease remain highly enigmatic. In view of the situation, we report here a confirmed case of ulcerative colitis in a 4-year-old Bangladeshi child.

### Case Report

A 4-year-old girl was admitted in GHPD Department of BIRDEM General Hospital, Dhaka with frequent passage of blood mixed stool for 6 months. The frequency was about 8-10 times per day. Additional symptoms included anorexia, tenesmus, lower abdominal pain, weight loss and mild pain in large joints. For these symptoms she was treated several times by different physicians but did not have any improvement. She had no history of food allergies.

On physical examination, she looked moderately pale, mildly dehydrated and afebrile. Her heart rate was 110/min, blood pressure was 90/60 mmHg and respiratory rate was 24/min. There was no clubbing, lymphadenopathy and skin lesion. Her height was 95 cm (at 10th centile reference value of CDC) and weight was 13 kg (<3rd centile of reference value of CDC). Abdomen was soft, mild tenderness present in lower

---

### Author Information

1. Dr. Nazmul Hoque, Ex-Associate Professor and Head of the Department of GHPD, BIRDEM General Hospital, Dhaka.
2. Dr. Shireen Ahmed, Registrar, Department of GHPD, BIRDEM General Hospital, Dhaka.
3. Dr. Taslima Zaman, Department of Gastroenterology, Sheikh Fazilatunnessa Mujib Memorial KPJ Specialized Hospital, Gazipur

**Address of Correspondence:** Dr. Nazmul Hoque, Ex-Associate Professor and Head of the Department of GHPD, BIRDEM General Hospital, Dhaka. E-mail: alifbd@gmail.com

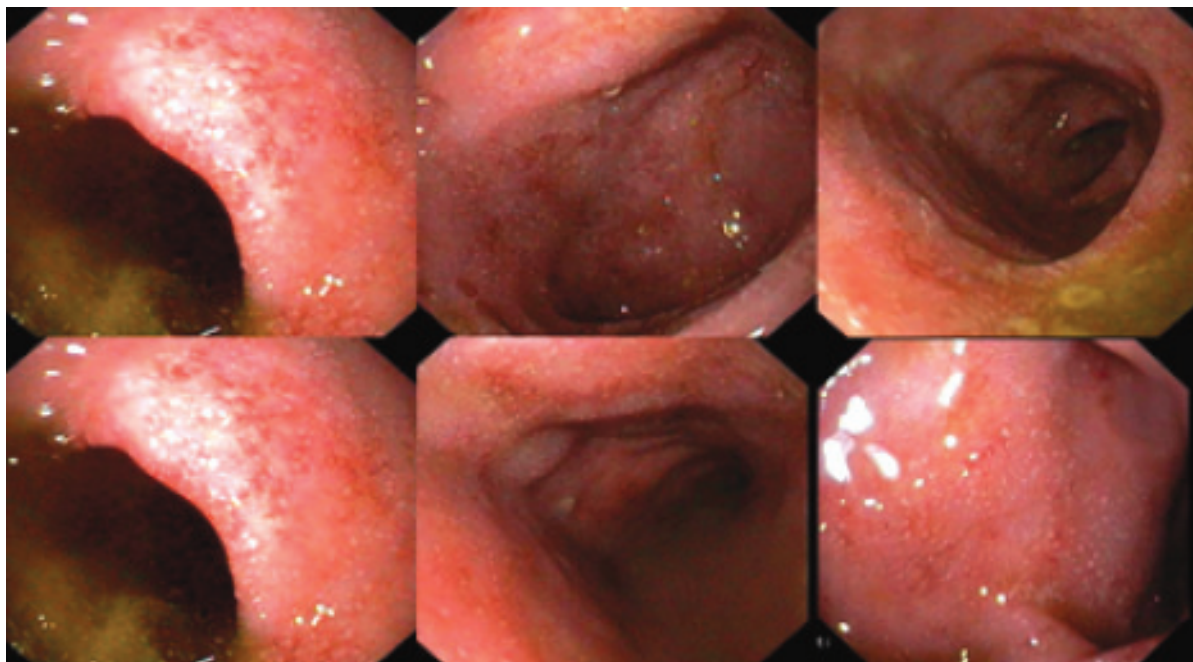
**Received:** September 26, 2018

**Accepted:** October 31, 2018

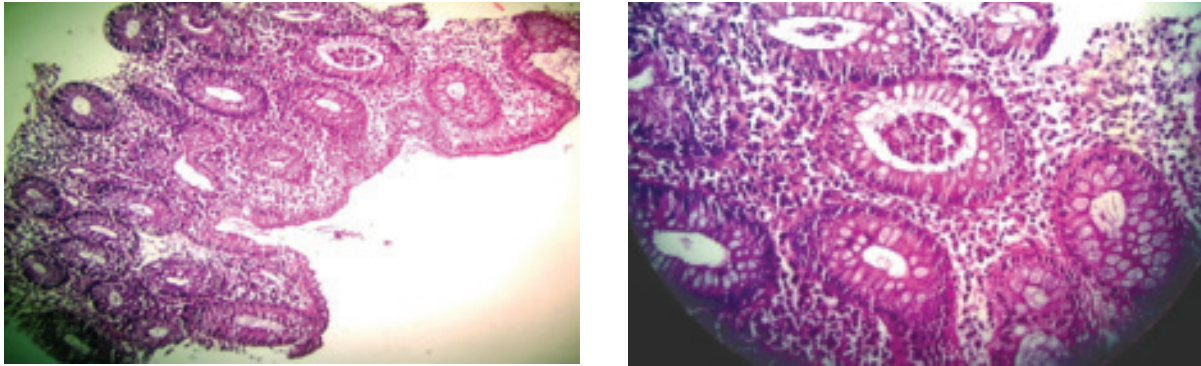
abdomen but there was no guarding or organomegaly. No abnormality was noted in the perianal region and no signs of inflammation in any joints. Other systemic examination revealed no abnormality.

Her investigations showed- Hb-5.8 gm/dl, PBF-microcytic hypochromic anemia, white cell count  $13.3/\text{mm}^3$  with neutrophilia (74%) and thrombocytosis ( $581/\text{mm}^3$ ). ESR was 90 mm in 1st hour, CRP was high (6 mg/dl), S. Albumin 25mg/dl, S.electrolytes and S.creatinine were essentially normal. ANA was negative. Stool microscopy showed numerous pus cells and RBCs. Blood, stool and urine culture were negative. Abdominal ultrasound revealed normal study. Chest X-ray was also normal. Colonoscopy under short G/A (seen up to caecum) showed the mucosa of the whole colon was ulcerated and granular in appearance, contact bleeding seen and the vascular pattern was also lost throughout the length of the colon and biopsy was taken for histopathology (Figure 1). Colonic biopsy revealed focal surface erosion, focal cryptitis and crypt abscesses. The lamina propria revealed infiltration of acute as well as chronic inflammatory cells. No granuloma or malignancy was found. The findings were suggestive of active colitis, compatible with ulcerative colitis (Figure 2,3). So, the diagnosis of ulcerative colitis was made. The activity of UC using the pediatric ulcerative colitis activity index (PUCAI) for the index patient was a score of 65 which indicate severe form of disease at diagnosis.

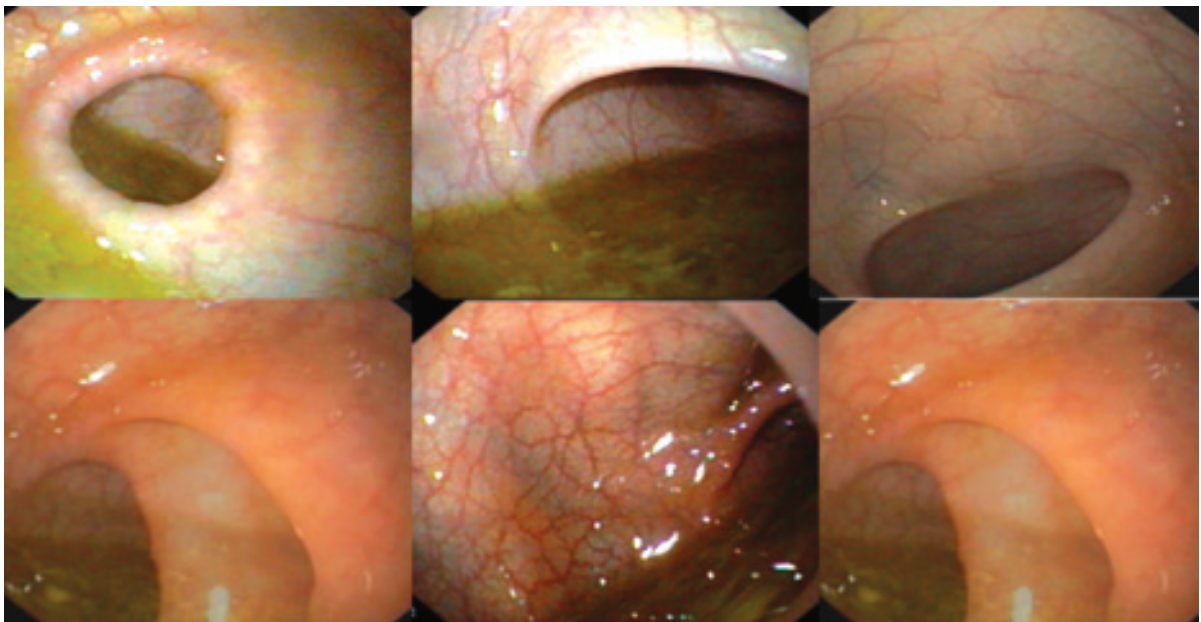
Initially she was treated symptomatically and transfused three units of blood 20ml/kg. After confirmation of diagnosis, Injection hydrocortisone and Tab. Mesalamine were started with folic acid and ranitidine. Her symptom of colitis, like frequency of motion and per rectal bleeding decreased and general wellbeing began to improve after 1 week of treatment. Subsequently she was discharged on seventh hospital day with oral prednisolone 2 mg /kg for one month thereafter 5 mg weekly reduction of dose. Tab. mesalamine 50mg/kg in three divided doses. Her bowel movement and per rectal bleeding had improved by the time of her outpatient review 2 weeks later. CBC showed marked improvement of Hb%- 11.5 and ESR – 20 mm/ 1st hr. Follow up sigmoidoscopy one month later revealed the mucosa, vascular pattern and lumen appeared normal. No active ulcer seen which was consistent with normal distal colon (UC in remission phase) (Figure 4,5). But after withdrawing steroid, 2 and half months later she had again blood mixed stool about 5 to 6 times per day. Repeat colonoscopy showed reappearance of ulcer. So, we started oral steroid, Mesalamine and Azathioprine. After withdrawal of steroid Patient was on remission with Mesalamine and Azathioprine in her outpatient review 4 weeks later. The girl is now on regular follow up.



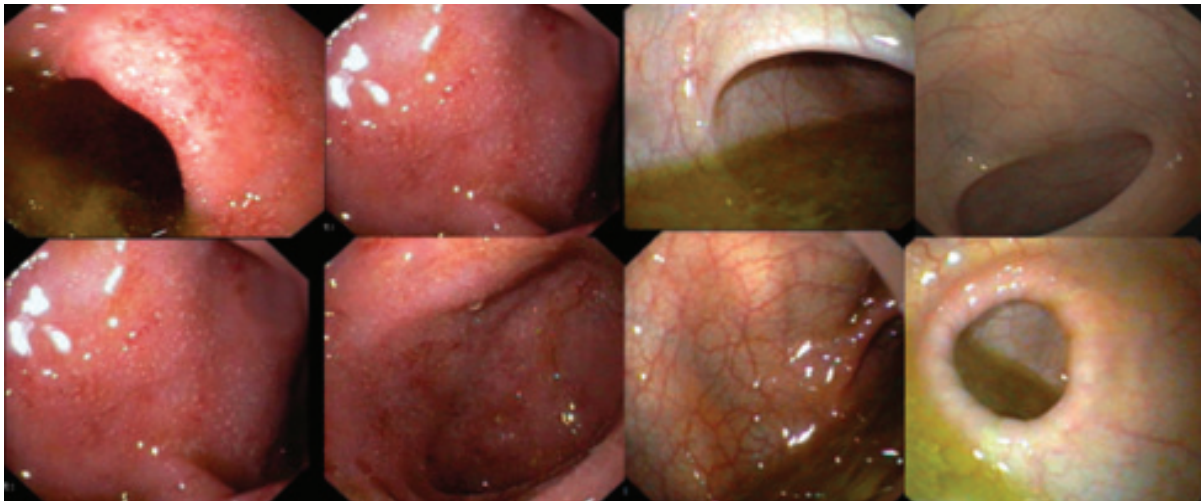
**Figure 1** Image showing colonoscopic findings of ulcerative colitis



**Figure 2 & 3** Image showing histopathological findings of ulcerative colitis.



**Figure 4** Image showing improvement of colon after treatment.



**Figure 5** Image showing comparative image of colon before and after treatment

## Discussion

UC is a multifactorial disease characterized by remission and relapse. Both genetic and environmental influences as well as abnormality in intestinal mucosal immunoregulation may play role in the pathogenesis of the disease.<sup>6</sup> The hall mark symptoms are chronicity (>2-3 weeks), abdominal cramping, diarrhea and bloody stool.<sup>6,7</sup> Mild disease is observed in 50-60% confined to the distal colon only with no systemic manifestation. Moderate disease is observed in 30% of patients with bloody diarrhea, cramps, urgency to defecate and abdominal tenderness. Associated systemic findings such as anorexia, weight loss, low grade fever and mild anemia are present. About 10% patients present with features of severe colitis such as more than six bloody stools per day, fever, weight loss, abdominal tenderness, anaemia, leucocytosis, hypoalbuminaemia. Life threatening complications like severe hemorrhage, toxic megacolon or intestinal perforation may occur in these patients.<sup>7</sup> Similarly, our patient had more than six bloody stools per day for six months, fever, weight loss, abdominal tenderness, anemia and hypoalbuminemia. But she did not have any complication. Less than 5% of children with UC present predominantly with extraintestinal manifestations that include pyoderma gangrenosum, sclerosing cholangitis, chronic active hepatitis and ankylosing spondylitis.<sup>6,7</sup>

The Pediatric Ulcerative Colitis Activity Index (PUCAI) is a validated score of clinical disease activity that does not include endoscopy or laboratory markers and is easy to perform on a daily basis. Generally, a PUCAI<10 indicates remission, 10 to 34 mild disease activity, 35 to 64 moderate, and >65 points severe. A clinically significant response is indicated by a drop in PUCAI of at least 20 points. In drug trials, the PUCAI score can be used as a noninvasive primary outcome measure that has proven to be a valid and responsive index, including high correlation with colonoscopy. Our patients PUCAI score was above 65 which indicate severe form.<sup>7-10</sup>

Before confirming the diagnosis of early-onset UC, Crohn's disease, Infective colitis (frequent), allergic colitis (frequent in young infants), vasculitis (rare), immunodeficiency states (rare) should be excluded. Our patient did not have any food allergy and gastrointestinal infections were ruled out by culture. A long list of tests can be done for the diagnosis of UC, but Kim and Ferry identified UC solely by clinical history (gastrointestinal

bleeding and abdominal pain) and routine laboratory tests, and diagnosis was confirmed by colonoscopy and biopsy. There is little benefit in adding serological testing for diagnostic purpose.<sup>11</sup> Colonoscopy of our patient showed-the mucosa of the whole colon is ulcerated and granular in appearance, contact bleeding seen and the vascular pattern is also lost throughout the length of the colon and biopsy had been taken for histopathology which revealed active colitis compatible with UC. Cryptitis, crypt abscess with foci of inflammatory cells were also found in histopathology.

A medical cure for ulcerative colitis is not available; treatment is aimed at controlling symptoms and reducing the risk of recurrence, with a secondary goal of minimizing steroid exposure. The intensity of treatment is dependent on the severity of the disease. Mild disease can be treated with aminosalicylates (5-ASA) like sulfasalazine, mesalamine. Children with moderate to severe pancolitis or colitis should be treated with 5-ASA and corticosteroids (if unresponsive to 5-ASA). Combining oral 5-ASA with topical 5-ASA is more effective than oral alone. Immunomodulators such as azathioprine or 6-mercaptopurine can be used as a steroid sparing agent. Infliximab and cyclosporine are also used in addition to above mentioned drugs in severe or fulminant colitis. With medical management, most children are in remission within 3 month; however, 5-10% continues to have symptoms unresponsive to treatment beyond 6 month.<sup>6</sup> Based on the symptoms and signs, colonoscopy and histopathology our patient was labeled as a case of severe UC and was treated initially with I/V steroid and Mesalamine.

Very few paediatric UC cases has been reported in Bangladesh. First case a 7-year-old girl was admitted in pediatric department of Dhaka Medical College Hospital<sup>12</sup> and second case a 12-years-3-month old girl was reported from Pediatrics department of Apollo Hospital<sup>13</sup> Dhaka. Both of them presented with frequent passage of slimy stool mixed with blood and diagnosed as UC. They were treated with steroid, sulfasalazine and mesalamine. Their symptoms of colitis begun to improve from the 3<sup>rd</sup> and 2<sup>nd</sup> week of treatment respectively. They were discharged with steroid, sulfasalazine and mesalamine. Their bowel movement had normalized by the time of her outpatient review at 4 weeks and 2 weeks later respectively.

Third case was a 14-month-old girl presented in Paediatric Gastroenterology and Nutrition Department of Bangabandhu Sheikh Mujib Medical University<sup>14</sup> with complaints of loose motion with bloody stool since 8 months of age. After diagnosis of UC at 14 months of age, the child was managed with dietary modification along with various antibiotics like metronidazole and ciprofloxacin, mesalamine, immunosuppressive therapy with methyl prednisolone, prednisolone and azathioprine. The child was not responding to above mentioned drugs. Treatment was discontinued due to noncompliance of the parents. Then, at 21 months of age, treatment was again started with mesalamine, methyl prednisolone, prednisolone and azathioprine at the same manner, same dose and same route. Due to failure to attain remission, cyclosporine was given orally. Finally, infliximab was added parenterally and patient gradually improved with this treatment. Patient underwent remission 14 months after starting treatment. She was maintained remission with mesalamine and azathioprine therapy.<sup>14</sup>

After reviewing the above-mentioned case reports we have found the following facts:

1. Due to lack of diagnostic expertise and still a high burden of infective diseases to battle with and the thought of UC commonly seen as a westernized illness, paediatric UC patients in Bangladesh is misdiagnosed.
2. Oral steroids are effective for inducing remission in pediatric UC. But not for maintaining remission. Oral steroids are recommended in moderate disease with systemic symptoms and selected children with severe disease without systemic symptoms, or in those failing to achieve remission with optimal 5-ASA therapy. Most of those with severe disease should be admitted for intravenous steroid therapy. Steroid dependency in children should not be tolerated; steroid-sparing strategies should be used.
3. Topical 5-ASA is not available in Bangladesh now which is a prime need to manage UC.
4. Steroid resistant cases require other modalities of therapy include 6-MC, Azathioprin, Cyclosporine, Infliximab.
5. The nutritional status and growth of children with UC must be monitored regularly. Bone mineral

status should be assessed using dual-energy x-ray absorptiometry (DEXA), particularly in children with highly active UC and who are receiving prolonged, or repeated treatment with corticosteroids.

6. Psychological intervention should be offered to patients in need because it improves quality of life, coping and depression.
7. Non-adherence to medication should be also considered in children and adolescents, particularly during unstable disease course.

Surgical treatment for intractable or fulminant colitis is total colectomy. The major complication of this operation is pouchitis which is seen in 30-40% of patients. It commonly responds to treatment with oral metronidazole or ciprofloxacin.<sup>6</sup> Probiotics may have a more important role in a patient with pouchitis.<sup>7</sup> Beyond the 1st decade of disease, the risk of development of colon cancer begins to increase rapidly. The risk of colon cancer may be diminished with surveillance colonoscopies beginning after 8-10 year of disease. Detection of significant dysplasia on biopsy would prompt colectomy.<sup>6</sup>

### Conclusion

UC should be suspected in childhood chronic bloody diarrheal diseases. If proper diagnosis, appropriate treatment with immunosuppressive therapy and careful follow can be done, a normal healthy life is achievable in this children.

**Conflict of interest:** Nothing to declare.

### References

1. Benchimol EI, Fortinsky KJ, Gozdyra P, Van den Heuvel M, Van Limbergen J, Griffiths AM. Epidemiology of pediatric inflammatory bowel disease: a systematic review of international trends. *Inflamm Bowel Dis* 2011;17:423-39.
2. Henderson P, Hansen R, Cameron FL, Gerasimidis K, Rogers P, Bisset WM et al. Rising incidence of pediatric inflammatory bowel disease in Scotland. *Inflamm Bowel Dis* 2012; 18:999-1005.
3. Heyman MB, Kirschner BS, Gold BD, Ferry G, Baldassano R, Cohen SA et al. Children with early onset inflammatory bowel disease (IBD): analysis of a pediatric IBD consortium registry. *J Pediatr* 2005;146:35-40.
4. Van Limbergen J, Russell RK, Drummond HE, Aldhous MC, Round NK, Nimmo ER et al. Definition of phenotypic characteristics of childhood-onset inflammatory bowel disease. *Gastroenterology* 2008;135:1114-22.

5. Gower-Rousseau C, Dauchet L, Vernier-Massouille G, Tilloy E, Brazier F, Merle V et al. The natural history of pediatric ulcerative colitis: a population-based cohort study. *Am J Gastroenterol* 2009;104:2080–88.
6. Grossman AB, Baldassano RN, Kligman RM, Stanton BF, Geme JWS, Nina F, Schor NF, Behrman RE, editors. *Chronic ulcerative colitis*. In *Nelson textbook of pediatrics*. 19th ed. Philadelphia: W B Saunders; 2011.
7. Kelsen JR, Cuffari C, Mamula P. Ulcerative colitis in children. [Online] 2011 Sep. [cited 2013 Feb]. Available from: URL: <http://www.eMedicine .medscape.com>
8. Turner D, Seow CH, Greenberg GR, Griffiths AM, Silverberg MS, Steinhart AH. A systematic prospective comparison of noninvasive disease activity indices in ulcerative colitis. *Clin Gastroenterol Hepatol* 2009;7:1081–8.
9. Turner D, Otley AR, Mack D, Hyams J, de Bruijne J, Uusoue K et al. Development, validation, and evaluation of a Pediatric Ulcerative Colitis Activity Index: a prospective multicenter study. *Gastroenterology* 2007;133:423–32.
10. Turner D, Hyams J, Markowitz J, Lerer T, Mack DR, Evans J et al. Appraisal of the Pediatric Ulcerative Colitis Activity Index (PUCAI). *Inflamm Bowel Dis* 2009;15:1218–23.
11. Kim SC, Ferry GD. Inflammatory bowel disease in pediatric and adolescent patients: Clinical, therapeutic and psychosocial considerations. *Gastroenterology* 2004;126:1550–60.
12. Hassan T, Afroze F, Mollah MAH, Saha N, Parveen R, Rahman A et al. A Child with Ulcerative Colitis - A Case Report. *Bangladesh Coll Phys Surg* 2010;28: 117-120.
13. Nahar N, Sultana S, Chowdhury MLL, Chowdhury K. A Girl with Ulcerative Colitis in a Tertiary Care Hospital- A Case Report. *Pulse Volume* 2013; 6 (1 & 2).
14. Rukunuzzaman M, Karim ASMB. Ulcerative Colitis in Infancy. *Saudi J Gastroenterol* 2011; 17: 414–17.