

Medical quiz: image 1

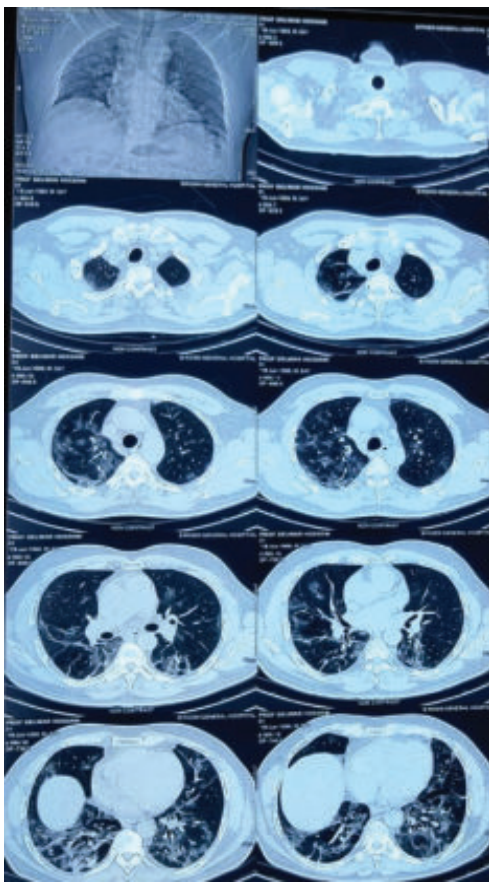
(BIDEM Med J 2020; 10(3): 218)

Haque HF^a, Afroz F^b, Ahmed AKMS^c

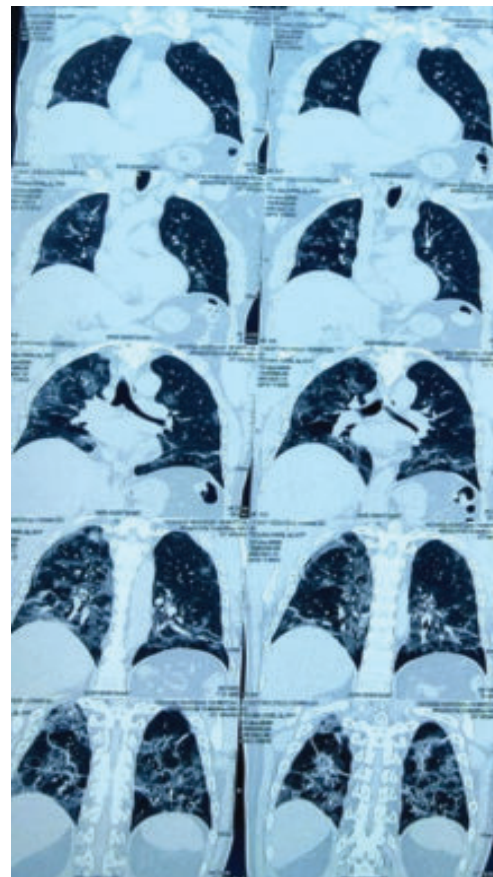
A 56-year-old gentleman got admitted with the complaints of fever, cough and breathlessness for 11 days. He had no previous history of cough or breathlessness. Photograph of high resolution computed tomography (HRCT) scan of his chest is provided (Figures 1a & 1b).

Questions

1. Mention abnormal findings on HRCT scan of the chest?
2. What is the likely diagnosis?
3. What are the other possibilities?
4. What further investigations you want to do to establish the diagnosis?



1(a)



1(b)

Figure 1 HRCT chest (a) axial and (b) coronal films

Author information

- a. Hasna Fahmima Haque, Assistant Professor, Internal Medicine, BIRDEM General Hospital, Dhaka, Bangladesh.
- b. Farhana Afroz, Assistant Professor, Respiratory Medicine, BIRDEM General Hospital, Dhaka, Bangladesh.
- c. AKM Shaheen Ahmed, Professor, Internal Medicine, BIRDEM General Hospital, Dhaka, Bangladesh.

Address of correspondence: Hasna Fahmima Haque, Assistant Professor, Internal Medicine, BIRDEM General Hospital, Dhaka, Bangladesh.
Email: drfahmimahaque@gmail.com