

Rhino- Orbito- Cerebral - Mucormycosis with Osteomyelitis in a Patient with Diabetes mellitus: A Case Report and Literature Review

HABIB R^a, ISLAM R^b, RAHMAN A^c, BHOWMIK NB^d, HAQUE MA^e

Abstract:

Mucormycosis is a form of fulminant invasive fungal infection of the sinonasal tract that often extends to the orbit, brain, palate, and skin. It is caused by members of the order Mucorales, and it is considered to be the most fatal fungal infection known to man. It is most commonly associated with diabetic ketoacidosis, hematologic malignancies, acquired immunodeficiency syndrome acquired immunodeficiency syndrome, see AIDS., and immunosuppressive therapy. This rare opportunistic infection exists in many forms, the most

common of which is rhinocerebral mucormycosis. Treatment includes aggressive surgical debridement of the necrotic tissue combined with systemic antifungal therapy. In this case report, we describe the successful management of rhinoorbitocerebral mucormycosis, a subtype of the rhinocerebral variety, complicated by osteomyelitis of cranium. We review the diagnostic work-up and discuss the literature with respect to the presentation, pathophysiology, management, and outcome of the disease.

(Birdem Med J 2012; 2(2):124-127)

Introduction

Mucormycosis is a rapidly progressive fungal infection that usually develops in patients who are metabolically or immunologically compromised. Left untreated, it is rapidly fatal. Thereby Mucormycosis has earned its designation as the most acutely fatal fungal infection known to man.¹

Saprophytes (band), a Lithuanian gothic/deat MMucormycosis is caused by Saprophytic aerobic fungi

- Dr. Rumana Habib ,Registrar, Dept of Neurology, Ibrahim Medical college and BIRDEM General Hospital, Shahbag,Dhaka-1000,Bangladesh
- Dr. Rashedul Islam Medical officer , Neurology, Ibrahim Medical college and BIRDEM General Hospital, Shahbag,Dhaka-1000,Bangladesh
- Dr. Aminur Rahman ,Assistant Professor, Dept of Neurology, Ibrahim Medical college and BIRDEM General Hospital, Shahbag,Dhaka-1000,Bangladesh
- Dr. N.B.Bhowmik, Associate Professor, Dept of Neurology, Ibrahim Medical college and BIRDEM General Hospital, Shahbag,Dhaka-1000,Bangladesh
- Dr. Amirul Haque, Professor and Head, Dept of Neurology, Ibrahim Medical college and BIRDEM General Hospital, Shahbag,Dhaka-1000,Bangladesh.

Address of correspondence: Dr. Rumana Habib ,FCPS (Medicine) -Registrar,Dept of Neurology, Ibrahim Medical college and BIRDEM General Hospital, Shahbag,Dhaka-1000, e-mail: doctorhrumana@rocketmail.com

Received: 13 December, 2011

Accepted: 21 June, 2012

of the Phycomycetes class (order Mucorales) .² Saprotrroph, a term used for organisms which obtain nutrients from dead organic matter (this term commonly applies to fungi).

These saprophytes are commonly found in soil, decomposed vegetation, and in the healthy human respiratory and digestive tracts, and their distribution is worldwide.

Mucormycosis can manifest as one of six different clinical syndromes; it appears in rhinocerebral, pulmonary, gastrointestinal, central nervous system, subcutaneous, and disseminated forms. Rhinocerebral mucormycosis (RCM) is the most common of these forms, and it is subdivided into three subtypes: rhinomaxillary, rhinoorbital, and rhinoorbitocerebral.³.

In most cases of RCM, the fungi gain entry to the body via inhalation of airborne spores through the sinuses. It has been postulated that the most common reservoir for organisms is the pterygopalatine fossa. RCM begins with colonization of the nasal mucosa by airborne spores. In normal hosts, a phagocytic response to colonization prevents infection. In immunocompromised hosts, on the other hand, the response is suboptimal and germination ensues.⁴.Infection spreads along vascular and neuronal structures and infiltrates the walls of blood vessels. . Angioinvasion by the hyphae produces a fibrin reaction and the development of “mucor thrombi”

which occlude the arteries and lead to ischemia, infarction, and consequent formation of the black necrotic eschar of the skin and mucosa that is characteristic of RCM. Vascular occlusion prevents systemic antifungal agents from reaching their targets, and ischemia favors the development of acidotic tissue, which is ideal for fungal growth.⁵ As the infection spreads it can erode bone through walls of the sinus and can spread into the orbit and the retro-orbital area, thereby extending into the brain.

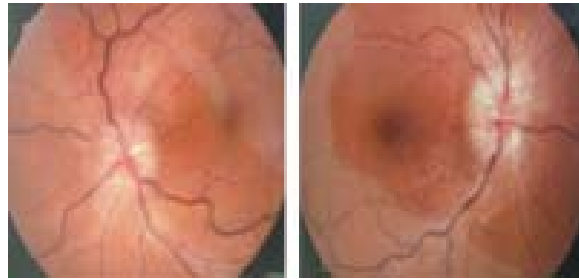
Infection originating in the nose and paranasal sinuses may lead to blindness due to fungal invasion of the globe or ophthalmic artery, Cavernous sinus thrombosis, and Coma due to direct invasion of the frontal lobe⁶. Without treatment, the patient may die within a few days to a few weeks. Patients who survive rhinocerebral mucormycosis are often left with severe facial disfigurement and usually require plastic surgery to restore their appearance..

We report a case of Rhino-cerebral Mucormycosis complicated by skull osteomyelitis, a rather unusual outcome because of the angioinvasive nature of the fungus.

Case report:

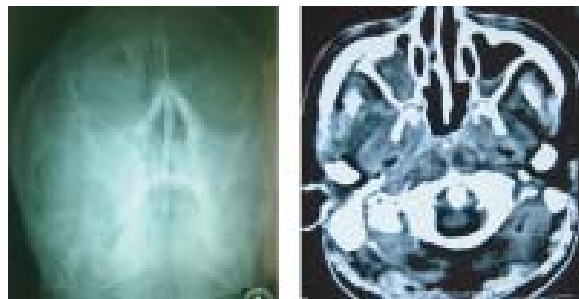
A 25 year old diabetic patient presented with the complaints of mild, continuous, global headache for 3 months which worsened on bending forward and straining and was not relieved by analgesics. This was followed by gradual swelling and numbness of face on right side. The Patient also complained of progressive dysphagia to liquid for the last two months. He also had low grade continued fever ten days prior to admission. He did not give any h/o diplopia, vomiting, blurring of vision, convulsion or loss of consciousness. There was no h/o cough, weight loss, bladder and bowel disturbances. He was a non smoker had no H/O exposure, abuse of alcohol. Before coming to Dhaka he was working as a farmer at KSA.

On examination patient was ill looking, mildly anaemic, temp 100°F with facial puffiness, periorbital swelling and mild bilateral proptosis of eyes along with swelling & tenderness over right maxillary region. Neurological examination revealed slurred speech, bilateral papilloedema, fifth nerve palsy on right side, bilateral VI, VII, IX & X cranial nerve palsy.



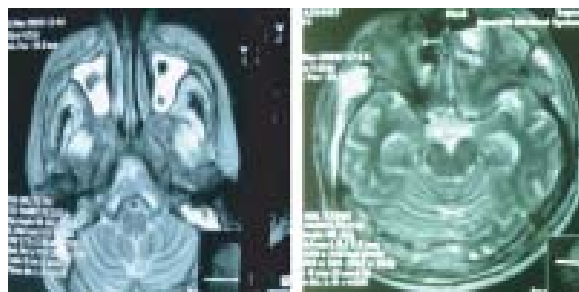Investigations: Hb: 9.1g/dl. ESR: 135mm in 1st hr TC WBC: 15,500/cmm. DC: P-72%,L-26%,M-02%,E-01%. Platelet-1,50,000/cumm PBF: Normocytic normochromic anaemia with neutrophilic leucocytosis..Blood Sugar Profile: F:9.1mmol/l ABF: 12.8mmol/l, AL: 10.8mmol/l, AD: 12.7mmol. HbA1C: 9.7%. Blood C/S –No growth. Urine R/M/E and C/S - No growth.RFT and LFT are normal.

X-ray PNS O/M view-Bilateral maxillary sinusitis. CT scan of brain : Mucosal thickening noted on both maxillary sinus suggestive of chronic maxillary sinusitis



X ray PNS

CT Scan of brain



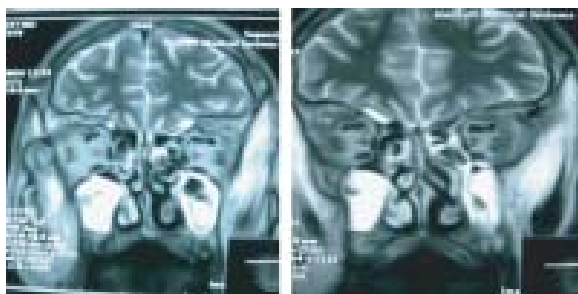
MRI of Brain

MRI of Brain

MRI of Brain and paranasal sinuses : Soft tissue signal intensity in Both Maxillary, Sphenoid & Ethmoidal sinuses. Suggestive of- Chronic Infection/ Myelomatous Deposit

MRI of Orbit : Diffuse marrow inhomogeneity in cranial & orbital bones; suggestive of- Myeloproliferative disorder/ Lymphoproliferative disorder. Enlargement of lateral Recti, left Lacrimal gland & soft tissue thickening of left orbit with Multiple lytic lesion suggestive of-

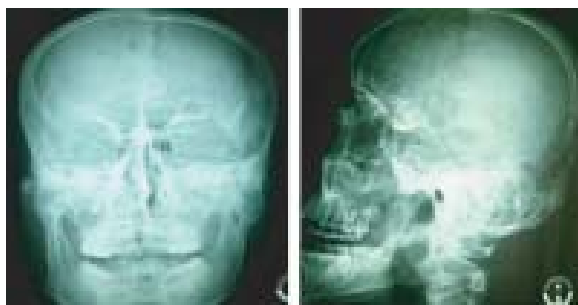
Multiple Myeloma / Histiocytosis x



MRI of Orbit

MRI of Orbit

X-Ray Skull showed multiple lytic lesions and Immunoelectrophoresis: Normal



X-Ray Skull AP and Lateral view

His Anti HIV Antibody was Negative

General care included adequate hydration and nutrition, insulin, Meropenem, Metronidazole, Paracetamol and Proton pump Inhibitor was given. Endoscopic debridement of Para nasal sinuses under G/A was done by ENT Specialist. Fungal ball was found in Para nasal sinuses, sample was taken and sent for microscopy and histopathology.

Histopathological study of biopsy specimen (Tissue from right Maxilla & Ethmoid sinuses) revealed entangled fungal organisms exhibiting broad long nonseptate hyphae with irregular branching. In some foci colony of fungus is seen invading tissue fragment.

Diagnosis: Inflammatory tissue with fungus, suggestive of mucor.



Finally we diagnosed the case as Rhino- Orbito-Cerebral- Mucormycosis with Diabetes mellitus

We treated the patient with Inj. Amphotericin- B, Cap. Fluconazole, Tab. Ibuprofen. The patient complained of severe headache with high grade fever. Follow-up CT Scan of Brain showed Pan sinusitis with destruction of calvarial bones & adjacent soft tissue swelling, may be consistent with invasive fungus. Debridement was repeated and Ciprofloxacin and Flucloxacillin was added to the ongoing treatment. The patient responded well and was discharged after a week on 29.12.2009.

Discussion:

Upper airway mucormycosis was first described in 1885 by Paltauf, who called it mycosis mycosis: see fungal infection. mucorina.⁷ In 1943, Gregory et al reported the more typical findings of advanced RCM in 3 patients with fatal diabetic ketoacidosis. Cure of the disease was first reported in 1955 by Harris.

Mucormycosis refers to any fungal infection of the order Mucorales. Although the responsible fungus can be isolated in the nose of healthy subjects, it can turn pathogenic in patients with immunologic or metabolic compromise. Among the recognizable risk factors for the development of RCM are Diabetes mellitus, especially when poorly controlled.

R. oryzae is the predominant pathogen, accounting for 60% of all forms of mucormycosis and 90% of all cases of RCM.⁸ Regardless of the causative agent, the clinical presentation and management are the same. Our patient was diabetic and mycologic evaluation of the infected tissue specimen in our patient revealed the growth of Mucor.

Solid organ (eg, liver, kidney) and bone marrow transplantation, Iron overload syndromes, particularly those associated with hemodialysis, Long-term therapy with deferoxamine, Uremia, Severe malnutrition, Diarrheal diseases, AIDS, Trauma or burns. Blood dyscrasias

:Leukemia: Lymphoma .Prolonged neutropenia ,Graft versus host disease (GVHD)are common predisposing factors⁷. Our case suffered from no such clinical conditions.

Fever is the most common early symptom (44% of cases), followed by nasal ulceration or necrosis, periorbital or facial swelling, and decreased vision, each of which occurs in approximately 33% of cases. . Ultimately, 80% of patients develop a necrotic lesion on either the nasal or oral mucosa.) When the clinical picture includes the presence of sinusitis with black discoloration in the nose and palate in addition to a predisposing factor, a diagnosis of RCM should be highly suspected .Other less frequent features include facial pain or numbness, nasal congestion or discharge, headache, ophthalmoplegia, anesthesia over the cheek, and cranialpolyneuropathy, which may be consistent with orbital apex syndrome. ¹³.

A black eschar of the nasal mucosa or palate usually is a hallmark sign of rhinocerebral mucormycosis. It is a sign of deep infection and tissue destruction of the nasal mucosa. This finding on physical examination should prompt biopsy and empiric treatment. ¹⁴.

In our patient,presentation was with headache and right sided facial numbness followed by fever and dysphagia .On, examination,he had bilateral proptosis ,bilateral papillodema and bulbar weakness.The orbital manifestation preceeded intracranial spread; hence: Rhino- Orbito- Cerebral- Mucormycosis, was the most acceptable terminology.

Our patient later complained of severe headache with high grade fever complicated with a bony erosion. This sort of bony involvement is uncommon because of the angioinvasive nature of the fungus, and bone lesions are usually adjacent to other forms of mucormycosis. It has been described at the base of the cranium¹⁵, in the bones of the feet and hands ^[16-18], and in the humerus ¹⁹, tibia ^[20], femur ^[21] and vertebrae ^[22].

Definitive diagnosis requires identification of the fungus histologically in tissue specimens or recovery of the fungus by culture. ²⁴ In our patient, PAS staining readily demonstrated the fungus (Mucor) in tissue taken from right Maxillary and ethmoid sinuses.

Radiographic findings are helpful in assessing the different stages of the disease rather than in making a

definitive diagnosis because the radiographic features may be indistinguishable from those of simple rhinosinusitis.²⁵In rhino-orbital-cerebral mucormycosis, CT generally shows evidence of paranasal sinus involvement manifested as mucosal thickening without air-fluid levels of several sinuses, primarily in the ethmoid and sphenoid sinuses, but with a clear unilateral predilection .²⁶. Evidence of bone destruction on CT is a late finding, and usually is absent despite deep extension of disease beyond the bony confines of the paranasal sinus .

Because of the rapidity with which this disease progresses, prompt and aggressive therapy is essential ²⁸ Three factors are key to a successful outcome of therapy for mucormycosis²⁹

1.Reversal of the underlying predisposition, 2. Aggressive surgical debridement, 3.Aggressive antifungal therapy, with early initiation and high drug doses.

Antifungal therapy alone or surgical therapy alone is ineffective The standard medical therapy for RCM is amphotericin B in a dose of 1.0 to 1.5 mg/kg/day should be continued for at least 3 months after: all clinical abnormalities resolve or stabilize, leaving no clinical evidence of infection at the involved site(s). Since the introduction of combined therapy with amphotericin B and surgery, more than 80% of the patients can be expected to survive ³¹

Recent data support the concept that high-dosliposomal amphotericin is the preferred monotherapy for mucormycosis as this formulation maximizes the amount of amphotericin B delivered to tissues as well as the speed of drug delivery and Nephrotoxicity occurs in < 50% of patients. So, Higher doses of liposomal amphotericin may be well-tolerated.³²

We treated our patient with Inj. Amphotericin- B, Cap. Fluconazole , and surgical debridement with some supportive therapy . The patient improved clinically his temperature subsided , puffiness of face and periorbital swelling reduced. We advised continuation of Amphotericin B up to 2 gm & Fluconazole for 3 month and discharged the patient .

Conclusion :

Mucormycosis has a fulminantly fatal clinical pattern. We were able to modify the prognosis of our patient

with rapid diagnosis, early and aggressive management including combined antifungal and surgical interventions, and reversal of underlying risk factors. In all cases a high index of sus

References:

1. Hendrickson RG, Olshaker J, Duckett O. Rhinocerebral mucormycosis: A case of a rare, but deadly disease. *J Emerg Med* 1999;17: 641-5.
- 2.. Rippon JW. Mucormycosis. In: Medical Mycology. The Pathogenic Fungi and the Pathogenic Actinomycetes. 2nd ed. Philadelphia: W.B. Saunders, 1982:615-40.
- 3.. Rhinocerebral Mucormycosis Author: William P Baugh, MD; Chief Editor: Burke A Cunha, MD more...
4. Maniglia AJ, Mintz DH, Novak S. Cephalic phycomycosis: a report of eight cases. *Laryngoscope* 1982;92:755-60.
5. Ferguson BJ. Mucormycosis of the nose and paranasal sinuses. *Otolaryngol Clin North Am* 2000;33:349-65.
6. Roden MM et al: Epidemiology and outcome of zygomycosis: a review of 929 reported cases. *Clin Infect Dis* 41:634, 2005
7. Paltauf A. Mycosis mucorina. *Virchows Arch Pathol Anat* 1885; 102: 543-64.
8. Mancare MY. Mucormycosis. www.emedicine.com/ped/topic1488.htm.
9. Chayakulkeeree M, Ghannoum MA, Perfect JR: Zygomycosis: the re-emerging fungal infection. *Eur J Clin Microbiol Infect Dis* 25:215, 2006 [PMID:16568297]
10. Jenson HB (eds). Nelson Textbook of pediatrics, 17th ed. Philadelphia: W.B. Saunders. 2004; pp.1025-26.
11. Prabhu RM et al: Mucormycosis and entomophthoromycosis: A review of the clinical manifestations, diagnosis and treatment. *Clin Microbiol Infect* 10(Suppl 1):31, 2004
12. .Andresen D et al: Multifocal cutaneous mucormycosis complicating polymicrobial wound infections in a tsunami survivor from Sri Lanka. *Lancet* 365:876, 2005 Mar 5-11 [PMID:15752532]
13. Chan LL, Singh S, Jones D, Diaz EM Jr, Ginsberg LE. Imaging of mucormycosis skull base osteomyelitis. *AJNR Am J Neuroradiol* 2000; 21: 828-831.
14. Stevanovic MV, Mirzayan R, Holtom PD, Schnell SB. Mucormycosis osteomyelitis in the hand. *Orthopedics* 1999; 22: 449-450
- 15.. Shaw CJ, Thomason AJ, Spencer JD. Fungal osteomyelitis of the foot. A report of an unusual case. *J Bone Joint Surg Br* 1994; 76:137-139.
16. Chaudhuri R, McKeown B, Harrington D, Hay RJ, Bingham JB, Spencer JD. Mucormycosis osteomyelitis causing avascular necrosis of the cuboid bone: MR imaging findings. *AJR Am J Roentgenol* 1992; 159: 1035-1037.
17. Meis JF, Kullberg BJ, Pruszczyński M, Veth RP. Severe osteomyelitis due to the zygomycete *Apophysomyces elegans*. *J Clin Microbiol* 1994; 32: 3078-3081.
18. Pierce PF, Wood MB, Roberts GD, Fitzgerald RH Jr, Robertson C, Edson RS. *Saksenaeva vasiformis* osteomyelitis. *J Clin Microbiol* 1987; 25: 933-935.
19. Echols RM, Selinger DS, Hallowell C, Goodwin JS, Duncan MH, Cushing AH. *Rhizopus* osteomyelitis. A case report and review. *Am J Med* 1979; 66: 141-145.
20. Buruma OJ, Craane H, Kunst MW. Vertebral osteomyelitis and epidural abscess due to mucormycosis, a case report. *Clin Neurol Neurosurg* 1979; 81: 39-44.
21. Mostaza JM, Barbado FJ, Fernandez-Martin J, Pena-Yanez J, Vazquez-Rodriguez JJ. Cutaneoarticular mucormycosis due to *Cunninghamella bertholletiae* in a patient with AIDS. *Rev Infect Dis* 1989; 11: 316-318.
22. Imaging of Mucormycosis Skull Base Osteomyelitis. Ling-Ling Chan^a, Sanjay Singh^a, Dan Jones^a, Eduardo M. Diaz Jr.^a and Lawrence E. Ginsberg^{aa} From the Departments of Diagnostic Radiology (L-L.C., S.S., L.E.G.), Pathology (D.J.) and Head and Neck Surgery (E.M.D.), the University of Texas M.D. Anderson Cancer Center, Houston, Texas
23. Schell WA. Histopathology of fungal rhinosinusitis. *Otolaryngol Clin North Am* 2000;33:251-76.
24. Greenberg MR, Lippman SM, Grinnell VS, Colman MF, Edwards JE Jr. Computed tomographic findings in orbital mucor. *West J Med* 1985; 143:102-103
25. Gamba JL, Woodruff WW, Djang WT, Yeates AE. Craniofacial mucormycosis: Assessment with CT. *Radiology* 1986; 160:207-212
26. Kilpatrick C, Tress B, King J. Computed tomography of rhinocerebral mucormycosis. *Neuroradiology* 1984; 26:71-73
- 27.. Parfrey NA: Improved diagnosis and prognosis of mucormycosis. *Medicine* 1986, 65:113-123
28. Ericsson M, Anniko M, Gustafsson H, et al.: A case of chronic progressive rhinocerebral mucormycosis treated with liposomal amphotericin B and surgery. *Clin Infect Dis* 1993, 16:585-586.
29. Gallis HA, Drew RH, Pickard WW: Amphotericin B: 30 years of clinical experience. *Rev Infect Dis* 1990, 12:308-329.
30. Kofteridis DP, Karabekios S, Panagiotides JG, et al. Successful treatment of rhinocerebral mucormycosis with liposomal amphotericin B and surgery in two diabetic patients with renal dysfunction. *J Chemother* 2003; 15:282-6.
- 31.. R hurchill RB, Aronoff SC. Zygomycosis. In: Behrman RE, Kliegman RM, Jenson HB (eds). Nelson Textbook of pediatrics, 17th ed. Philadelphia: W.B. Saunders. 2004; pp.1025-26.
32. Greenberg RN et al: Posaconazole as salvage therapy for zygomycosis. *Antimicrob Agents Chemother* 50: 126, 2006
- 33.. Kajs-Wyllie M. Hyperbaric oxygen therapy for rhinocerebral fungal infection. *J Neurosci Nurs* 1995;27:174-81.
34. Centeno RS, Bentson JR, Mancuso AA. CT scanning in rhinocerebral mucormycosis and aspergillosis. *Radiology* 1981; 140:383-389.