

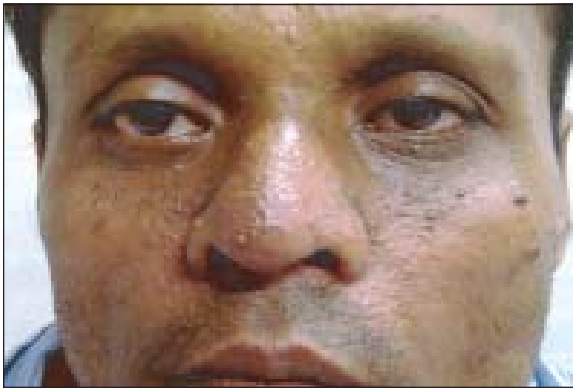
IMAGES IN MEDICAL PRACTICE

(Birdem Med J 2011; 1(1): 54)

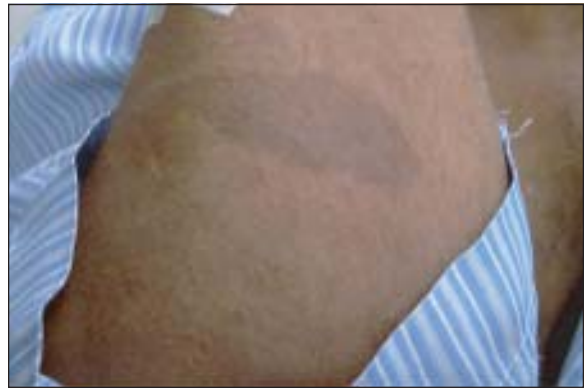Quiz: Images in Medical Practice

Courtesy: Safder AMB

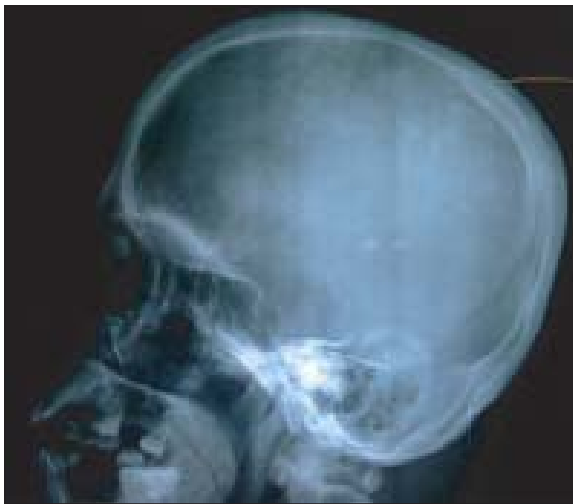A 43 years old male presented with recurrent convulsion. He had some papular lesion on the face & hand and patch on the forearm; the images of which are given below. A skull x-ray and CT scan of brain was done.



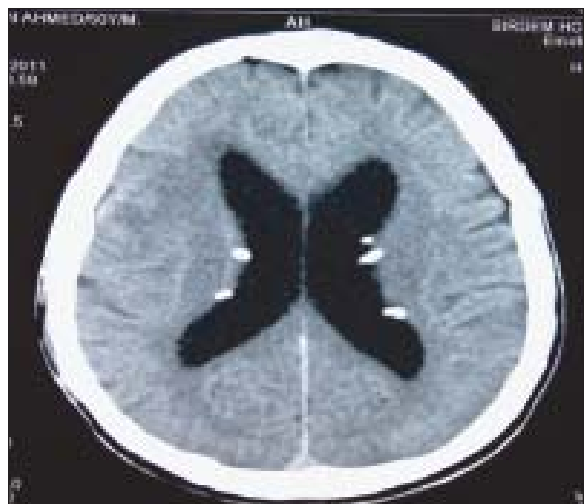Papular lesion on face



Patch on forearm



X-ray skull (Lateral view)



CT scan of Brain

Q. What is the likely diagnosis?