

Gastro Intestinal Stromal Tumor : A Case Report

MAITRA TK^a, ROY S^b, MONDAL SK^c, ALAM NA^d

Abstract

Gastro Intestinal Stromal Tumor (GIST) are a type of neoplasm arising from the embryological mesoderm of Gastrointestinal Tract. But they can also arise from extra intestinal sites. The incidence¹ of site of origin of GIST is - Oesophagus 5% Stomach 50% Small intestine 25% Colon & rectum 10%, Extr-intestinal (Mesenchyme,

GB,Pancreas) 10%. We present here a case of GIST attaining enormous size, having all classical histological features of GIST arising from the mesentery which is a relatively rare site.

Key words: Gastro Intestinal Stromal Tumor, Mesenchyme.

(Birdem Med J 2013; 3(1):47-49)

Introduction

Originally GISTs were leveled as smooth muscle tumor, but mesenchymal tumors of gut are of distinct biological entity as they have morphological & immuno-histochemical features dissimilar to smooth muscle¹. The definite feature of most GIST is their positive immuno-histochemical staining for the receptor tyrosine kinase, KIT. KIT is expressed in number of cell types, but KIT mutation occurring in Interstitial Cells of Cajal (ICC) – the unique pacemaker cells that control peristalsis in gut, have been shown to lead to GIST formation. Recent evidences suggest there are Interstitial Cajal like cells in extra-intestinal sites & there are the presumed cells of origin for extra-intestinal GIST².

Case Report

Mr Y, 65 year old diabetic male, from Uttara, Dhaka was admitted in Birdem with complaints of a gradually increasing swelling in the lower abdomen for 2 years which was rapidly increasing in size for last 3 months. Swelling was associated with occasional pain. There was no fever, vomiting, changes in bowel habit or significant weight loss, also no H/O cough,

haemoptysis, jaundice or any bone pain. On examination, his all general & vital parameters were normal. On abdominal examination, there was an elliptical, non-tender, firm lump in the abdomen measuring about (14 × 7) cm (Fig.-1). The overlying skin & underlying structures were free, margins were well defined, surface was irregular. The swelling was mobile in all direction & did not move with respiration.

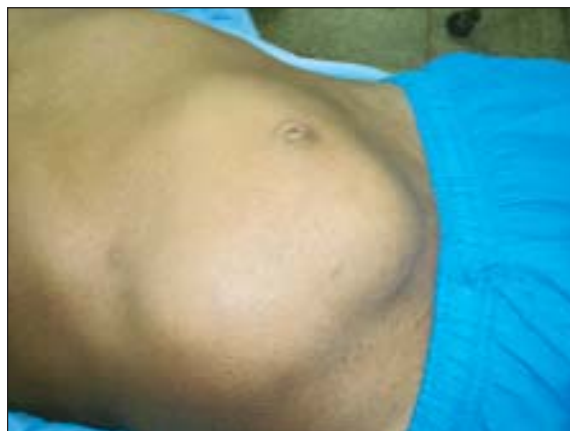

Fig.-1: Before operation

- Dr. Tapash Kumar Maitra, Associate Professor of Surgery, BIRDEM, Dhaka
- Dr. Sharmistha Roy, Assistant Professor of Surgery, BIRDEM, Dhaka
- Dr. Samiron Kumar Mondal, Assistant Professor of Surgery, BIRDEM, Dhaka
- Dr. Noor -A-Alam, Associate Professor of Surgery, BIRDEM, Dhaka

Address of Correspondence: Dr. Tapash Kumar Maitra, Associate Professor of Surgery, BIRDEM, Dhaka, E-mail: tapashkm1965@gmail.com

Received: 16 January 2012 **Accepted:** 12 October, 2012

Head rising test was negative. There was no organomegaly, or ascites, digital rectal examination findings were normal. Haematological & biochemical parameters were within normal range. The impression on Ultrasound of whole abdomen was intra abdominal mixed density mass of mesenchymal origin. CT scan showed (Fig 2) Large (12 × 9) cm solid abdominal mass with multiple smaller lobulated abdominal mass in mid abdomen with few focal calcification within it which may suggest (?) mesenchymal & neurogenic tumor.

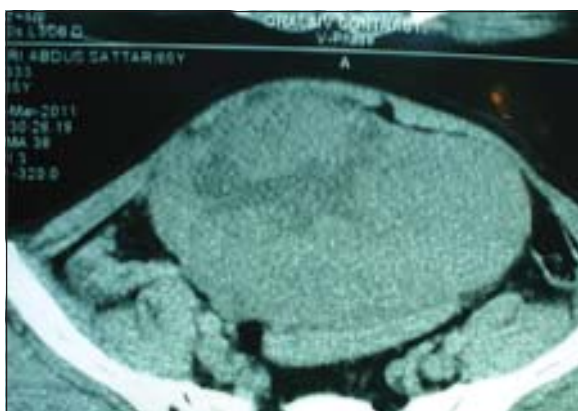

Fig.-2: CT Scan of abdomen

Abdomen was opened by midline incision. The lump was delivered through the wound (Fig 3). It was a large multiloculated solid tumour in between the two leafs of the mesentery & also adherent to the mesenteric border

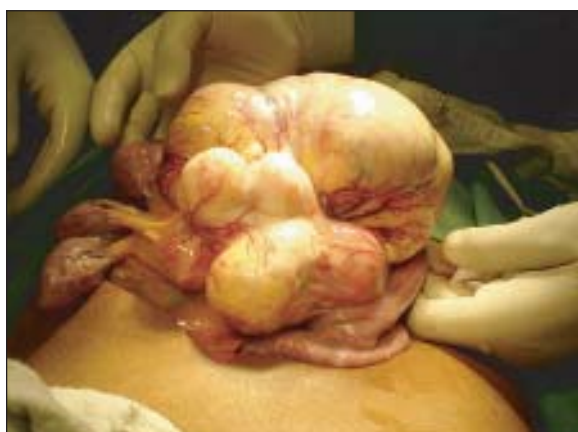

Fig.-3: Per operative view

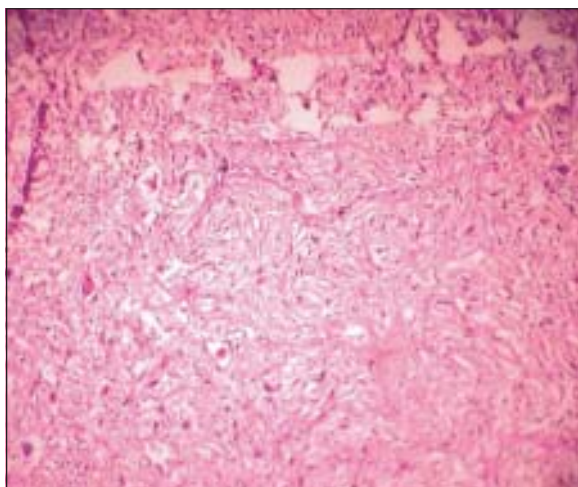


Fig.-4: Histopathology

of part of ileum, having some common blood supply. Lymph nodes were not enlarged. No hepatic metastases & ascites was seen. We removed the tumor in toto, with the affected part of ileum & mesentery followed by maintenance of the continuity of gut. Histopathology report revealed Gastro intestinal stromal tumor(Fig 4) . Mitotic figure were rarely found, No malignancy was seen. He was discharged on 7th POD with advice to attend Surgical OPD For regular follow up.

Discussion

GISTs are uncommon, comprising of only 1-3% of all gastrointestinal neoplasia³. However they are the most common mesenchymal tumors of the gut.⁴ Half of the patients with GIST have metastatic tumor at presentation. Metastasis occurs to liver or peritoneum. Lymph node involvement & extra abdominal extension are very rare (<1%). Median tumor size at presentation is 5 cm⁵. Macroscopically they are non encapsulated & show cystic degeneration, necrosis or hemorrhage. Histologically there are three subtypes depending on predominating cell type : spindle shaped (70%), epithelioid (20%) & combination of two (10%)⁶. Contrast enhanced CT is the imaging modality of choice. On contrast CT, GIST have a characteristic heterogeneous appearance with central necrosis & cystic degeneration, which is similar to our case. Endoscopic USG may be suitable alternative for small tumors. MRI is the modality of choice in rectal GIST.

Treatment: Surgery is the treatment of choice in operable GIST. A GIST is suggested at laparotomy by a large mass without obvious lymph node involvement. This was also very similar to our finding at laparotomy. Recent advances in non-surgical management of GIST have improved outcome for locally advanced & metastatic diseases. On going investigation is aiming at determination of benefit of adjuvant therapy in resectable disease .

Metastatic disease GISTs are not sensitive to conventional chemo or radiotherapy⁷ & median survival of irresectable disease is 20 months⁸. Recently selective tyrosine kinase inhibitor Imatinib Mesylate has been shown to be effective .Imatinib in resectable large tumor may result in tumor shrinkage⁶.

Size of tumor is a major determinant of the malignant potential in case of GIST .In our case though the tumor was considerably large in size(12x9cm), there was no

evidence of metastasis to the liver or peritoneum & on histopathology no mitotic figure was found, so we treated the patient as a benign one and did not give any adjuvant therapy. Yet still keeping the size of the tumor in mind and its chance of recurrence we counseled the patient accordingly and kept him under follow up.

Prognosis 5 years survival following a complete resection of a localized GIST is 48-70% and in case of incomplete resection 8-9%. Recurrence after complete removal of localized disease is 40-80%. Long term studies suggest up to 90% patient develop a recurrence or die from their disease.

Conclusion

As there is a quite high chance of recurrence (48-70%) even after complete removal of tumor, once the diagnosis of GIST is confirmed on histopathology, all patients should be counseled accordingly & kept under follow up. Role of adjuvant therapy to decrease recurrence should be evaluated.

References:

1. Rubin BP. Gastro Intestinal Stromal Tumors, an update. *Histopathology* 2006; 48: 83-96.
2. Min KW, Leabu M. Interstitial cells of Cajal (ICC) and gastrointestinal stromal tumor (GIST): facts, speculations, and myths. *J Cell Mol Med* 2006; 10: 995-1013.
3. Rossi CR, Mocellin S, Mencarelli R et al. Gastrointestinal stromal tumors: from a surgical to a molecular approach. *Int J of Cancer* 2003; 107: 171-76.
4. DeMatteo RP, Lewis jj, Leung D et al. Two hundred gastrointestinal stromal tumor: Recurrence pattern and prognostic factors for survival. *Ann Surg* 2000; 231:51-58.
5. Hasegawa T, Matsuno Y, Shimoda T, Hirohasi S. gastrointestinal stromal tumor: consistent CD117 immunostaining for diagnosis, and prognostic classification based on tumor size and MIB-1 grade. *Hum Patho* 2002; 33: 669-76.
6. Blay JY, Bonvalot S, Casali P et al. Consensus meeting for management of gastrointestinal stromal tumors. Report of the GIST consensus conference of 20-20; March 2004, under the auspices of ESMO. *Ann Oncol* 2005; 16:566-78.
7. Demitri GD. Identification & treatment of chemo resistant inoperable or metastatic GIST: experience with selective tyrosine kinase inhibitor Imatinib Mesylate (ST1571). *Euro J Cancer* 2002; 38 (suppl 5): 552-59.
8. Graddt Van Roggen JF, van Velthuysen ML, Hogendoorn PC. The histopathological differential diagnosis of gastrointestinal stromal tumors. *Clin Pathol* 2001; 54: 96-102.