

MEDICAL QUIZ

Medical Quiz: Images

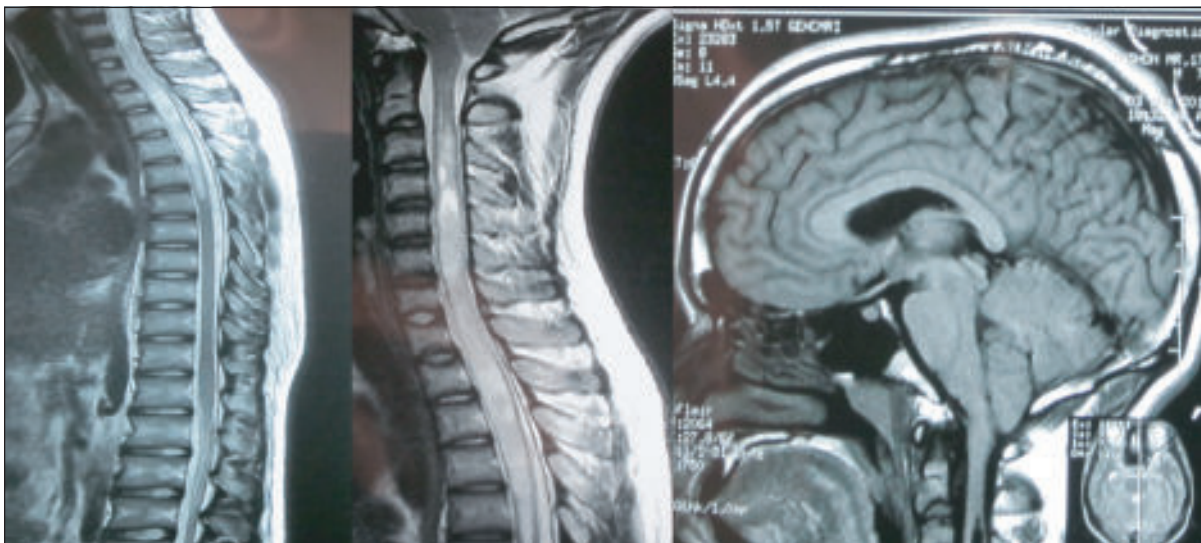
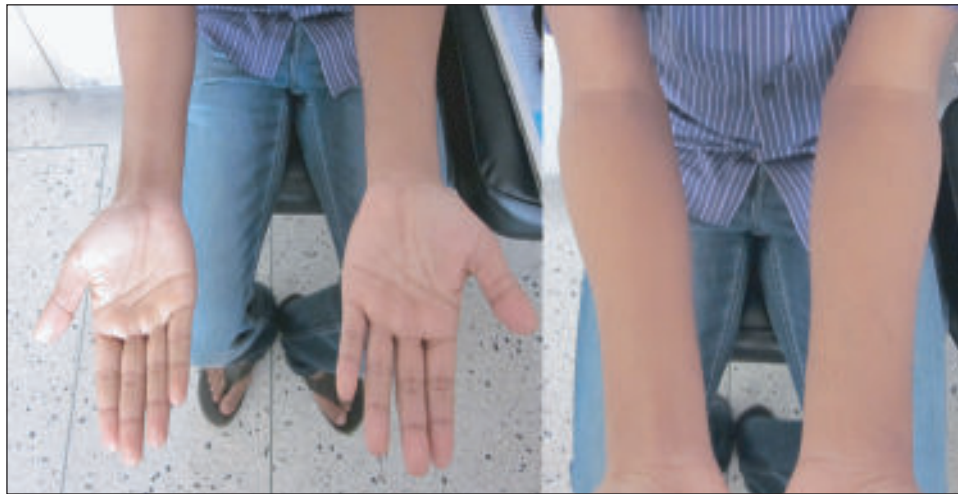(*BirDEM Med J* 2013; 3(2): 121)

JAMALUDDIN AHMED

A 17 years old student presented with tingling sensation of left upper limb particularly on sneezing, coughing or bending for 3 years followed by gradual decrease of sensation in that limb. 5 months back he developed similar problem in his right upper limb along with pain in his upper part of back. He also felt that his left upper

limb was wider than the right. There was no H/O any headache, visual disturbance, convulsion or unconsciousness. He had no gait difficulty or lower limb involvement. His bowel and bladder habits were normal. He had a H/O RTA with minor neck injury – 4 years back. The radiological images are given below.

What is the diagnosis?



Dr. Jamal Uddin Ahmed, Assistant Professor, Internal Medicine, BIRDEM, Dhaka