

Answer to Medical Quiz: Images

1. Epiglottitis appears to be swollen and nodular in appearance causing partial narrowing of air column. Soft tissue anterior to hyoid also appears to be swollen.
2. Acute epiglottitis.

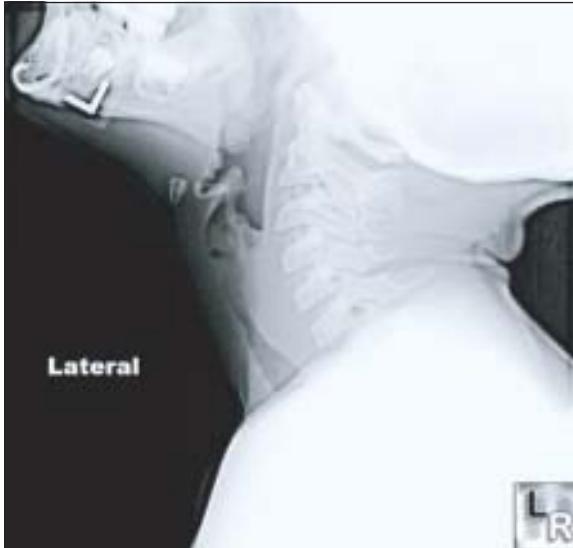


Fig-1: X-ray soft tissue neck showing normal epiglottitis.

Review

Epiglottitis is an inflammation of the epiglottis. Due to its place in the airway, inflammation can interfere with breathing and constitutes a medical emergency.

Most often caused by *Haemophilus influenzae* type B, although group A beta-hemolytic *Streptococci*, *Staphylococcus aureus*, *Moraxella catarrhalis* are responsible. Sometimes, chemical injury, inhalational injury (burn), crack or heroine smoking can cause epiglottitis.

Epiglottitis commonly affects children. Presentations are fever, difficulty in swallowing, drooling, hoarseness of voice and typically stridor. Since the introduction of *Haemophilus influenzae* (Hib) vaccination, childhood incidence has decreased while adult incidence remained the same, thus the disease is becoming relatively more common in adults than children.¹

If epiglottitis is suspected, attempts to visualize the epiglottis using a tongue depressor are strongly

discouraged as it may provoke airway spasm. Therefore, diagnosis is made on the basis of direct fiber-optic laryngoscopy carried out in operating room. On lateral cervical spine X-ray, the thumbprint sign (or 'thumb sign') describes a swollen, enlarged epiglottis², usually with dilated hypo-pharynx and normal supra-glottic structures.

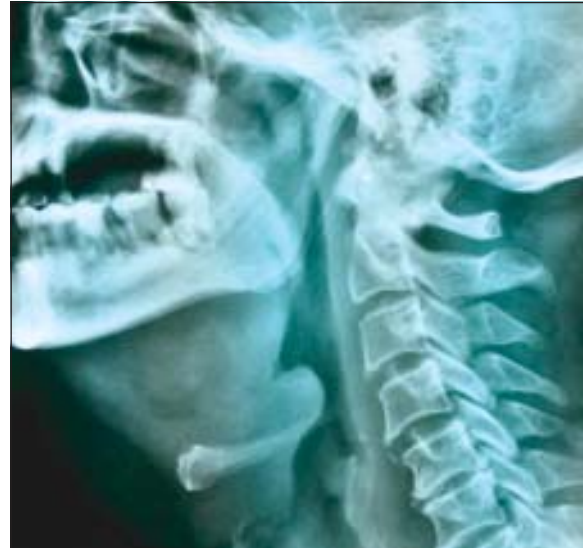

Fig-2: Thumb-print sign due to swollen, inflamed epiglottitis.

Epiglottitis may require urgent endotracheal intubation to protect airway, if failed then tracheostomy remains the option. In addition, patient should be given antibiotics, such as 2nd or 3rd generation cephalosporins, either alone or in combination with penicillin or ampicillin. Cotrimoxazole or clindamycin is an alternative, if patient is allergic to penicillin.

References

1. Bowman, Jeffrey. "Adult Epiglottitis". *eMedicine*. MedScape. Retrieved 2010-12-30. From 1996-2005, with the introduction of widespread H influenzae type b vaccination, an incidence of only 0.02 cases per 100,000 per year was seen. During this period, the incidence of acute epiglottitis in adults remained constant, at 1.9 cases per 100,000 per year.
2. Jaffe JE. Acute Epiglottitis. *eMedicine.com*. Available at: <http://www.emedicine.com/Radio/topic263.htm>. Accessed on: December 21, 2010.