

MEDICAL QUIZ

Medical Quiz: Images

SAMAD T^a, HAQUE HF^b, HAQUE WMM^c

(*Birdem Med J 2015; 5(Supplement 1): 63*)

A 25-year-old man presented with swelling of ankle and face and multiple symmetrical large joint pain for 2 months. He also mentioned about rash in his face involving the cheeks and forehead which aggravated

on exposure to sun (Fig A) He also had follicular lesion in the palm and sole and oral ulcer at the hard palate. (Fig B). Fundal photograph is also available. (Fig C)

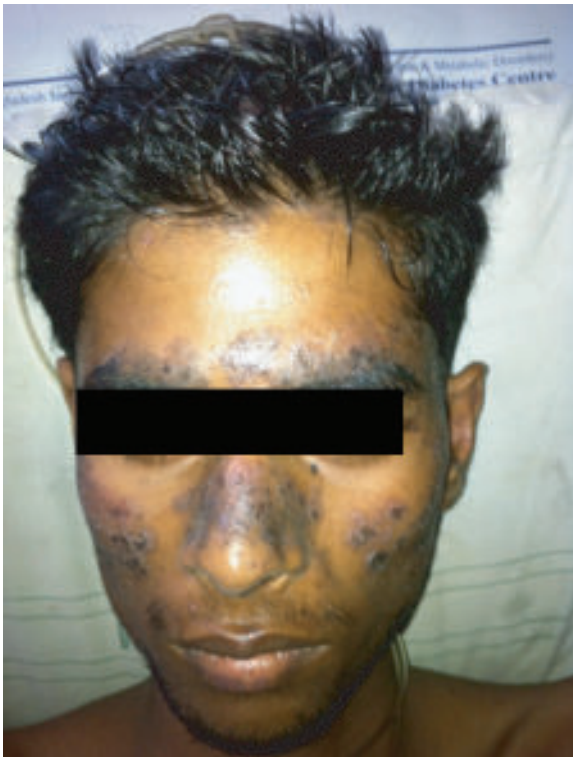

Fig-A

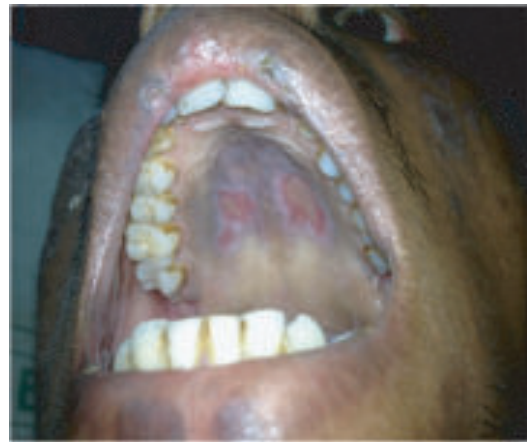

Fig-B

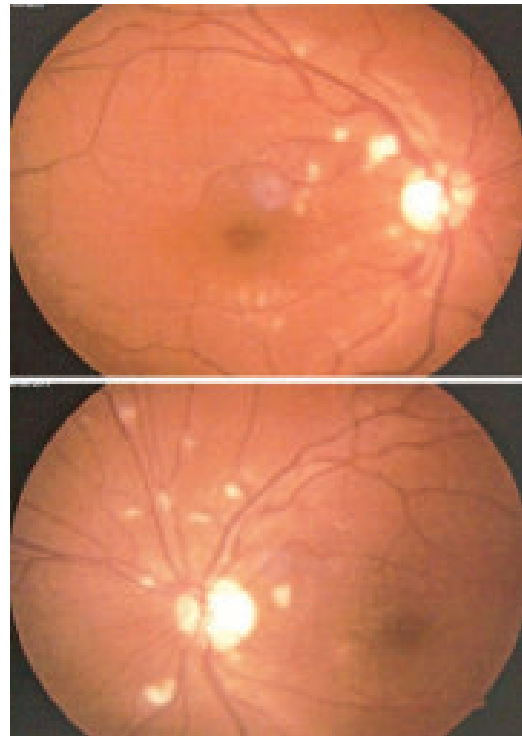


Fig-C

- Q 1. What is the most likely diagnosis?**
Q 2. What is atypical in this case?
Q 3. What is the finding in fundal photogaph?

- Dr. Tabassum Samad, FCPS (Medicine), Registrar, Nephrology, Ibrahim Medical College and BIRDEM General Hospital, Shahbag, Dhaka 1000, Bangladesh
- Dr. Hasna Fahmima Haque, FCPS (Medicine), Registrar, Internal Medicine, Ibrahim Medical College and BIRDEM General Hospital, Shahbag, Dhaka-1000, Bangladesh.
- Dr. Wasim Md. Mohosinul Haque, FCPS (Medicine) Associate Professor, Nephrology, Ibrahim Medical College and BIRDEM General Hospital, Shahbag, Dhaka 1000, Bangladesh

Address of Correspondence: Dr. Tabassum Samad, FCPS (Medicine), Registrar, Nephrology, Ibrahim Medical College and BIRDEM General Hospital, Shahbag, Dhaka 1000, Bangladesh