

Diabetes Mellitus Specific Infections

(*BIRDEM Med J* 2017; 7(1):1-5)

People with diabetes mellitus are exceptionally prone to develop infections like Emphysematous pyelonephritis (EPN), Mucormycosis, Malignant otitis externa and Melioidosis. Birdem general hospital is 700 bed tertiary care multidisciplinary hospital in Dhaka, Bangladesh with around 80% patients having Diabetes Mellitus. We have series of case with Melioidosis, Emphysematous pyelonephritis, Mucormycosis and Malignant otitis externa. Majority of these cases were detected and treated in our hospital during last few years. These cases were reported to journal, presented to national and international seminar. We do not infrequently encounter these type of cases because of professional involvement in this hospital dedicated to people with Diabetes mellitus.

Mucormycosis

(previously called zygomycosis) - is a fungal infection, can affect any organ but commonly affect the sinuses, brain, or lungs mostly in people with a weakened immune system, caused by a mold of mucormycete group frequently found in the soil and in dying plants.

People affected: Diabetes (usually poorly controlled), AIDS, burns, metabolic acidosis (diabetic ketoacidosis), leukemia and lymphoma etc.

Why Diabetes Mellitus (DM) preponderance: The fungus develops in environment of high glucose. The fungus grows in acid environment. Most of the series shows Mucormycosis commoner in patients with Diabetic ketoacidosis at presentation.

Site of involvement: Rhino Orbito Cerebral: Sinus, orbit and brain infection, which may start as a sinus infection, ultimately causes swelling of the cranial nerves.

Pulmonary Mucormycosis: Pneumonia that gets worse quickly and may spread to the chest cavity, heart and brain.

Mucormycosis of the gastrointestinal tract, skin, and kidney may happen.

Symptoms /signs: According to site of involvement. Commonest site Rhino-orbito-cerebral.

Symptoms of rhino-orbito-cerebral Mucormycosis include: Eye swelling and protrusion (proptosis), Dark nasal discharge (scabbing), Fever, Headache, Mental status changes, Redness of skin overlying sinuses, Sinus pain or congestion. These are in addition to original disease viz Diabetic ketoacidosis

Clinical Examination : An ear-nose-throat (ENT) doctor and an eye specialist should see the patient in case of rhino-orbital and neurologist if cerebral manifestation is there.

Investigations: Testing depends on symptoms but may include: CT or MRI scans. A biopsy must be done to make a definitive diagnosis of Mucormycosis

Treatment

Surgery should be done immediately to remove all dead and infected tissue. Surgery can lead to disfigurement because it may involve removal of the palate, parts of the nose, or parts of the eye. Without such aggressive surgery, however, chances of survival are greatly decreased.

Systemic antifungal medicines: Usually amphotericin B is needed.

Prognosis

Mucormycosis has an extremely high death rate even when aggressive surgery is done. Death rates range from 25 - 85% depending on the body area involved and overall health.

Malignant otitis externa

Malignant external otitis (MEO) is an infection that affects the external auditory canal and temporal bone. The causative organism is usually *Pseudomonas aeruginosa*, and the disease commonly manifests in

elderly patients with diabetes. The infection begins as an external otitis that progress into an osteomyelitis of the temporal bone.

Comorbid conditions: Patients with MEO almost always have diabetes(>90%), MEO has been reported in all age groups but is most common in patients who are elderly (age >60 y).

Clinical features

Symptom: Severe, unrelenting, deep-seated otalgia, Temporal headaches, Purulent otorrhea. Possible dysphagia, hoarseness, and/or facial nerve dysfunction. The pain is out of proportion to the physical examination findings.

Sign: Inflammatory changes are observed in the external auditory canal and the periauricular soft tissue. Marked tenderness is present in the soft tissue between the mandible ramus and mastoid tip. Granulation tissue is present at the floor of the Osseo cartilaginous junction. This finding is virtually pathognomonic of malignant external otitis. Ooscopic examination may also reveal exposed bone.

Cranial neuropathy

Cranial nerves can be affected by inflammation along the skull base or by a neurotoxin produced by *Pseudomonas* species. The facial nerve (VII) is affected most commonly, usually at the stylomastoid foramen. IX, X, and XI can be affected also XII. The cranial nerves (V-XII) should be examined

Intracranial complications: These complications rarely occur in the absence of cranial nerve palsies. Meningitis, brain abscess, and dural sinus thrombosis may ensue. Mental status examination should be performed. Deterioration of the mental status may indicate intracranial complication. The tympanic membrane is usually intact. Fever is uncommon.

Causes

Diabetes is the most significant risk factor for developing malignant external otitis.

- Small-vessel vasculopathy and immune dysfunction associated with diabetes are primarily responsible for this predisposition. The cerumen

of patients with diabetes has a higher pH and reduced concentration of lysozyme, which may impair local antibacterial activity. No difference in predisposition is found between diabetes types I and II. The predisposition is not necessarily related to the severity of glucose intolerance or periods of hyperglycemia. The term malignant is used to emphasize the serious nature of this infection. Some series claimed their 100% cases to be with DM.

Aural irrigation: As many as 50% of cases of malignant external otitis have been reported to be preceded by traumatic aural irrigation in patients with diabetes.

Patients with Immunodeficiencies, such as lymphoproliferative disorders or medication-related immunosuppression, AIDS may have predilection of it.

Laboratory evaluation

The leukocyte count in MEO is usually normal or mildly elevated. The erythrocyte sedimentation rate (ESR) is invariably elevated. ESR can be used to support the clinical diagnosis since acute external otitis or ear canal malignancy usually does not cause much elevation of ESR

Biochemistry: Patients without a history of diabetes should be tested for glucose intolerance.

Culture and sensitivities from the external auditory canal drainage should be performed ideally before antimicrobial therapy is initiated. The most common causative organism is *P. aeruginosa* (95%). Less common organisms identified include *Aspergillus* and *Proteus* species, *Candida* species, *Staphylococcus aureus* (Specially MRSA), and *S. epidermidis*.

CT scanning and MRI are both useful for evaluating the anatomic extent of soft tissue inflammation, abscess formation, and intracranial complications.

A biopsy of the external auditory canal to exclude carcinoma or other etiologies needed.

Treatment and management

Treatment includes meticulous glucose control, aural toilet, systemic and ototoxic antimicrobial.

Duration of therapy

Symptoms and examination findings improve with appropriate therapy, but these changes do not correlate with the length of needed therapy. Despite symptom relief, prolonged antimicrobial treatment as indicated for osteomyelitis is still indicated. Treatment response should be evaluated with a gallium citrate Ga 67 scan every 4-6 weeks during treatment.

Surgery is now reserved for local debridement, removal of bony sequestrum, or abscess drainage.

Outlook (Prognosis)

Majority cases with Diabetes mellitus have frustrating outcome. Malignant otitis externa often responds to long-term treatment, especially if treated early. It may return in the future. Severe cases may be deadly.

Emphysematous pyelonephritis

Emphysematous pyelonephritis (EPN) is a severe, necrotizing infection of the renal parenchyma; it causes gas formation within the collecting system, renal parenchyma, and/or perirenal tissues. Other terms that have been used to describe the condition include renal emphysema and pneumonephritis. Gas in the renal pelvis alone, without parenchymal gas, is often referred to as emphysematous pyelitis. EPN is common in persons with diabetes (some series claim their 100% cases were with DM) often has a fulminating course, and can be fatal if not recognized and treated promptly.

Definition: Presence of culture positive UTI and presence of gas in the renal parenchyma / collecting system as evident on USG of KUB then confirmed by CT scan

Signs and symptoms

Typical presenting features of EPN include the following: Fever (79%), Abdominal or flank pain (71%), Nausea and vomiting (17%), Dyspnea (13%), Altered sensorium (19%), Shock (29%).

Other possible findings include the following

Crepitus over the flank area in advanced cases of EPN, Pneumatouria is uncommon unless emphysematous cystitis is present, Subcutaneous emphysema and pneumomediastinum have been reported in a case of EPN,

Comorbidities include alcoholism, malnourishment, renal calculi, and diabetic ketoacidosis.

Infectious agents

Among the bacteria associated with emphysematous pyelonephritis, *Escherichia coli* is isolated in 66% of patients, and *Klebsiella* species are reported in 26% of patients. *Proteus*, *Pseudomonas*, and *Streptococcus* species are other organisms found in patients with EPN, and *Entamoeba histolytica* and *Aspergillus fumigatus* also have been reported to cause the disease. Mixed organisms are observed in 10% of patients. Positive blood culture results are identical to urine culture results in 54% of patients. Rare organisms such as *Clostridium* and *Candida* species have also been isolated in patients with EPN.

Diagnostic workup

A high index of suspicion is important when attempting to diagnose emphysematous pyelonephritis promptly.

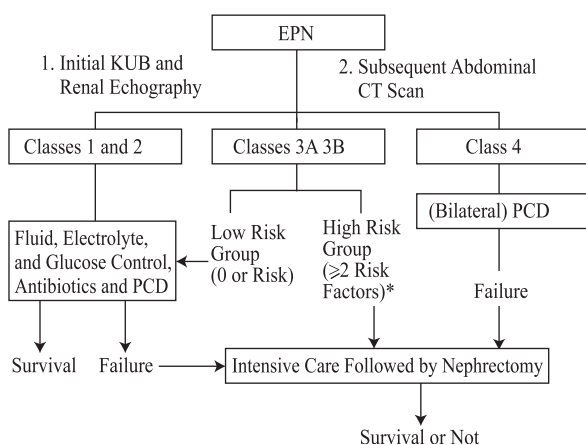
Laboratory data reveal leukocytosis with a left shift, pyuria, infected urine, thrombocytopenia, an elevated creatinine level, and positive blood culture. Patients with urosepsis and shock should undergo cardiac and pulmonary function assessment as needed.

Ultrasonography: Often reveal high echogenic areas with dirty shadowing. Hydronephrosis and perinephric fluid may also be seen:

Computed tomography (CT) scanning is the definitive imaging test for EPN

Several patterns have been described, including streaky, streaky and mottled, and streaky and bubbly. Gas can be rim like or crescent shaped in the perinephric area. Gas can also be seen in the renal vein or inferior vena cava and along the psoas muscle. Perinephric abscess may lead to significant gas accumulation in the perinephric space. A stone may be seen in the collecting system.

Staging and its evolution according to imaging characteristics:

Management:**Management algorithm for EPN**

Patients with emphysematous pyelonephritis should be treated with aggressive medical management and, possibly, prompt surgical intervention. However, surgical intervention should be performed only after stabilization of the patient's cardiorespiratory status. Prompt hydration, fluid resuscitation, and systemic antibiotics are the mainstays of medical management in EPN. Initial antibiotic therapy is based on local resistance patterns and patient factors; agents may include intravenous ampicillin, third- or fourth-generation cephalosporins, gentamicin, amikacin, vancomycin, and metronidazole. Regimens are adjusted as necessary when culture sensitivities become available. In patients with renal compromise, doses must be adjusted according to creatinine clearance. A monitored-care facility may be needed for patients in shock. Control of diabetes and maintenance of adequate fluid balance should be achieved quickly. Any obstruction found on imaging studies should be relieved with either percutaneous drainage or stent placement. The presence of a stone often leads to obstruction, which must be urgently relieved with percutaneous drainage or stenting. Definitive treatment for stones should be deferred until later.

Conservative treatment using percutaneous drainage with antibiotics is indicated as follows

1. Patients with compromised renal function
2. Early cases associated with gas in the collecting system alone and patient is in otherwise in stable condition
3. Class 1 and class 2 EPN
4. Class 3 and class 4

EPN - In the presence of fewer than 2 risk factors (eg, thrombocytopenia, elevated serum creatinine levels, altered sensorium, shock)

The use of **nephrectomy** is indicated as follows

1. No access to percutaneous drainage or internal stenting (after patient is stabilized)
2. Gas in the renal parenchyma or "dry-type" EPN
3. Possibly bilateral nephrectomy in patients with bilateral EPN
4. Class 3 and class 4 EPN - In the presence of more than 2 risk factors (eg, thrombocytopenia, elevated serum creatinine, altered sensorium, shock)

Prognosis

Overall EPN mortality rate of 19-40%. Reported treatment success rates with percutaneous drainage and antibiotics (66%) and with nephrectomy (90%). Furthermore, the investigators reported a high risk of death in patients with serum creatinine levels greater than 1.4 mg/dL and platelet count of less than 60,000/ μ L.

Gas and it's mechanism of production

Schainuck et al proposed that fermentation products from tissue necrosis produced carbon dioxide. Three investigators analyzed the gas content, and all 3 demonstrated that the major components of the gas in EPN include nitrogen (60%), hydrogen (15%), carbon dioxide (5%), and oxygen (8%).

Huang et al concluded that mixed acid fermentation is the mechanism of gas production based on the presence of hydrogen.

In presence of high glucose-in DM, the glucose fermenting bacteria produces gas.

Impaired host immunity, a perfect situation for bacteria to grow. It has been suggested that gas-forming infections depend on rapid tissue catabolism and impaired transport of the end products at the inflammatory site. Diabetic microangiopathy may also contribute to the slow transport of catabolic products and may lead to accumulation of gas.

Melioidosis

Whitmore's disease is an infectious disease caused by a Gram-negative bacterium, *Burkholderia pseudomallei*, found in soil and water. It is of public health importance in endemic areas (south and southeast Asia and northern Australia). It exists in acute and chronic forms. It has

the potential for epidemic spread to areas where it is not endemic, and sporadic case reports elsewhere in the world suggest that as-yet-unrecognized foci of infection may exist. Environmental determinants of this infection, apart from a close association with rainfall, are yet to be elucidated. The sequencing of the genome of a strain of *B. pseudomallei* has recently been completed and will help in the further identification of virulence factors. The presence of specific risk factors for infection, such as diabetes mellitus suggests that functional neutrophil defects are important in the pathogenesis of melioidosis; others have defined virulence factors (including a type III secretion system) that allow evasion of killing mechanisms by phagocytes. There is a possible role for cell-mediated immunity, but repeated environmental exposure does not elicit protective humoral or cellular immunity. A vaccine is under development, but economic constraints may make vaccination an unrealistic option for many regions of endemicity.

Disease manifestations are protean; diagnosis relies on culture of the organism. Despite the introduction of ceftazidime- and carbapenem-based intravenous treatments, melioidosis is still associated with a significant mortality attributable to severe sepsis and its complications. A long course of oral eradication therapy is required to prevent relapse. Studies exploring the role of preventative measures, earlier clinical identification, and better management of severe sepsis are required to reduce the burden of this disease. Most of the series claimed almost 80% of their cases were with DM. The exact mechanism or pathogenesis of relation to diabetes Mellitus is yet to be revealed.

The topic was discussed in our journal as editorial (Melioidosis: an emerging infection in Bangladesh .*Birdem med j* 2016;6:3-6).

Khwaja Nazim Uddin

Professor of Medicine
BIRDEM General Hospital, Dhaka