

## Medical Quiz

---

### Medical Quiz: Images

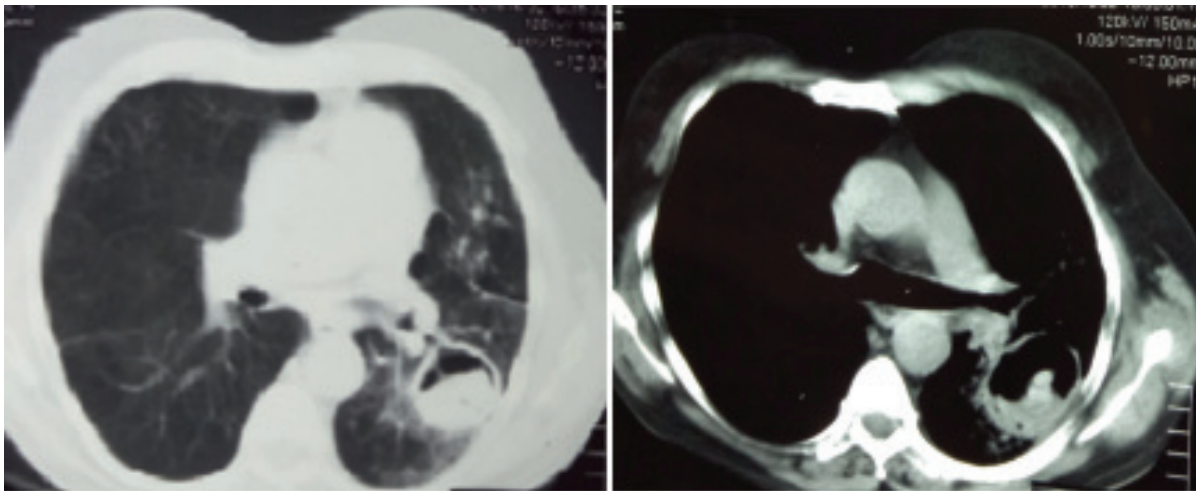
Afroz F<sup>a</sup> Ahmed JU<sup>b</sup> Hossain MD<sup>c</sup>

(*BIRDEM Med J 2017; 7(1): 76*)

A-70-year-old nonsmoker retired businessman visited the Pulmonology OPD of BIRDEM with low grade evening rise of temperature and cough without hemoptysis for one month and was eventually diagnosed as smear positive pulmonary TB with his Chest X-ray showing a cavitory lesion in left upper and part of midzone. He was prescribed CAT-1 anti-TB medication, his sputum became negative for AFB from second month onwards and he was improving satisfactorily. But after 4 months, he presented with sudden onset of hemoptysis that was continuing for three weeks. It was scanty in amount and occurred 2 to 3 times per week.

He had no history of fever, chest pain, breathlessness or anorexia. Except being mildly anemic, his physical findings were unremarkable. His sputum was still negative for AFB and sputum culture showed no growth. Complete blood count revealed, hemoglobin 9 gm/dl with eosinophil 11%. Other parameters were within normal limit. His CT scan of chest is given below.

- Please mention the most significant abnormal radiological finding.
- What is your diagnosis?



---

#### Author Informations

- Dr. Farhana Afroz, FCPS (Medicine), Registrar, Internal Medicine, Ibrahim Medical College and BIRDEM General Hospital, Dhaka
- Dr. Jamal Uddin Ahmed, FCPS (Medicine), Assistant Professor, Internal Medicine, Ibrahim Medical College and BIRDEM General Hospital, Dhaka
- Dr. Md. Delwar Hossain, MD (Chest), Associate Professor, Internal Medicine, Ibrahim Medical College and BIRDEM General Hospital, Dhaka

**Address of correspondence:** Dr. Farhana Afroz, FCPS (Medicine), Registrar, Internal Medicine, Ibrahim Medical College and BIRDEM General Hospital, Dhaka

**Received:** November 28, 2016

**Accepted:** November 30, 2016