

## Case Report

# Bardet Biedl Syndrome: A Case Report

Nabi MU<sup>a</sup>, Pathan MF<sup>b</sup>, Barua M<sup>c</sup>

### Abstract

*Bardet Biedl syndrome is a rare heterogenous autosomal recessive disorder. A very few cases were reported in Bangladesh. A 12-year-old boy presented with childhood obesity, polydactyly in all 4 limbs, bilateral gynaecomastia, acanthosisnigricans, night blindness and mental retardation. After hormonal evaluation he was found to have hypogonadotrophichypogonadism, dislipidaemia, renal impairment, elevated liver enzymes and retinitis pigmentosa. We advised him to reduce weight and implemented a weight reducing diet. Levothyroxine and metformin were started. He was scheduled for eye check-up every 3 months and follow up at endocrinology.*

**Key words:** Bardet Biedl syndrome, Retinitis pigmentosa, Lawrence Moon syndrome, obesity, hypogonadism.

*(BIRDEM Med J 2019; 9(2): 162-164)*

### Introduction

Bardet Biedl syndrome is a genetically heterogenous disorder that is usually inherited as autosomal recessive trait.<sup>1</sup> The main problem is in the BBS1 gene located in the long arm of chromosome 11.<sup>2</sup> Visual loss and obesity are main features of this syndrome. Other features are polydactyly or syndactyly, hypogonadism, impairment of speech, delayed motor skill development, distinctive facial appearance, behavioural abnormality, poor coordination, dental abnormalities and partial or complete loss of sense of smell. Here, we present a 12-year-boy with characteristic features of Bardet Biedl syndrome with metabolic syndrome, renal impairment, impaired glucose tolerance and elevated liver enzymes.

### Case Report

A 12-year-old young boy was admitted in BIRDEM General Hospital on with the complaints of night blindness and under developed penis and scrotum. He was obese since childhood. There was learning difficulties with low IQ level. There was no

consanguinity of marriage between his parents. On query, his mother complained about increased hunger. His body mass index (BMI) was 31.98Kg/m<sup>2</sup>, which was more than 95 percentile according to his age. Stretched penile length (SPL) was 2 cm and testicular volume is was 1.5 ml. Tanner stage 1. Skin was thick, coarse and dry with presence of Acanthosisnigricans. He also noticed gynaecomastia (stage 4) on both side. He had extra axial polydactyly in all 4 limbs. Neurological examination of lower limbs revealed normal. Fundoscopy revealed retinitis pigmentosa.

His hormone analysis reveals primary hypothyroidism (TSH 8.09 uIU/ml, FT4 14.64 pmol/L), secondary hypogonadism (S. LH 0.08 mIU/ml, S. testosterone 0.36 ng/ml), and abdominal ultrasonography revealed fatty change in liver. Fasting lipid profile revealed high triglyceride level (176 mg/dl) decreased HDL level (35 mg/dl) and he had impaired fasting glucose (IFG) (Fasting 4.6 mmol/L and 2 hr after 75 gm glucose 8.4 mmol/L). His liver enzymes were also elevated including alkaline phosphatase (AST 141 u/L, ALT 101 U/L, S. bilirubin 0.6 mg/dl and alkaline phosphatase 318 u/L). His renal function tests showed mild renal impairment (S. creatinine 1.3 mg/dl, eGFR-82.98 ml/min/1.73 m<sup>2</sup>).

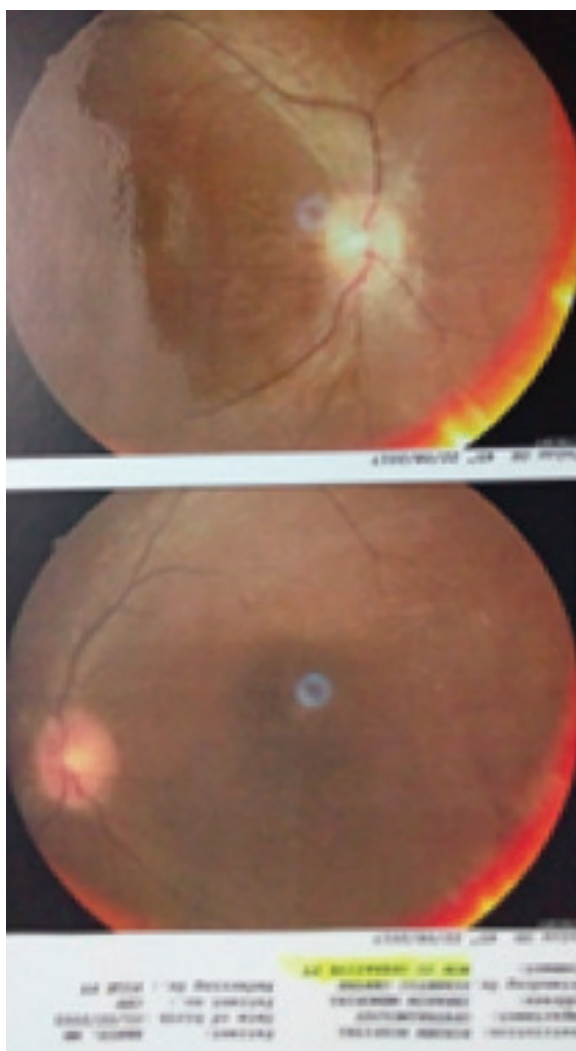
We advised the patient to do exercise regularly and implemented a weight reducing diet chart. We gave him levothyroxine 50 microgram once daily and metformin 500 mg twice daily. Ophthalmological follow up was scheduled after 3 months.

### Author Information

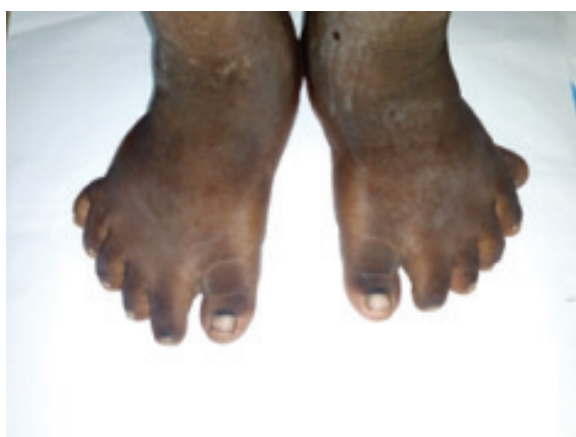- Dr. Md. Masud Un Nabi, Department of Endocrinology, BIRDEM General Hospital, Shahbagh, Dhaka.
- Prof. Md. Faruque Pathan, Professor and Head, Department of Endocrinology, BIRDEM General Hospital, Shahbagh, Dhaka.
- Dr. Milton Barua, Department of Endocrinology, BIRDEM General Hospital, Shahbagh, Dhaka.

**Address of correspondence:** Dr. Md. Masud Un Nabi, Department of Endocrinology, BIRDEM General Hospital, Shahbagh, Dhaka. Email: masudnabi@gmail.com

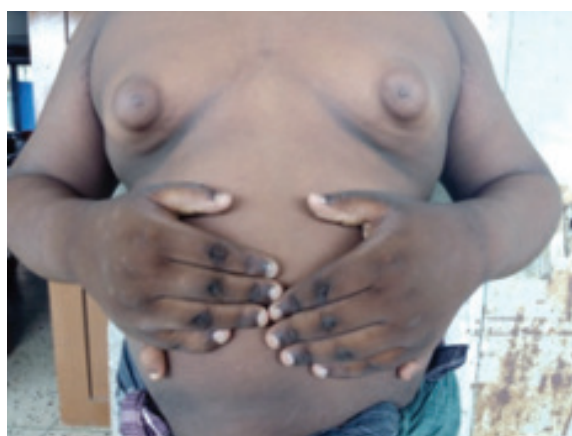**Received:** November 25, 2017      **Accepted:** February 28, 2019



**Figure 1** Fundus photography showing features of retinitis pigmentosa



**Figure 2** Polydactyly of both feet



**Figure 3** Bilateral gynecomastia and polydactyly of both hands

### Discussion

This syndrome is named after George Bardet and Arthur Biedl. The first known case was reported by Laurence and Moon in 1866 at the Ophthalmology Hospital in south London. Laurence-Moon-Bardet-Biedl syndrome is no longer considered a valid term because Laurence and Moon had paraplegia but no obesity or polydactyly, which is the key features of Bardet-Biedl syndrome.<sup>3</sup> Laurence-Moon syndrome is now considered a separate entity.

Bardet-Biedl syndrome is rare; occurring about 1 in 160000 population in Switzerland but it is more common in specific population, like 1 in 13500 among kuwaiti Bedouins and 1 in 17500 among residents of Newfoundland in Canada.<sup>4,5</sup> Retinitis pigmentosa is caused by progressive degeneration of Rod photo receptor cells in the retina.<sup>6</sup>

Prognosis is poor if there is renal involvement. Many patient die from renal failure in early age. Genetic counseling and pre-conception genotyping of family members may be worthwhile. Prenatal second-trimester ultrasound scanning in pregnancies with increased risk looking for polydactyly and renal anomalies (enlarged hyperechoic kidneys) can help in diagnosing BBS antenatally.

There is no definitive treatment for BBS. Symptomatic treatment is the approach, like management of obesity, cosmetic surgery for gynaecomastia, using stick and support of caretakers for walking, multi-disciplinary approach from speech therapist, audiologist, orthopedic surgeons and endocrinologists.

**Conflict of interest:** Nothing to declare.

**References**

1. Beales PL, Elcioglu N, Woolf AS. New criteria for improved diagnosis of Bardet-Biedl syndrome: results of a population survey. *Journal of Medical Genetics* 1999;36:437-46.
2. Beales PL, Warner AM, Hitman GA, Thakker R, Flintner FA. Bardet-Biedl syndrome: A molecular and phenotypic study of 18 families. *J Med Genet* 1997;34: 92-98.
3. Green J, Parfrey PS, Harnett JD, Farid N, Cramer B, Johnson G. The Cardinal Manifestations of Bardet-Biedl Syndrome, a Form of Laurence-Moon-Biedl Syndrome. *N Engl J Med* 1989; 321:1002-1009.
4. Kumar S, Mahajan BB, Mittal J. Bardet-Biedl syndrome: a rare case report from North India. *Indian J Dermatol Venereol Leprol.* 2012 Mar-Apr;78(2):228.
5. Andrew P. Schachat, Irene H. Maumenee. Bardet-Biedl Syndrome and Related Disorders. *Arch Ophthalmol.* 1982;100(2):285-288.
6. Wahiduzzaman M, Rahim MA, Iftekhhar M. Bardet-Biedl Syndrome: A Case Report. *BIRDEM Med J* 2018; 8(2): 184-86.