

## Medical Quiz

---

### Medical Quiz: Images

Islam MR<sup>a</sup>, Rahman T<sup>b</sup>

(*BIRDEM Med J 2019; 9(1): 261*)

A 45 year old woman presented with a painful vesicular rash on upper lip followed by headache, unsteadiness when walking, double vision, and photophobia. She had no significant previous medical history. On admission, she was alert, pyrexial. Neurological examination revealed truncal ataxia variable ophthalmoplegia with diplopia followed by tetraparesis, pyramidal signs, and consciousness impairment. Other systematic examination was unremarkable. This is the MRI of brain of that patient. See the photograph and answer the following question.

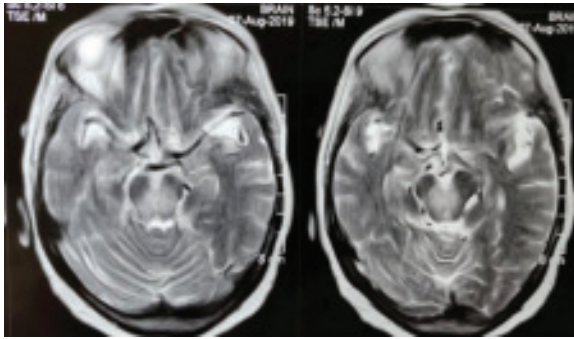


Figure 1

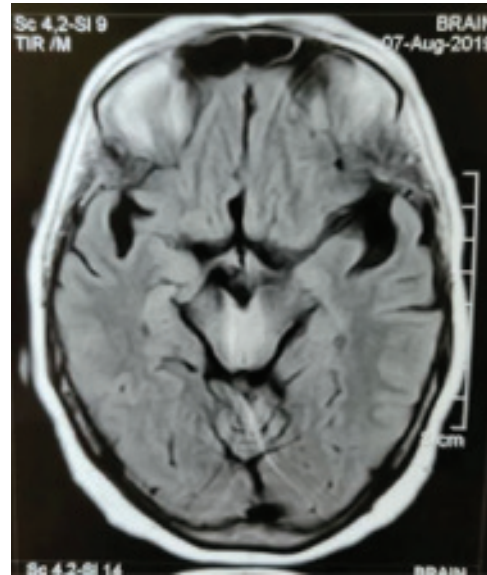


Figure 2

**Question 1:** What are the findings of MRI of brain?

**Question 2:** What is the diagnosis?

**Question 3:** What is the next investigation?

---

a. Dr. Md. Rashedul Islam, FCPS(Neurology), FCPS (Medicine), MRCP (UK), FACP (USA). Assistant Professor, Neurology, BIRDEM General Hospital, Shahbag, Dhaka, Bangladesh

b. Dr Tanbin Rahman, MBBS, MRCP(UK), Registrar, Medicine, Greenlife Medical College Hospital, Bangladesh

**Address of correspondence:** Dr. Md. Rashedul Islam, FCPS (Neurology), FCPS (Medicine), MRCP (UK), FACP (USA). Assistant Professor, Neurology, BIRDEM General Hospital, Shahbag, Dhaka-1000, Bangladesh