

Case Report

Per-rectal bleeding due to jejunal Crohn's: a rare case report from Bangladesh

Ahmed S^a, Hoque MN^b, Rahman MA^c

Abstract

Crohn's disease (CD) is a disorder of uncertain etiology that is characterized by transmural inflammation of the gastrointestinal tract. CD may involve the entire gastrointestinal tract from mouth to the perianal area. Isolated jejunal involvement of CD is a rare entity. We describe a case of CD involving only jejunum with successful treatment in a 74-years-man who presented with melaena, abdominal pain and significant weight loss. Endoscopy of upper gastro-intestinal tract revealed gastritis and colonoscopy showed small sessile polyp at rectum and sigmoid colon, polypectomy was done accordingly. After few days of polypectomy, he again noticed melaena along with abdominal discomfort and weakness with loss of 4 kg weight within this periods. Diagnosis was confirmed by capsule endoscopy and serology. Treatment was thereafter started with oral steroid and mesalamine sachet. The patient is now on remission and is on regular follow up. CD has propensity to involve the distal small intestine and proximal large bowel. Affected persons usually experience diarrhea and abdominal pain, frequently accompanied by weight loss. Proximal small bowel involvement is less common than distal small bowel or colonic involvement in CD. CD involving proximal small intestine should be suspected in Asian patients with middle gastro-intestinal bleeding. It is associated with a high risk of clinical relapse and morbidity, including the need for abdominal surgery. Different modalities of baseline evaluation and more sophisticated diagnostic modalities may be required for patients with CD involving proximal small bowel. Capsule endoscopy (CE) currently plays an important role in CD.

Key words: Bangladesh, jejunal Crohn's, per-rectal bleeding.

(BIRDEM Med J 2020; 10(1): 68-72)

Introduction

Crohn's disease (CD) is a disorder of uncertain etiology that is characterized by transmural inflammation of the gastrointestinal tract. CD may involve the entire gastrointestinal tract from mouth to the perianal area. Approximately 80 percent of patients have small bowel involvement, and 50 percent of patients have ileocolitis. Relatively fewer patients have involvement of proximal small bowel. CD that is confined solely to the jejunum and ileum is unusual and may be impossible to

differentiate from ischemic jejunitis and ulcerative jejunoileitis, a distinct condition that occasionally responds to a gluten-free diet. Frank malabsorption and steatorrhea often occur. If the disease is confined to a short segment of intestine or has features consistent with CD, initial management should be based on the presumed diagnosis of CD. The clinical manifestations of CD are more variable than those of ulcerative colitis. Patients can have symptoms for many years prior to diagnosis.¹⁻³ Fatigue, prolonged diarrhea with abdominal pain, weight loss and fever, with or without gross bleeding, are the hallmarks of CD.⁴

There is no available data regarding the incidence and prevalence of jejunal CD in Bangladesh. The diagnosis, management, course and prognosis of the disease remain highly enigmatic. In view of the situation, we report here a confirmed case of jejunal CD in a 74-year-old Bangladeshi male patient.

Author information

- Shireen Ahmed, Registrar, Department of GHPD, BIRDEM General Hospital, Dhaka, Bangladesh.
- Md. Nazmul Hoque, Ex-Associate Professor and Head of the Department of GHPD, BIRDEM General Hospital, Dhaka, Bangladesh.
- Md. Anisur Rahman, Professor, Department of GHPD, BIRDEM General Hospital, Dhaka, Bangladesh.

Address of correspondence: Shireen Ahmed, Registrar, Department of GHPD, BIRDEM General Hospital, Dhaka, Bangladesh. Email: a.alwasi15@gmail.com

Received: September 21, 2019

Accepted: October 31, 2019

Case report

A 74-year-old male presented at gastrointestinal, hepatobiliary and pancreatic diseases (GHPD) department of BIRDEM General Hospital with the complaints of melaena, which occurred intermittently, 1 to 2 episodes per day. The stool was small volume, semisolid in consistency, foul smelling and difficult to flush. Associated symptoms were progressive weakness for last one month which initially occurred with moderate physical activity but later occurred with even mild physical activity. Other features were occasional dizziness, palpitation and breathlessness. With these complaints he consulted with a physician and was found anaemic (Hb 7.1%). Therefore, he was admitted in a private hospital and received 4 units of blood transfusion. After correction of anaemia he underwent endoscopy, followed by colonoscopy. Endoscopy of upper gastro-intestinal tract (GIT) revealed gastritis and colonoscopy showed small sessile polyp at rectum and sigmoid colon, polypectomy was done accordingly.

After few days of polypectomy he again noticed passage of black tarry stool along with mild abdominal discomfort and generalized weakness. He lost about 4 kg weight within this period. On query, he had no history

of jaundice, vomiting of blood, abdominal pain with distension, altered level of consciousness. He further denied any perianal disease, contact with tuberculosis patient, redness of eyes, joint pain, skin lesions, taking any non-steroidal anti-inflammatory drugs (NSAIDs), anticoagulant or antiplatelets. On physical examination, he looked severely pale, his heart rate was 92/min, blood pressure 110/70 mmHg and respiratory rate 16/min. His weight was 49 kg and BMI was 19.6 kg/m². There was no clubbing, lymphadenopathy and skin lesion. His tongue was smooth and shiny, abdomen was soft, mild tenderness in lower abdomen but there was no guarding and no organomegaly. No abnormality was noted in the perianal region and no signs of inflammation in any joints. Other systemic examinations revealed no abnormality.

His investigations showed haemoglobin 6.3 gm/dl, peripheral blood film revealed severe dimorphic anemia, white blood cell count 9690/cmm. Erythrocyte sedimentation rate (ESR) was 90 mm in 1st hour, serum electrolytes and creatinine were normal. Abdominal ultrasound revealed normal study. Chest X-ray was also normal. After resuscitation, we reviewed endoscopy and colonoscopy which were found normal. The source of

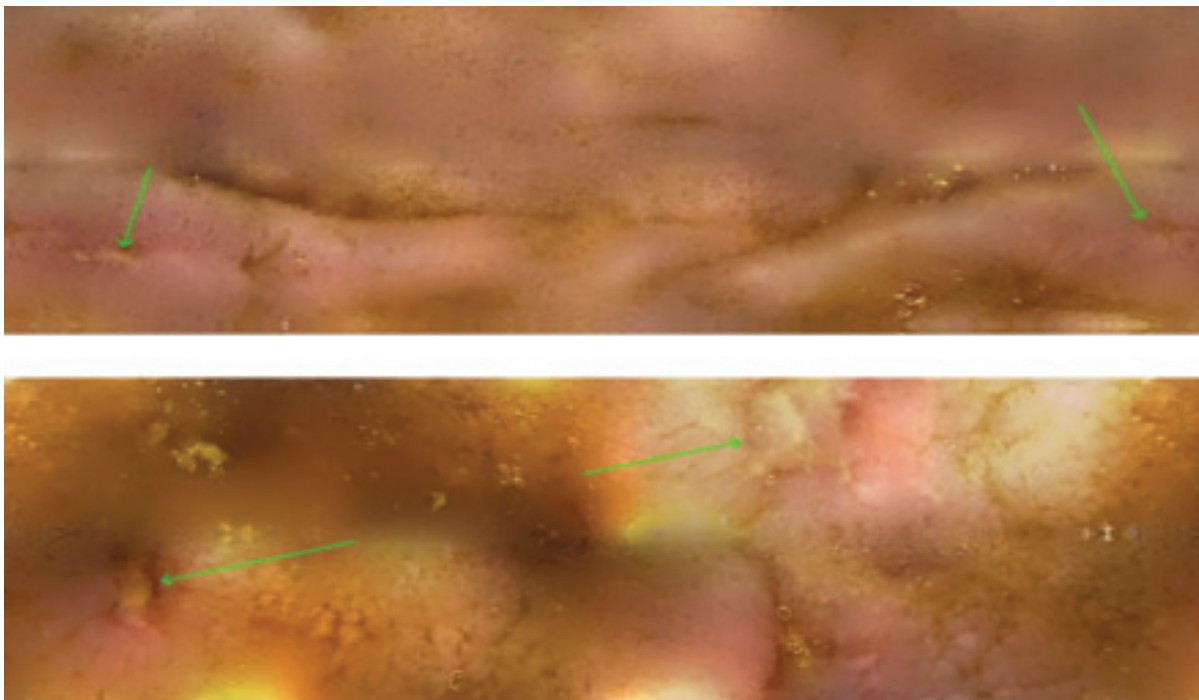


Figure 1 Focal aphthous jejunal ulcers

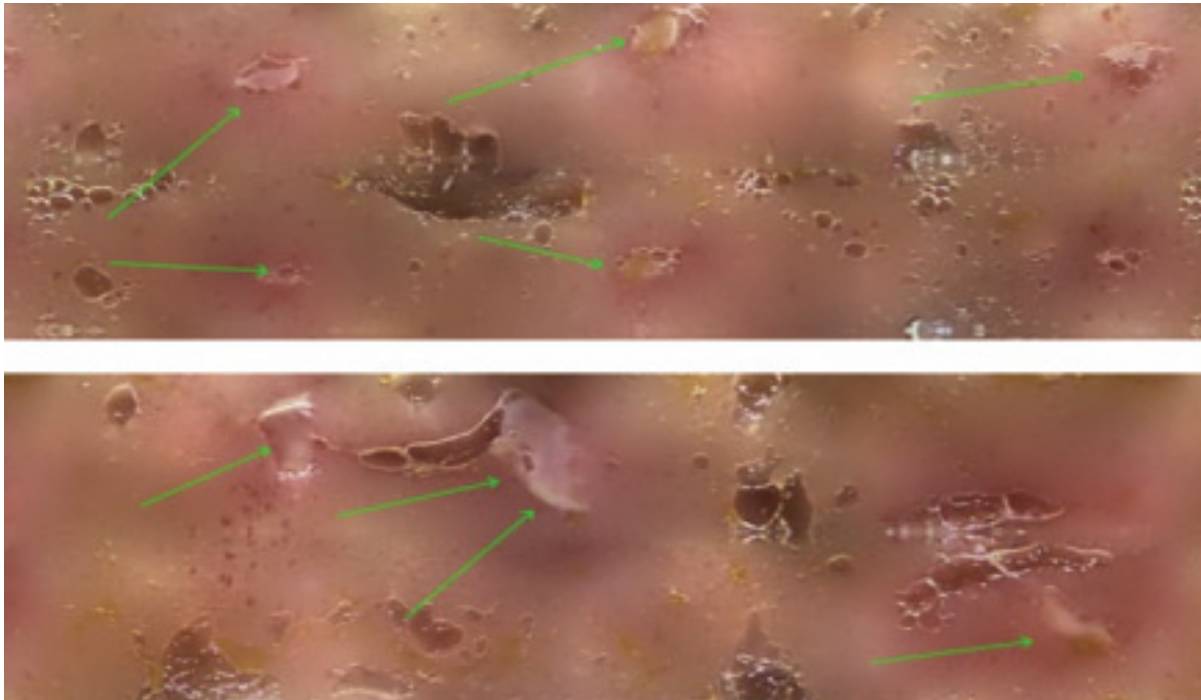


Figure 2 Focal aphthous jejunal ulcers

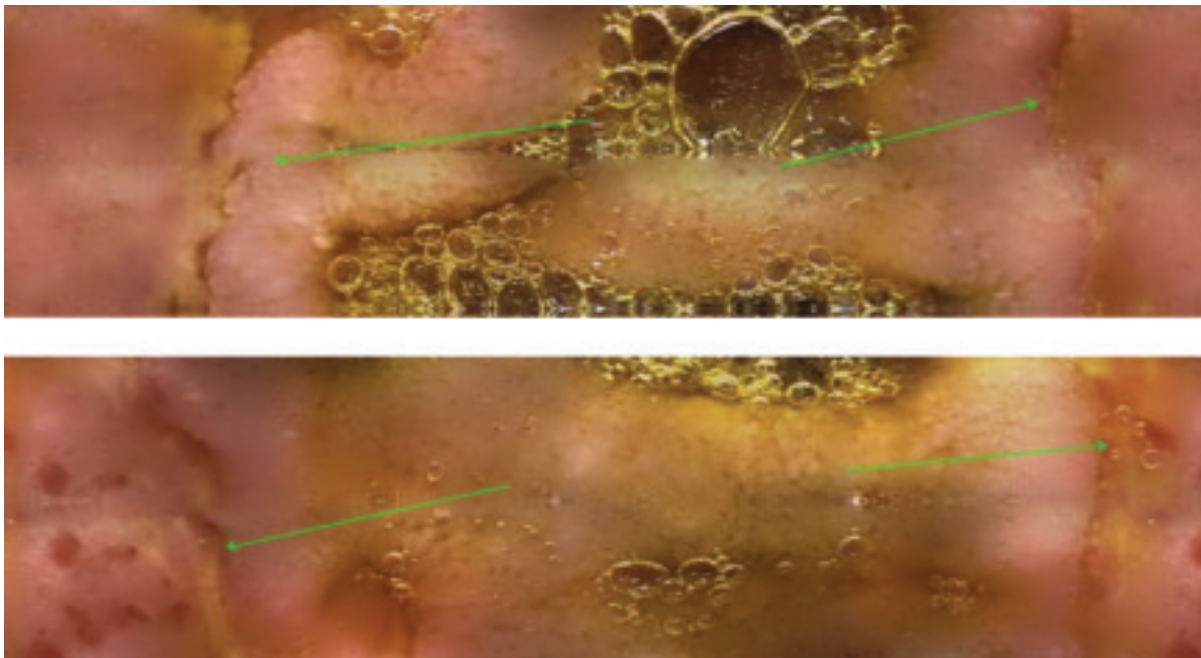


Figure 3 Deep jejunal ulcers

his bleeding was still not identified. Then we thought the bleeding source may be found in the middle GIT. Subsequently we did video capsule endoscopy. Capsule

was retrieved 24 hours after ingestion. Then it was sent for data recovery. There were multiple small aphthous ulcers to large deep elongated ulcers in jejunum with

skip areas which suggest CD (Figure 1,2,3). Other possibilities were NSAIDs induced ulcer, coeliac disease and tubercular ulcer. We did some serological markers like tissue transglutaminase (tTG) Ig A (15.2 U/ml) which was negative, Anti saccharomyces cerevisiae antibodies (ASCA) IgG and IgA respectively 28.60 units and 27.84 units, both were positive.

Initially, he was treated symptomatically including three units of blood transfusion. After confirmation of diagnosis, we started pentasa sachet 2 gm bd along with tab deflazacort 48 mg daily with supplementation of iron and folic acid. His symptom, like frequency of motion and per rectal bleeding decreased and general well being began to improve after 1 week of treatment. Subsequently, he was discharged on seventh hospital day with deflazacort 48 mg for one month thereafter 6 mg weekly reduction of dose. Pentasa sachet 2 gm bd continued. His bowel movement and per rectal bleeding had improved by the time of his outpatient review 2 weeks later. Complete blood count showed marked improvement of haemoglobin 11.5 and ESR 20 mm/1st hr.

Discussion

CD is a chronic inflammatory disorder with a propensity for the distal small intestine and proximal large bowel. Accurate comparisons of epidemiologic data on the incidence and prevalence of CD are hampered by a lack of gold-standard criteria for diagnosis and inconsistent case ascertainment. Moreover, the invasiveness and expense of diagnostic modalities ensures that diagnosed cases represent only a fraction of the diseased population. In Asia, the incidence rate has remained low, with a mean estimated incidence of 0.54 per100000 person-years.⁵

Our patient presented with melaena, abdominal pain and weight loss. We did not find any clue in endoscopy of upper GIT and colonoscopy. Then we performed capsule endoscopy and found multiple jejunal ulcers. Capsule endoscopy currently plays an important role in CD. It is a noninvasive technique that has led to a breakthrough in the endoscopic diagnosis of diseases of the small intestine. Its superior diagnostic performance and excellent safety profile lead to its considerable acceptance on the part of the patient. Current indications of capsule endoscopy in three stages of clinical practice: Suspected CD, unclassified colitis and its extensive role

in diagnosed CD.⁶ Achieving deep remission (clinical, biological and mucosal healing) improves the prognosis for CD with mucosal healing being an objective of treatment.⁷ The various radiological modalities, as opposed to endoscopic modalities, cannot provide direct visualization of the mucosa of the small bowel; consequently, they have an inherent limitation in the objective assessment of mucosal healing.

CD involving only in jejunum is a rare entity. In our patient we found only jejunal involvement. We further proved it by serological tests. Patient's symptoms were improved after treatment with steroid and mesalamin therapy which further proved CD. Proximal small bowel involvement is less common than distal small bowel or colonic involvement in CD, it should be of concern because it is associated with a high risk of clinical relapse, including the need for abdominal surgery.⁸ Several studies have demonstrated that patients showing proximal small bowel involvement have clinical features distinct from those of patients without proximal small bowel involvement.⁸ In addition, different modalities for baseline evaluation and more sophisticated surveillance may be required for patients with proximal small bowel involvement.⁹

In a study, it was found the proportion of Korean patients with proximal small bowel involvement was 16.7%,¹⁰ compared to 3.8% in Western countries.¹¹ This result is similar to another Korean study that estimated it at 14.1%.¹² Genetic or environmental factors have been suggested as possible reasons for this discrepancy. Previous reports have suggested a difference in the genetic susceptibility for inflammatory bowel disease between Asian and Western populations.¹³

Conclusion

CD involving proximal small intestine should be suspected in Asian patients with middle GIT bleeding. It is associated with a high risk of clinical relapse, morbidity including the need for abdominal surgery. Different modalities of baseline evaluation and more sophisticated diagnostic modalities may be required for patients with CD involving proximal small bowel.

Conflict of interest: Nothing to declare.

References

1. Farmer RG, Hawk WA, Turnbull RB Jr. Clinical patterns in Crohn's disease: a statistical study of 615 cases. *Gastroenterology* 1975; 68:627.
2. Pimentel M, Chang M, Chow EJ, Tabibzadeh S, Kirit-Kiriak V, Targan SR, et al. Identification of a prodromal period in

- Crohn's disease but not ulcerative colitis. *Am J Gastroenterol* 2000; 95(12):3458-62.
3. Burgmann T, Clara I, Graff L, Walker J, Lix L, Rawsthorne P, et al. The Manitoba Inflammatory Bowel Disease Cohort Study: prolonged symptoms before diagnosis—how much is irritable bowel syndrome? *Clin Gastroenterol Hepatol* 2006; 4(5):614-20.
 4. Mekhjian HS, Switz DM, Melnyk CS, Rankin GB, Brooks RK. Clinical features and natural history of Crohn's disease. *Gastroenterology* 1979; 77(4):898-906.
 5. Ng SC, Tang W, Ching J, Wong M, Chow CM, Hui AJ, et al. Incidence and phenotype of inflammatory bowel disease based on results from the Asia-Pacific Crohn's and Colitis Epidemiology Study. *Gastroenterology* 2013; 145(1):158-65.
 6. Van Assche G, Dignass A, Panes J, Beaugerie L, Karagiannis J, Allez M, et al. The second European evidencebased Consensus on the diagnosis and management of Crohn's disease: Definitions and diagnosis. *J Crohns Colitis* 2010; 4:7-27.
 7. Bouguen G, Levesque BG, Feagan BG, Kavanaugh A, Peyrin-Biroulet L, Colombel JF, et al. Treat to target: a proposed new paradigm for the management of Crohn's disease. *Clin Gastroenterol Hepatol* 2015; 13: 1042-50.
 8. Keh C, Shatari T, Yamamoto T, Menon A, Clark MA, Keighley MR. Jejunal Crohn's disease is associated with a higher postoperative recurrence rate than ileocaecal Crohn's disease. *Colorectal Dis.* 2005;7:366-68.
 9. Peyrin-Biroulet L, Loftus EV, Jr, Colombel JF, Sandborn WJ. The natural history of adult Crohn's disease in population-based cohorts. *Am J Gastroenterol* 2010;105:289-97.
 10. Kim OZ, Han DS, Park CH, Eun CS, Kim YS, Kim YH, et al. The Clinical Characteristics and Prognosis of Crohn's Disease in Korean Patients Showing Proximal Small Bowel Involvement: Results from the CONNECT Study. *Gut Liver* 2018 Jan; 12(1): 67-72.
 11. Freeman HJ. Long-term clinical behavior of jejunoileal involvement in Crohn's disease. *Can J Gastroenterol* 2005;19:575-78.
 12. Park SK, Yang SK, Park SH, Kim JW, Yang DH, Jung KW, et al. Long-term prognosis of the jejunal involvement of Crohn's disease. *J Clin Gastroenterol* 2013;47:400-408.
 13. Hu PJ. Inflammatory bowel disease in Asia: the challenges and opportunities. *Intest Res* 2015;13:188-190.