

Case Report

An 11-year-old girl with genital ambiguity: a case of non-classical congenital adrenal hyperplasia

Monni AF^a, Sobhan R^a, Pathan MF^b, Afsana F^c, Amin F^d

Abstract

Congenital adrenal hyperplasia (CAH) describes a group of autosomal disorders where there is impairment of cortisol biosynthesis. Here is a case of 11-year-old girl who presented with enlargement of external genitalia, excessive growth of hair in pubis, axilla, face and lower limbs along with growth spurt, excessive sweating and deepening of voice for 4 years. On examination she had normal body habitus, hirsutism (modified Ferriman-Gallwey Score-8), acanthosis nigricans in neck and axillary region, Tanner staging revealed stage-II breast development and stage IV female pattern pubic hair. Genitalia examination showed clitoromegaly with normal labia majora, minora and urethral position. Chromosomal analysis showed a normal female 46XX karyotype with normal uterus and bilateral ovaries on ultrasonography. Serum testosterone was elevated and 17-hydroxyprogesterone (17 OHP) was mildly elevated, raising the suspicion of non-classical congenital adrenal hyperplasia which was confirmed later by performing short Synacthen test. Patient and her parents were counseled regarding the diagnosis and clitoroplasty was done and prednisolone 5 mg daily at night in reverse circadian rhythm started. After 3 months of treatment, her hirsutism significantly reduced and menstruation had begun.

Key words: clitoromegaly, congenital adrenal hyperplasia, hirsutism, non-classical congenital adrenal hyperplasia, short Synacthen test.

(*BIRDEM Med J* 2020; 10(3): 204-206)

Introduction

Congenital adrenal hyperplasia (CAH) are inherited defect of cortisol biosynthesis, occurs due to 21-hydroxylase deficiency in 95% cases and shows a wide range of clinical severity.¹ The clinical phenotype is typically classified as classic, severe form or non-classic, mild or late-onset form. Classic CAH is sub-classified as salt-losing or non-salt-losing (simple virilising), reflecting the degree of aldosterone deficiency. Data

from close to 6.5 million new-born screenings worldwide indicate that classical CAH occurs in 1:13,000 to 1:15,000 live births. Non-classical 21-OHD detected in 1:100 of certain population, may be diagnosed on genital ambiguity in affected females and/or later on the occurrence of androgen excess in both sexes.²

Case report

An 11-year-old girl presented with enlargement of external genitalia, excessive growth of hair in pubis, axilla, face and lower limbs along with growth spurt, excessive sweating and deepening of voice for 4 years. She was born of consanguineous marriage, at term by vaginal delivery at home without any perinatal complication. There was no history of maternal virilization or any drug intake by mother during pregnancy and no family history of such conditions. The child did not have history of salt crisis or failure to thrive. The developmental milestones were normal and the child had an average scholastic performance. On examination, normal body habitus, excessive hair

Author information

- Aleya Ferdush Monni, Rezwana Sobhan, MD Phase-B Resident, Endocrinology and Metabolism, BIRDEM General Hospital, Dhaka, Bangladesh.
- Md. Faruque Pathan, Professor, Department of Endocrinology, BIRDEM General Hospital, Dhaka, Bangladesh.
- Faria Afsana, Assistant Professor, Department of Endocrinology, BIRDEM General Hospital, Dhaka, Bangladesh
- Feroz Amin, Associate Professor, Department of Endocrinology, BIRDEM General Hospital, Dhaka, Bangladesh.

Address of correspondence: Aleya Ferdush Monni, MD Phase-B Resident, Endocrinology and Metabolism, BIRDEM General Hospital, Dhaka, Bangladesh. Email: aleyaferdush.monni@yahoo.com

Received: February 5, 2020

Accepted: June 30, 2020

growth were noted over upper lip, chin (Figure 1) and thighs (Figure 2). Distribution and extent of hirsutism assessed by modified Ferriman-Gallway score was 8, suggestive of moderate hirsutism. Acanthosis nigricans was found in neck and axillary region. Tanner staging revealed stage-II breast development and stage IV female pattern pubic hair. Genitalia examination showed clitoromegaly index 750mm² along with normal labia majora, minora and urethral position and intact vaginal orifice.

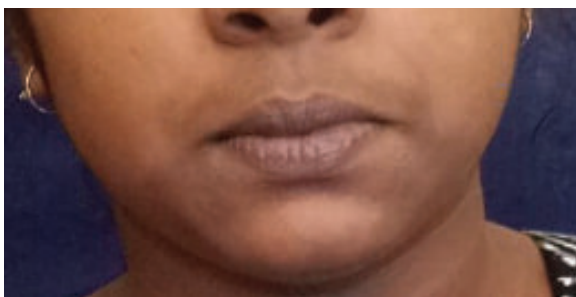


Figure 1 Excessive hair growth in upper lip and chin

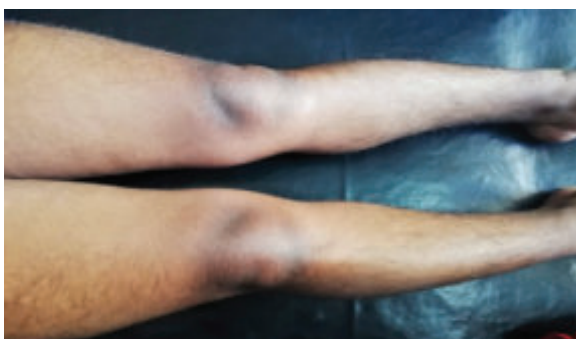

Figure 2 Excessive hair growth in thigh

Chromosomal analysis showed a normal female 46XX karyotype. Ultrasonography showed normal uterus and bilateral ovaries (right 4.2 cc and left 5 cc). There was no detectable ovarian or adrenal mass. X-ray for bone age was 15 years suggestive of bone age advancement indicates pseudo prepubertal puberty. The diagnosis of non-classical congenital adrenal hyperplasia was suspected clinically and based on biochemical findings. S. Testosterone, DHEA-S, 17 α hydroxyl-progesterone (17 α -OHP), an intermediate product in the biosynthesis of cortisol was marginally elevated (Table I) and further increased after short Synacthen test, but S. cortisol was not increased (Table II).

Table I Hormone analysis of the patient

Hormones	Results	Normal value
S. Testosterone (ng/ml)	1.05	0.15-0.9
17-OH progesterone (ng/ml)	2.77	0.10-0.80
DHEA-S(ig/dl)	240.01	5.00-40.00
DHEA(ng/ml)	8.00	1.3-9.8
Serum oestradiol (pg/ml)	43.76	20-400
FSH (mIU/ml))	3.76	3.03-8.08
LH (mIU/ml)	1.78	1.80-11.78

Table II Short Synacthen test result

Test	0 min	30 min	60 min	Normal value
ACTH (pg/ml)	79			7-53
Cortisol (nmol/L)	232.72	189.33	181.15	101-690
17 OH Progesterone (ng/ml)	2.77	16.00	17.00	0.10-0.80

Patient and her parents were counseled regarding the disease and consequences. We have started prednisolone 5 mg daily at night in reverse circadian rhythm which would suppress further adrenocorticotropic hormone (ACTH) production, virilization and she underwent reconstructive surgery for clitoromegaly. After 3 months of treatment, her hirsutism significantly reduced and menarche appeared.

Discussion

CAH is a family of autosomal recessive disorders of cortisol biosynthesis. The pathophysiology relates primarily to decreased cortisol production, which stimulates a compensatory increase in ACTH, causing increased level of steroid hormone proximal to the enzyme block seeking alternative metabolic pathway, resulting in increased androgen.³ 21-hydroxylase deficiency is caused by mutations in the CYP21 gene encoding the steroid 21-hydroxylase enzyme.³ Non-classical 21-hydroxylase deficiency refers to the condition in which partial deficiencies of 21-hydroxylation permits a late onset, a less extreme hyperandrogenism and milder clinical symptoms or even no symptom at all. They are expressed as non-specific hyperandrogenism in females, particularly in the peripubertal period and more rarely of pseudo-precocious

puberty in children of both sexes. The clinical signs (premature pubarche, tall stature and advanced bone age, menstrual disturbances, infertility, slowly progressive hirsutism, acne) occur in later childhood, adolescence or after puberty. Short Synacthen test constitutes the gold standard test for obtaining an accurate diagnosis of non-classical CAH. After measuring the serum 17-OHP, a single dose (0.25 mg) of Synacthen injection is performed. Concentration of 17-OHP concentration above 1500 ng/dl confirms the diagnosis of CAH.⁴ Treatment for CAH is aimed at providing sufficient amount of glucocorticoid, to reduce excessive ACTH.

Conclusion

Early diagnosis and treatment help to promote normal growth and development by providing sufficient hormone to minimize adrenal sex steroids production

while minimizing the consequences of glucocorticoid excess.

Conflicts of interest: Nothing to declare.

References

1. Deborah P. Merke. Approach to the adult with congenital adrenal hyperplasia due to 21-hydroxylase deficiency. *J Clin Endocrinol Metab* 2008 Mar; 93(3): 653-60.
2. Forest MG. Recent advances in the diagnosis and management of congenital adrenal hyperplasia due to 21-hydroxylase deficiency. *Human Reproduction Update* 2004;10(6):469–85.
3. New MI, Lekarev O, Parsa A, Yuen T, O'Malley B, Hammer G, eds. *Genetic Steroid Disorders*. San Diego, CA. Elsevier 13.
4. Hindmarsh PC. Management of the child with congenital adrenal hyperplasia. *Best Pract Res Clin Endocrinol Metab* 2009;23(2):193-208.