

# A tale of an unfortunate outcome in COVID-era

Haque TSU<sup>a</sup>, Jahan I<sup>b</sup>, Rahim MA<sup>c</sup>, Chowdhury TA<sup>d</sup>, Ananna MA<sup>c</sup>, Iqbal S<sup>e</sup>

### ABSTRACT

*Autosomal dominant polycystic kidney disease (ADPKD) primarily affects the kidneys; cysts can develop in other organs like liver and pancreas and sometimes complicated with formation of arterial aneurysms, brain being the commonest site. Aortic aneurysms can lead to thromboembolic events. Thromboembolism is also a recognized complication of coronavirus disease 2019 (COVID-19). Here, we present case history of an elderly diabetic, hypertensive patient with bilateral renal stones, who presented with gangrene of the left 5th toe and raised serum creatinine. He was later diagnosed as a case of COVID-19, ADPKD with aortic aneurysm, which was complicated with intraluminal thrombus formation and unfortunately, he died in course of treatment.*

**Key words:** Autosomal dominant polycystic kidney disease, aortic aneurysm, COVID-19.

*(BIRDEM Med J 2020; 10, COVID Supplement: 115-119)*

### INTRODUCTION

Patients with adult polycystic kidney disease (ADPKD) may pass unnoticed; hypertension is a common presentation, patients may present with chronic kidney disease, renal stones, arterial aneurysms and rarely thromboembolic phenomena. Long segment and large aortic aneurysms merit open surgery or endovascular repair. Ureteric stones need to be removed to prevent hydro-uretero-nephrosis. Routine surgeries and interventions need a negative reverse transcriptase polymerase chain reaction (RT-PCR) report for severe acute respiratory syndrome coronavirus 2 (SARS-CoV-2) by most healthcare facilities amid the coronavirus disease 2019 (COVID-19) pandemic, thus hampering

routine treatment for non-COVID illness. Here, we report a case of incidental diagnosis of ADPKD with aortic aneurism, bilateral renal and left ureteric stone, who presented with an ischemic toe, tested positive for SARS-CoV-2 and suddenly died while awaiting intervention.

### CASE REPORT

A 68-year-old man, diagnosed case of hypertension and bilateral renal stones, with background history of right nephrolithotomy, presented with a two-week history of pain and blackening of the left 5<sup>th</sup> toe. He initially consulted in a local health facility, where he was diagnosed as having diabetes mellitus and raised serum creatinine level (3.1 mg/dl). His pain was constant and gradually deteriorating and did not respond to paracetamol. He denied any local injury, fever, palpitation and arthritis. His antihypertensive drug (olmesartan) was changed to cilnidipine.

Initial assessment at our center revealed that he had anemia and bipedal oedema. The left 5<sup>th</sup> toe was darker, tender with raised local temperature and intact peripheral pulses. Abdominal examination revealed a previous open nephrolithotomy scar and 2-cm hepatomegaly below the right subcostal margin. Other systemic examination findings were unremarkable.

Laboratory evaluation showed anemia (Hb 9.2 gm/dl) and thrombocytopenia (1,12,000/cmm), urine routine examination revealed proteinuria (+) but no hematuria. Renal function revealed further deterioration (serum

### Author information

- Talha-Sami-UI-Haque, Resident Medical Officer, Department of Nephrology, BIRDEM General Hospital, Dhaka, Bangladesh.
- Ishrat Jahan, Assistant Registrar, Department of Nephrology, BIRDEM General Hospital, Dhaka, Bangladesh.
- Muhammad Abdur Rahim, Mehruba Alam Ananna, Associate Professor, Department of Nephrology, BIRDEM General Hospital, Dhaka, Bangladesh.
- Tufayel Ahmed Chowdhury, Assistant Professor, Department of Nephrology, BIRDEM General Hospital, Dhaka, Bangladesh.
- Sarwar Iqbal, Professor, Department of Nephrology, BIRDEM General Hospital, Dhaka, Bangladesh.

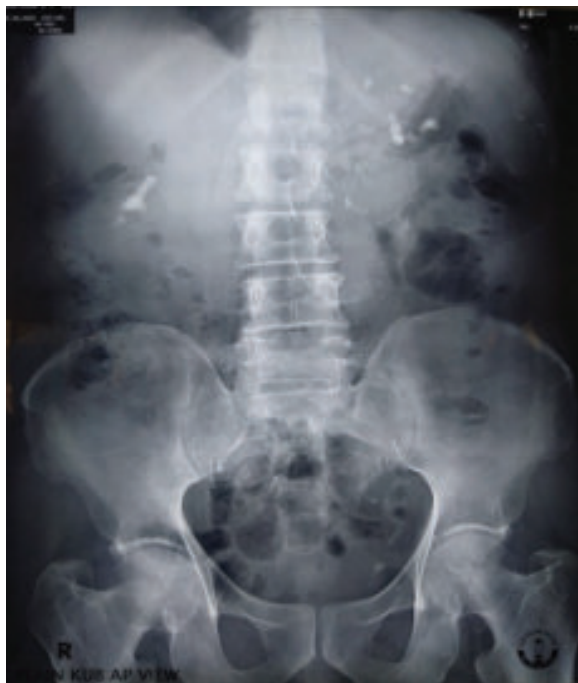**Address of correspondence:** Talha-Sami-UI-Haque, Resident Medical Officer, Department of Nephrology, BIRDEM General Hospital, Dhaka, Bangladesh. Email: drsami747@yahoo.com

**Received:** December 1, 2020

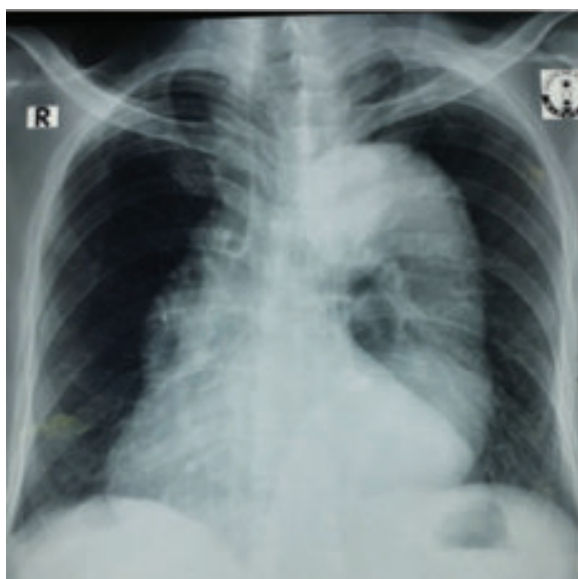**Revision received:** December 10, 2020

**Accepted:** December 10, 2020

creatinine 3.3 mg/dl and urea 90 mg/dl). Doppler study of lower limb vessels showed atherosclerotic changes with minimal (10-20%) flow reduction. Bilateral renal stones were present in x-ray (Figure 1) and chest x-ray showed widening of mediastinal silhouette with widening of aortic knob (Figure 2).

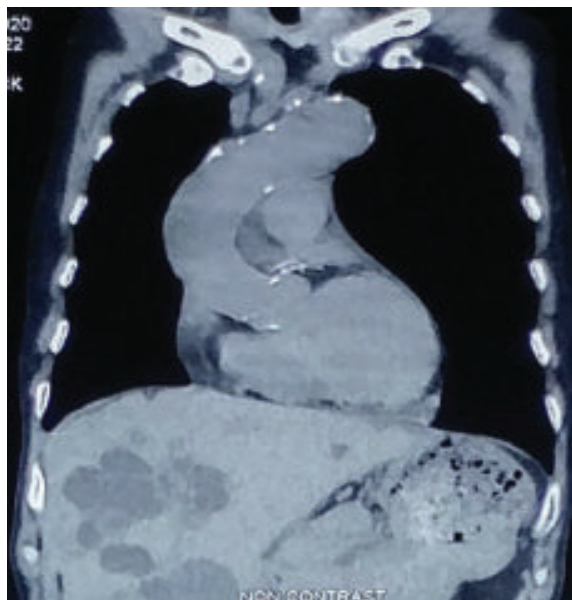


**Figure 1** X-ray KUB showing bilateral multiple renal stones

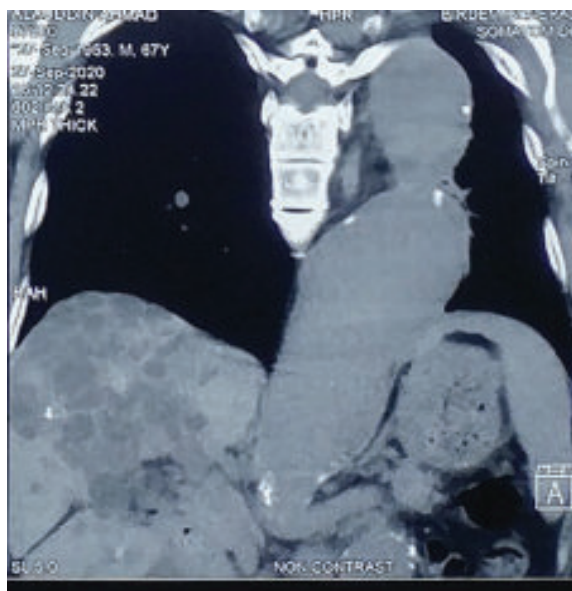


**Figure 2** Chest x-ray showing widening of mediastinal silhouette with widening of aortic knob

An abdominal ultrasonography showed bilateral renal parenchymal disease, bilateral renal stones, bilateral renal and hepatic cysts. Computed tomography (CT) scan of chest revealed aneurysmal dilatation of the aortic arch (4 cm) (Figure 3) and descending thoracic aorta (7 cm) (Figure 4). Non-contrast abdominal CT scan revealed multiple cysts in liver and kidneys, bilateral

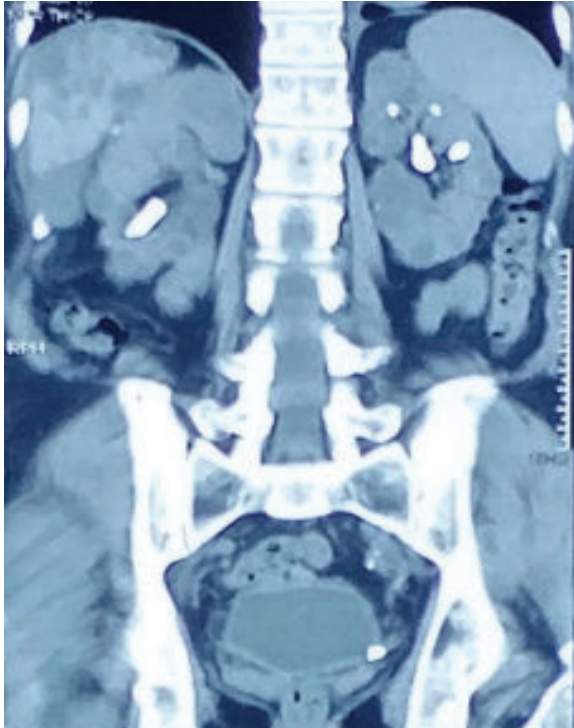


**Figure 3** Computed tomography (CT) scan of chest showing aneurysmal dilatation of the aortic arch



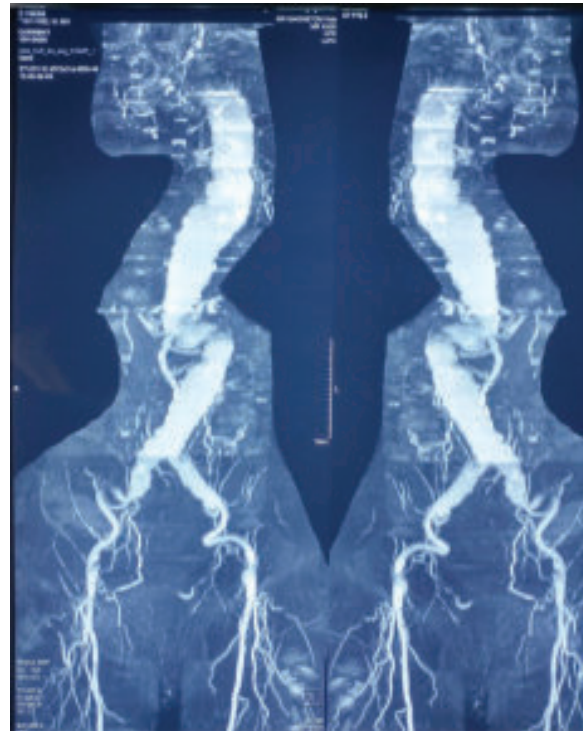
**Figure 4** Computed tomography (CT) scan of chest showing aneurysmal dilatation of the descending thoracic aorta

renal calculi and a left sided ureteric stone at vesico-ureteric junction (Figure 5). Magnetic resonance aortogram (MRA) showed fusiform aneurism in descending thoracic aorta-suprarenal abdominal aorta (17 cm length), infrarenal abdominal aorta (10 cm length) extending to both common iliac arteries (Figure 6) with thrombi (Figure 7) in the wall. Anticoagulation was initiated along with other medication (linagliptin, aspirin, atorvastatin).

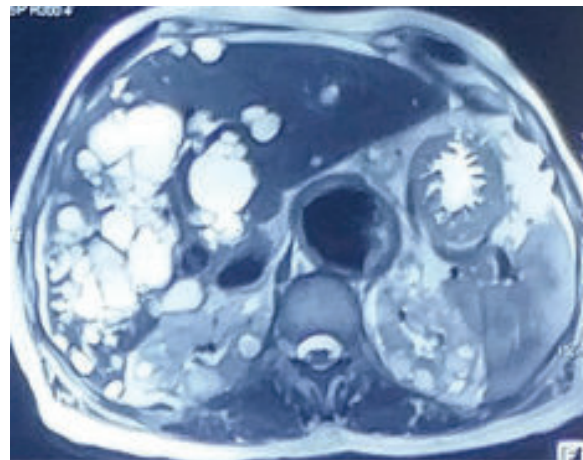


**Figure 5** Non-contrast CT scan of KUB showing multiple cysts in liver and both kidneys, bilateral renal calculi and a left sided ureteric stone at vesico-ureteric junction

Due to extensive aneurysm in both thoracic and abdominal aorta and multiple co-morbidities, vascular surgeon opined for an endovascular repair of aortic aneurysm after improvement of renal function. Cystoscopy with left sided D-J stenting was planned and as prerequisite, RT-PCR for SARS-CoV-2 was sent which came positive. Patient was referred to a COVID-dedicated hospital and was managed accordingly. One-month later, while awaiting cystoscopy, patient suddenly collapsed at bathroom without any preceding feature suggesting impending aneurysm rupture or shock and died.



**Figure 6** Magnetic resonance aortogram (MRA) showing fusiform aneurism in descending thoracic aorta-suprarenal abdominal aorta, infrarenal abdominal aorta extending to both common iliac arteries



**Figure 7** Magnetic resonance aortogram (MRA) showing intraluminal thrombi in aortic aneurysm

## DISCUSSION

ADPKD is a common disorder and less than half of these cases are diagnosed during life; most diagnoses are incidental, as the disease is often clinically silent.<sup>1</sup> It is associated with an increased incidence of

cardiovascular abnormalities including dilatation and formation of vascular aneurysms.<sup>2</sup> Different types of vascular manifestations have been reported in ADPKD such as aneurysms and/or dissections, predominantly involving the intracranial arteries but also the aorta, vertebral and coronary arteries.<sup>3-5</sup> The presence of this wide array of vascular abnormalities has led to the hypothesis that polycystins, the proteins encoded by the PKD genes, expressed in vascular smooth muscle cells, might be required to maintain vascular integrity.<sup>6-9</sup> Though some studies did not find any association between ADPKD and aortic aneurysm,<sup>10</sup> others find that there was increased incidence of aortic aneurysm in patients with ADPKD ranging from 5-9.7% of patients.<sup>11-15</sup>

The pathogenesis is still not clear; why some ADPKD patients developed aortic aneurysm and other do not. Whether the renal disease itself causes aortic aneurysm or is associated with the fact that many of these patients have hypertension, atherosclerosis and may be undergoing renal replacement therapy.

Other than atherosclerosis, the index case had hypertension, diabetes mellitus, dyslipidemia; all may contribute to aneurysm formation. Aortic aneurysm can also cause thrombosis with subsequent embolization due to disruption of the endothelium associated with degradation and destabilization of the aortic wall. In 70–80% of abdominal aortic aneurysm patients, the vessel wall is covered by an intraluminal thrombus, though it generally does not preclude blood flow.<sup>16-17</sup> Other than these causes, in current situation, COVID-19 is another factor, that is contributing in development of arterial thrombosis.<sup>18</sup>

In this case, though initially the cause of gangrene on left 5<sup>th</sup> toe was thought to be due to diabetic foot, after a complete work-up, distal embolization from the intraluminal thrombus of aortic aneurysm was most likely the cause of gangrene. Cause of death in this patient is uncertain. It might be due to sudden rupture of aortic aneurysm or sudden cardiovascular event like myocardial infarction, a massive systemic or pulmonary embolism could also be a cause, as the patient was infected by SARS-CoV-2. A post mortem medical autopsy would be an option to find the cause.

**Authors' contribution:** TSUH managed the patient and drafted the manuscript. IJ managed the case. MAR

did literature search, guided manuscript preparation, edited manuscript. TAC, MAA supervised managing patient. SI was the overall supervisor. All authors read and approved final manuscript for submission.

**Conflicts of interest:** Nothing to declare.

## REFERENCES

1. Davies F, Coles GA, Harper PS, Williams AJ, Evans C, Cochlin D. Polycystic kidney disease re-evaluated: a population-based study. *Q J Med.* 1991 Jun;79(290):477-85.
2. Leier CV, Baker BP, Kilman JW, Weoley CF. Cardiovascular abnormalities associated with polycystic kidney disease. *Ann Intern Med* 1984; 100: 683-8.
3. Biagini A, Maffei S, Baroni M, Piacenti M, Terrazzi M, Paoli F, et al. Familiar clustering of aortic dissection in polycystic kidney disease. *Am J Cardiol* 1993; 72: 741-2.
4. Menon A, Sachithanandan A, Singh H, Bhatt R, Lewis ME, Bonser RS. Simultaneous aortic valve and arch replacement with bilateral nephrectomy for massive polycystic kidney disease, aortic regurgitation and dissecting aneurysm. *Ann Thorac Surg* 2011; 91: 919-20.
5. Lee CC, Chang WT, Fang CC, Tsai IL, Chen WJ. Sudden death caused by dissecting thoracic aortic aneurysm in a patient with autosomal dominant polycystic kidney disease. *Resuscitation* 2004; 63: 93-6.
6. Perrone RD, Malek AM, Watnick T. Vascular complications in autosomal dominant polycystic kidney disease. *Nat Rev Nephrol* 2015; 11: 589-98.
7. Kim K, Drummond I, Ibrahimov-Beskrovnyaya O, Klinger K, Arnaout MA. Polycystin 1 is required for the structural integrity of blood vessels. *Proc Natl Acad Sci USA* 2000; 97: 1731-6.
8. Griffin MD, Torres VE, Grande JP, Kumar R. Vascular expression of polycystin. *J Am Soc Nephrol* 1997; 8: 616-26.
9. Qian Q, Li M, Cai Y, Ward CJ, Somlo S, Harris PC, et al. Analysis of the polycystins in aortic vascular smooth muscle cells. *J Am Soc Nephrol* 2003; 14: 2280-7.
10. Hossack KF, Leddy CL, Johnson AM, Schrier RW, Gabow PA. Echocardiographic findings in autosomal dominant polycystic kidney disease. *N Engl J Med* 1988; 319: 907-12.
11. Chapman JR, Hilson AJW. Polycystic kidneys and abdominal aortic aneurysms. *Lancet* 1980; 1:647-8.
12. Goeau-Brissonniere O, Renler JF, Bacourt F. Abdominal aortic aneurysms associated with aortic hypoplasia and polycystic kidneys. *Vasc Surg* 1990; 12: 504.
13. Montollu J, Torras A, Revert L. Polycystic kidneys and abdominal aortic aneurysms. *Lancet* 1980; 1: 1133-4.
14. Roodvoets AP: Aortic aneurysms in presence of kidney disease. *Lancet* 1980; 1:1413-141

15. Okamoto Y, Awzu A, Ono K, Nakayama K, Yamada K. Surgical treatment of abdominal aneurysms in hemodialysis patient with polycystic kidney. *Arch Jpn Chir* 1983; 52: 718-24.
16. O'Leary SA, Kavanagh EG, Grace PA, McGloughlin TM, Doyle BJ. The biaxial mechanical behaviour of abdominal aortic aneurysm intraluminal thrombus: classification of morphology and the determination of layer and region-specific properties. *J Biomech* 2014 Apr 11; 47(6): 1430-7.
17. Vorp DA, Mandarino WA, Webster MW, Gorcsan J 3rd. Potential influence of intraluminal thrombus on abdominal aortic aneurysm as assessed by a new non-invasive method. *Cardiovasc Surg* 1996 Dec; 4(6): 732-9.
18. Cheruiyot I, Kipkorir V, Ngure B, Misiani M, Munguti J, Ogeng'o J. Arterial Thrombosis in Coronavirus Disease 2019 Patients: A Rapid Systematic Review. *Ann Vasc Surg* 2020; S0890-5096(20)30767-6.