

# Stapled trans-anal rectal resection for the surgical management of obstructed defecation syndrome: our experience in Bangladesh

Haque AA<sup>a</sup>, Alam H<sup>b</sup>, Talukder MRH<sup>a</sup>

## ABSTRACT

**Background:** Obstructed defecation syndrome (ODS) is one of the commonest constipation related disorders confronted by surgeons in Bangladesh. Stapled transanal rectal resection (STARR) is a novel surgical technique specific for ODS. This study was designed to evaluate the effectiveness of STARR on patients with ODS in Bangladesh.

**Methods:** Thirty (30) female patients (age:  $46 \pm 13.2$  years) with ODS, were selected for this observational study, from July 2016 to July 2019, in a private hospital of Dhaka. Patients were interviewed with standardized questionnaire at study enrolment and up to 3 months postoperatively. Surgical outcome was quantified according to the Longo's Modified ODS score (MODS).

**Results:** At initial consultation, the mean Longo's MODS score was  $17.6 \pm 1.9$ . Mean operative time was  $39 \pm 6.2$  minutes. Commonest complication was 'staple line bleeding' in 24(80%) patients intraoperatively & 'defecatory urgency' in 18(60 %) patients postoperatively. At postoperative 3-month follow-up, statistically significant ( $p < 0.05$ ) symptomatic improvement in Longo's MODS score ( $6.9 \pm 2.5$ ) was observed in 27(90%) patients. Ten (33.3%) of patients judged their final clinical outcome as 'excellent', 11(36.7%) as 'good', and 6(20%) as 'moderate', with 3(10%) having 'poor/no improvement'.

**Conclusion:** After analyzing our results, we conclude that STARR is an effective procedure for the treatment of ODS due to structural abnormalities and can be performed safely without any major morbidity.

**Key words:** magnetic resonance defecogram, obstructive defecation syndrome, stapled trans-anal rectal resection.

(*BIRDEM Med J* 2021; 11(1): 11-16)

## INTRODUCTION

Obstructed defecation syndrome (ODS) is a type of constipation characterized by fragmented stools, need for straining at defecation, sense of incomplete evacuation, tenesmus, urgency, pelvic heaviness and self-digitation. These disorders are frequently

encountered in clinical practice and affect at least 18% of the population.<sup>1</sup> ODS has been treated conservatively for many years by medication, behavioral modification, and biofeedback with mixed success. Previous surgical attempts at correction of the anatomical defects associated with ODS have proved unsuccessful. Surgeons were faced with limited options, some of which resulted into extremely troublesome symptoms. A new surgical technique developed by Prof. Antonio Longo, called Stapled Transanal Rectal Resection (STARR), attempts to correct the anatomical defects associated with ODS, in particular rectocele and rectal intussusception. STARR aims to correct rectocele, resect internal prolapse, restore anatomy, correct rectal volume, and improve function.<sup>2</sup>

### Author information

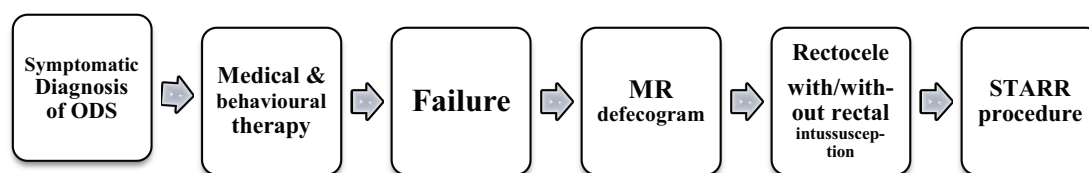
- Asif Almas Haque, Md. Rajibul Haque Talukder, Registrar, Department of Surgery, BIRDEM General Hospital, Dhaka, Bangladesh.
- Hasina Alam, Assistant Professor, Department of Surgery, BIRDEM General Hospital, Dhaka, Bangladesh.

**Address of correspondence:** Asif Almas Haque, Registrar, Department of Surgery, BIRDEM General Hospital, Dhaka, Bangladesh. Email: asifh7000@gmail.com

**Received:** April 1, 2020

**Revision received:** June 30, 2020

**Accepted:** October 31, 2020



**Figure 1** Flow chart for the management of obstructed defecation syndrome

The early studies and observations indicate that STARR may in fact provide significantly better symptomatic resolution in ODS patients rather than conventional treatments.<sup>3-5</sup> However, the impact of clinical studies to evaluate this technique has been limited by variability of results and lack of comparators. Few studies have assessed the efficacy and safety of the STARR procedure in comparison with evidence based conservative treatment for the management of ODS in the same patient. In most cases, follow-up has been too short with patient selection too varied and arbitrary. This study was designed to determine the efficacy and safety of the STARR procedure in the treatment of patients with chronic constipation due to ODS and with clinical evidence of rectocele with/without rectal intussusception.

**METHODS**

From July 2016 to July 2019, thirty (30) female patients with ODS associated with rectocele with or without rectal intussusception were recruited in this observational study, which was performed in Eden Multicare Hospital, a private hospital of Dhaka. Diagnosis was confirmed by MR defecogram. All patients gave their informed written consent before participating in this study.

The primary outcome measure of the study was symptomatic relief of ODS after STARR, according to Longo’s Modified ODS score (Table II).

**Table I** Study type and design

Study type	Observational study
Study design	Allocation: Non-randomized Intervention model: Single group assignment Masking: None (Open-label) Primary purpose: Treatment

All patients had detailed data on preoperative status and perioperative and postoperative complications. A clinical assessment was performed at baseline and at 1, 2, and 3 months after surgery. The magnitude and degree of ODS were quantified by Longo’s Modified ODS score. At follow-up, the patients were interviewed, either face to face or by telephone, with the same standardized questionnaire, which included additional items related to treatment satisfaction and adverse events. Patients were invited to declare whether their outcome was ‘excellent’, ‘good’, ‘moderate’ or ‘poor’.

**Statistical analysis**

Results were reported as means and standard deviation (mean ± SD). Descriptive statistical techniques were used to compare the two groups of patients. It was performed using paired t-test for continuous variables and Wilcoxon’s signed-rank test for quantitative variables. A p value < 0.05 was considered statistically significant. Data were processed manually and analysed with the help of Microsoft Excel Version 14.7.

**Table II** Longo’s modified obstructed defecation syndrome score

Presenting symptoms	Scores			
	0	1	2	3
Medication for defecation	Never	<1 x/week	1x”6x/ week	Daily
Difficult evacuation	Never	<1 x/week	1x”6x/ week	Daily
Digitation	Never	<1 x/week	1x”6x/ week	Daily
Return to toilet for evacuation	Never	<1 x/week	1x”6x/ week	Daily
Feeling of incomplete evacuation	Never	<1 x/week	1x”6x/ week	Daily
Straining during evacuation	Never	<1 x/week	1x”6x/ week	Daily
Duration of evacuation	<5 minutes	6-10 minutes	11-20minutes	>20minutes
Negative influence of quality of life (QoL)	NO	Mild	Moderate	Signifi-cant
Total Score (0 to maximal 24 points)				

**RESULTS**

During the period between July 2016 to July 2019, thirty (30) female patients (mean age:  $48.6 \pm 13.2$  years; range: 27–70 years) with ODS associated with rectocele with/without rectal intussusception, were included in this observational study. All patients had been followed up for 3 months postoperatively.

Rectocele was present in all 30(100%) patients, and 22(73%) patients had internal rectal prolapse / rectal intussusception. All patients had symptoms of ODS according to Longo's modified ODS score.

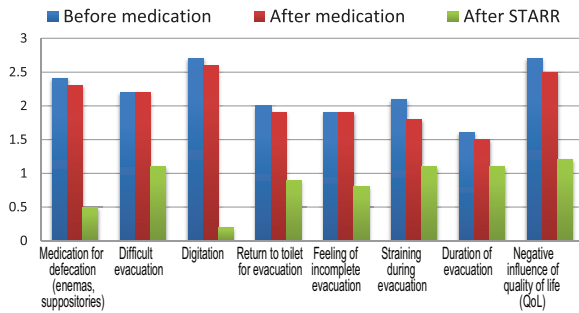
At initial consultation i.e. before any treatment, the mean total score was  $17.6 \pm 1.9$ . Following conservative treatment with medication, score was  $16.7 \pm 1.9$  ( $p > 0.05$ ) and 3 months after STARR procedure, score was  $6.9 \pm 2.5$  ( $p < 0.05$ ) (Table III, IV).

**Table III** Presenting symptoms according to Longo's modified obstructed defecation syndrome score of patients before and after medical treatment

Presenting symptoms	Before medical therapy	After medical therapy	p value
	(Mean + SD)A	(Mean + SD)B	
Medication for defecation	2.4 + 0.1	2.3 + 0.3	$p > 0.05$
Difficult evacuation	2.2 + 0.2	2.2 + 0.2	$p > 0.05$
Digitation	2.7 + 0.2	2.6 + 0.4	$p > 0.05$
Return to toilet for evacuation	2 + 0.4	1.9 + 0.2	$p > 0.05$
Feeling of incomplete evacuation	1.9 + 0.3	1.9 + 0.1	$p > 0.05$
Straining during evacuation	2.1 + 0.3	1.8 + 0.2	$p > 0.05$
Duration of evacuation	1.6 + 0.3	1.5 + 0.3	$p > 0.05$
Negative influence of quality of life (QoL)	2.7 + 0.1	2.5 + 0.3	$p > 0.05$
Total Score (0 to maximal 24 points)	17.6 + 1.9	16.7 + 2.0	$p > 0.05$

**Table IV** Presenting symptoms according to Longo's modified obstructed defecation syndrome score of patients before medical treatment and 3 months after STARR

Presenting symptoms	Initial consultation	3 months after STARR	p value
	(Mean + SD)A	(Mean + SD)C	
Medication for defecation	2.4 + 0.1	0.5 + 0.2	$p < 0.05$
Difficult evacuation	2.2 + 0.2	1.1 + 0.3	$p < 0.05$
Digitation	2.7 + 0.2	0.2 + 0.1	$p < 0.05$
Return to toilet for evacuation	2 + 0.4	0.9 + 0.2	$p < 0.05$
Feeling of incomplete evacuation	1.9 + 0.3	0.8 + 0.4	$p < 0.05$
Straining during evacuation	2.1 + 0.3	1.1 + 0.3	$p < 0.05$
Duration of evacuation	1.6 + 0.3	1.1 + 0.6	$p > 0.05$
Negative influence of quality of life (QoL)	2.7 + 0.1	1.2 + 0.4	$p < 0.05$
Total Score (0 to maximal 24 points)	17.6 + 1.9	6.9 + 2.5	$p < 0.05$



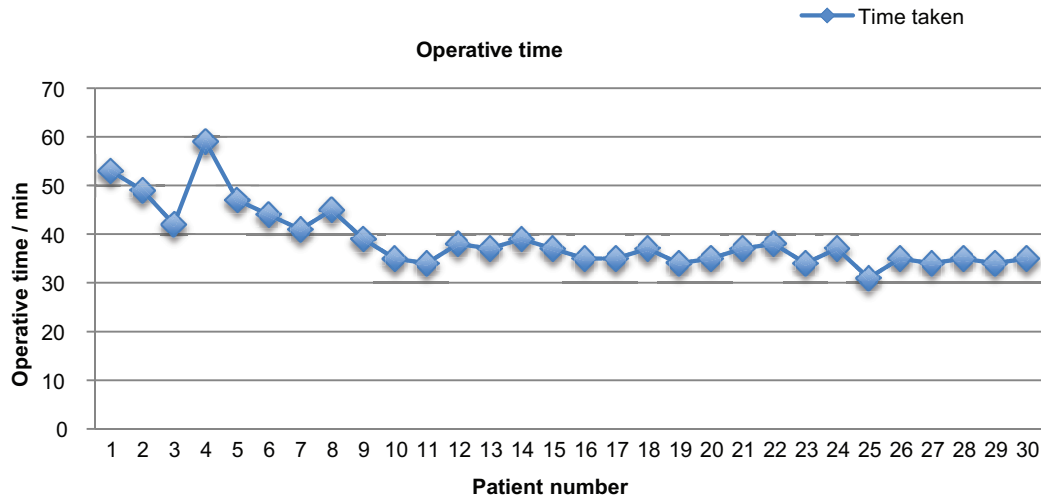
**Figure 2** Presenting symptoms according to Longo's modified obstructed defecation syndrome score of patients before and after medical treatment and 3 months after STARR

This study evaluated, over a 3-month period, the outcome of STARR treatment for ODS, defined with standardized and validated criteria. 27 (70%) patients were classified as responders. ODS by the Longo's Modified ODS score decreased significantly (17.6 + 1.9 vs. 6.9 + 2.5;  $P < 0.05$ ). However, constipation

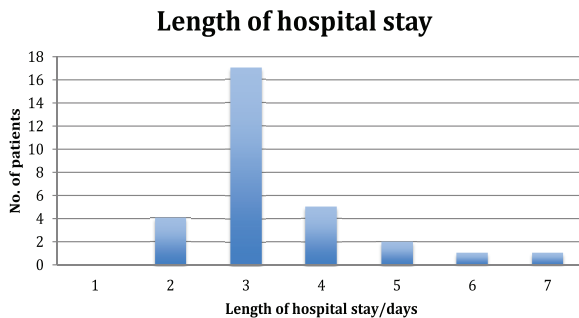
persisted or no improvement was seen in 3 patients following STARR procedure (Figure 2).

Analysis of pre-operative symptoms found that patients who self-digitate (2.7+0.2 vs. 0.2+0.1), used medication (2.4+0.1 vs.0.5+0.2) or had sense of incomplete evacuation (1.9+0.3 vs. 0.8+0.4), had the most significant ( $p < 0.05$ ) subjective symptomatic improvement postoperatively. On the other hand, the least improvement was seen in patients with prolonged duration of evacuation (1.6+0.3 vs. 1.1+0.6). Ultimately, there was a substantial improvement in the quality of life score (2.7+0.1 vs. 1.2+0.4).

The mean operative time (Figure 3) was 39 minutes (highest-59 mins, lowest - 31mins), and the mean hospital stay (Figure 4) was about 3 (ranging from 2 to 7) days. In all cases specimen was sent for histopathology. Rectal smooth muscle fiber with some mesorectal fat was found in all the specimens. The only intraoperative complication was moderate bleeding from



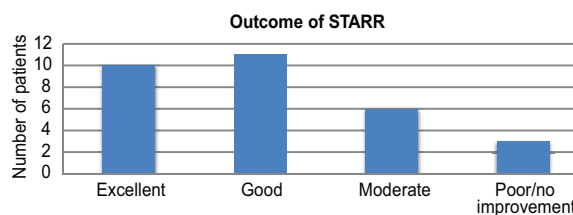
**Figure 3** Operative time



**Figure 4** Length of hospital stay of study participants

the anastomotic ring, which occurred in 24(80%) of cases and was successfully secured with hemostatic stitches. The most common morbidity after surgery was defecatory urgency, and the incidence was 18(60%) during the first postoperative week, which decreased to 2(6.7%) after three months' follow-up. Postoperative bleeding occurred in 3(10%) patients, but it was minor and stopped spontaneously with conservative treatment with no further surgical intervention required. Other recorded complications were incontinence to flatus in 3(10%) patients, acute urinary retention in 1(3.3%) patients and persistent postoperative pain in 2(6.7%)

patients. No staple line dehiscence, profuse rectal hemorrhage, rectovaginal fistula, perianal sepsis and no postoperative mortality recorded (Table V). Defecatory urgency and frequent stools were universally reported with resolution in most by 3<sup>rd</sup> month except for 2 ladies who continued to have rectal urgency. Two (2) patients were found to have a soft stricture at the routine follow up at 1<sup>st</sup> month. The stricture was dilated digitally and he was fine at 3<sup>rd</sup> month follow up.



**Figure 5** Subjective evaluation of outcome of STARR

**Table V** Postoperative complications of study participants

Post-operative complications	1 <sup>st</sup> week	1 <sup>st</sup> month	2 <sup>nd</sup> month	3 <sup>rd</sup> month
Defecatory urgency	18(60%)	11(37%)	2(6.7%)	2(6.7%)
Post-operative bleeding	3(10%)	0	0	0
Acute urinary retention	1(3.3%)	0	0	0
Incontinence to flatus	3(10%)	3(10%)	0	0
Pain	2(6.7%)	0	0	0
Anal fissure	0(0%)	0	0	0

After 3-month follow up 10 patients (33%) judged their final clinical outcome as 'excellent', 11 patients (37%) as 'good', 6 patients (20%) as 'moderate', with only 3 patients (10%) having 'poor' results (Table VI, Figure 5).

**Table VI** Subjective evaluation outcome of STARR

Patient satisfaction	No. of patients	Percentage
Excellent	10	33.3%
Good	11	36.7%
Moderate	6	20%
Poor/no improvement	3	10%

## DISCUSSION

ODS is a challenging clinical problem, the pathophysiology of which is not clearly defined. Rectocele & rectal intussusception, are the two most frequent anatomic defects associated with ODS. Patients were mostly treated conservatively with diet and biofeedback therapy, until the development of the STARR technique.

A multicentric study done by Stuto et al.<sup>6</sup> demonstrated that STARR is technically simple to perform and able

to revert all constipation symptoms. Also, the data from our study suggests that more than 70% (21) of our patients had a satisfactory surgical results with improved symptoms of ODS following the STARR procedure, coupled with only few intraoperative and postoperative complications.

The commonest intraoperative incident was bleeding from the staple line, which occurred in 24(80%) of patients, probably due to the overlapping of the staple lines. While the most common morbidity after surgery was defecatory urgency, and the incidence was 18(60%) during the first postoperative week, decreasing to 2(6.7%) at 3-month follow-up. Other published studies have shown that defecatory urgency was the most common complaint in the immediate and intermediate recovery periods after STARR.<sup>5,7</sup> Although the exact etiology of defecatory urgency is unclear, it may reflect the inflammatory response related to the staple line, presence of irritable rectum, and reduced rectal capacity or compliance. Few studies reported the incidence of severe complications such as staple line dehiscence, rectal diverticulum, pelvic infection, and even fulminating necrotizing pelvic fasciitis following the STARR procedure.<sup>8,9</sup> Incontinence has been claimed to be a potential postoperative drawback of STARR; it

may be a procedure-related complication caused by transient sphincteric impairment during instrumentation and anal dilatation.<sup>10-12</sup> In this study, only 2(6.7%) patients complained of incontinence to flatus during the first two weeks after the procedures and improved within 3 months of surgery. Our results confirmed that the rate of postoperative pain was low and there were no cases of dyspareunia. Frascio et al.<sup>8</sup> in their trial on 30 patients reported no mortality or pelvic sepsis and 4% of postoperative bleeding treated surgically, while in our study postoperative bleeding occurred in 4 (10%) patients, but it was minor and stopped spontaneously with conservative treatment with no further surgical intervention required.

### Limitations

STARR being at its infancy in Bangladesh, previous data on performing such studies were lacking. Our patient population was small, partly because of the extensive selection criteria and due to the high cost of the procedure. Due to the lack of availability MR defecogram and anorectal manometry, we had to be very selective about our patients. Moreover, facilities for biofeedback are not available in Bangladesh, so, comparison of STARR with biofeedback was not possible. The post-operative follow up period (3months) is very short. A longer follow up period of about 12 months would be more informative.

### Conclusions

STARR offers a novel surgical approach to the treatment of patients with obstructed defecation syndrome. Conventional surgeries were least successful in constipated patients perhaps because of the associated rectocele with/without internal intussusception contributing to continuing obstructed defecation. Pre-operative assessment of these patients should be multidisciplinary in nature. Treatment of patients with ODS should include conservative treatment prior to consideration of STARR. Adequate training of colorectal surgeons to perform STARR followed by a period of mentorship should minimize the risk of perioperative complications. Careful patient selection, according to a specific defined criterion, combined with a trained colorectal surgeon performing the operation will result in satisfactory outcomes following STARR.

**Authors' contributions:** AAH diagnosed and managed the cases, collected data, followed-up the

patients, did literature search and drafted the manuscript. MRHT managed and followed-up the case and collected data. HA did literature search and helped in drafting manuscript. All authors read and approved the final manuscript.

**Conflict of interest:** Nothing to declare.

### REFERENCES

1. Drossman DA, Li Z, Andruzzi E. U.S. householder survey of functional gastrointestinal disorders. Prevalence, sociodemography, and health impact. *Dig Dis Sci* 1993;38(9):1569-80.
2. Titu LV, Riyad K, Carter H, Dixon AR. Stapled transanal rectal resection for obstructed defecation: a cautionary tale. *Dis Colon Rectum* 2009; 52(10): 1716-22.
3. Gagliardi G, Pescatori M, Altomare DF. Results, outcome predictors, and complications after stapled transanal rectal resection for obstructed defecation. *Dis Colon Rectum* 2008; 51(2): 186-95.
4. Binda GA, Pescatori M, Romano G. The dark side of double-stapled transanal rectal resection. *Dis Colon Rectum* 2005; 48(9): 1830-2.
5. Corman ML, Carriero A, Hager T. Consensus conference on the stapled transanal rectal resection (STARR) for disordered defecation. *Int J Colorectal Dis* 2006; 8(2): 98-101.
6. Pescatori M, Zbar AP. Reinterventions after complicated or failed STARR procedure. *Int J Colorectal Dis* 2009; 24(1): 87-95.
7. Ram E, Alper D, Atar E, Tsitman I, Dreznik Z. Stapled transanal rectal resection: a new surgical treatment for obstructed defecation syndrome. *Isr Med Assoc J* 2010; 12(2): 74-7.
8. Frascio M, Stabilini C, Ricci B. Stapled transanal rectal resection for outlet obstruction syndrome: results and follow up. *World J Surg* 2008; 32(6): 1110-5.
9. Jayne DG, Schwandner O, Stuto A. Stapled transanal rectal resection for obstructed defecation syndrome: one-year results of the European STARR Registry. *Dis Colon Rectum* 2009; 52:1205-12.
10. Boccasanta P, Venturi M, Salamina G, Cesana BM, Bernasconi F, Roviario G. New trends in the surgical treatment of outlet obstruction: clinical and functional results of two novel transanal stapled techniques from a randomized controlled trial. *Int J Colorectal Dis* 2004; 19: 359-69.
11. Gagliardi G, Pescatori M, Altomare DF, Binda GA, Bottini C, Dodi G et al. Results, outcome predictors and complications after stapled transanal rectal resection for obstructed defecation. *Dis Colon Rectum* 2008; 51: 186-95.
12. Jayne D, Schwander O, Stuto A. STARR for obstructed defaecation syndrome(ODS):12-month follow-up. *Dis Colon Rectum* 2008; 51 (Suppl): 16.