

Heerfordt's syndrome: an uncommon manifestation of sarcoidosis

Ahmed SM^a, Hossain A^a, Azad MR^b, Khan MSH^c, Islam MR^d

ABSTRACT

Heerfordt's syndrome – the combination of facial palsy, parotid swelling, anterior uveitis and fever; is a rare manifestation of sarcoidosis. Here, we present case history of a patient with bilateral lower motor neuron facial nerve palsy, who was found to have bilateral parotid gland swelling and bilateral hilar lymphadenopathy. Computed tomography guided fine needle aspiration cytology from hilar lymph node findings were consistent with sarcoidosis. Subsequently, based on clinical features and cytological findings, the case was diagnosed as incomplete Heerfordt's syndrome.

Key words: facial palsy, Heerfordt's syndrome, sarcoidosis.

(*BIRDEM Med J 2021; 11(1): 67-69*)

INTRODUCTION

Sarcoidosis is a systemic granulomatous disease of unknown aetiology. It usually affects the lungs but any organ maybe involved.¹ Heerfordt's syndrome is described as a part of spectrum of sarcoidosis occurring in approximately 0.3% of sarcoidosis cases.² It presents with fever, uveitis and bilateral parotid gland swelling with unilateral or bilateral facial nerve palsy.³ According to the diagnostic guidelines of sarcoidosis proposed by the Japan Society of Sarcoidosis and other granulomatous disorder in 2006,⁴ Heerfordt's syndrome is classified into complete type, in which all four main symptoms are present and incomplete type, in which two out of the three symptoms facial nerve palsy, parotid gland enlargement and anterior uveitis are detected.

Author information

- Syed Mohaimeen Ahmed, Anika Hossain, Resident Medical Officer, Department of Neurology, BIRDEM General Hospital, Dhaka, Bangladesh.
- Md. Rihan Azad, Assistant Registrar, Department of Neurology, BIRDEM General Hospital, Dhaka, Bangladesh.
- Mohammad Sakhawat Hossen Khan, Registrar, Department of Neurology, BIRDEM General Hospital, Dhaka, Bangladesh.
- Md. Rashedul Islam, Assistant Professor, Department of Neurology, BIRDEM General Hospital, Dhaka, Bangladesh.

Address of correspondence: Syed Mohaimeen Ahmed, Resident Medical Officer, Department Neurology, Room No-1417, BIRDEM General Hospital, Shahbag, Dhaka-1000, Bangladesh. Email:syedmidad63@gmail.com

Received: September 9, 2020

Revision received: September 20, 2020

Accepted: September 27, 2020

Although it is a diagnosis of exclusion, a comprehensive analysis is usually performed only for patients who do not respond to treatment.⁵ Long term oral steroids have been used to treat this syndrome with variable response. We herein report a case of a 50-year-old female who presented with bilateral facial nerve palsy, was later found to be a case of Heerfordt's syndrome.

CASE REPORT

A 50-year-old diabetic, hypertensive lady presented with the complaints of inability to close left eye for 14 days and right eye for 11 days. The symptom appeared suddenly and was confined to her left eye initially along with deviation of the angle of the mouth towards right side. However, 3 days later, the problem progressed to involve her right eye and she developed poor articulation and difficulty in chewing food. Upon further detailed query, she complained of low grade fever and non-productive cough for preceding 3 months. There was no history of shortness of breath, allergy, exposure to chemicals, pets or contact with tuberculosis patient. On general examination, her vital signs were within normal limits. Parotid glands were enlarged bilaterally and were firm, non-tender with normal overlying skin (Figure 1). There was no palpable lymphadenopathy. The patient was conscious and oriented but her speech was low pitched with dysarthria. Cranial nerves examination revealed bilateral lower motor neuron facial palsy (Figure 2). Rest of the neurological examination and other systemic examination were normal.

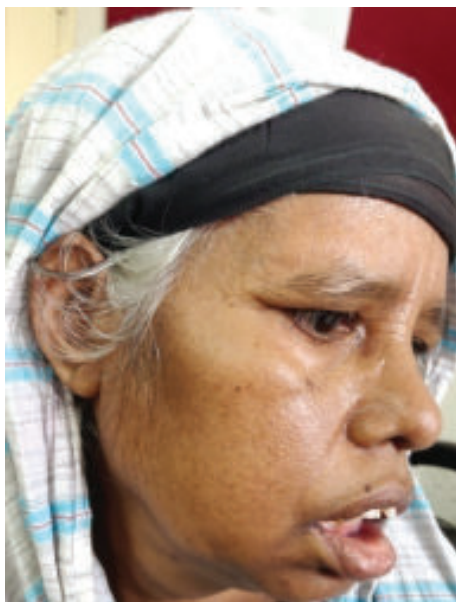

Figure 1 Right sided parotid gland is swollen

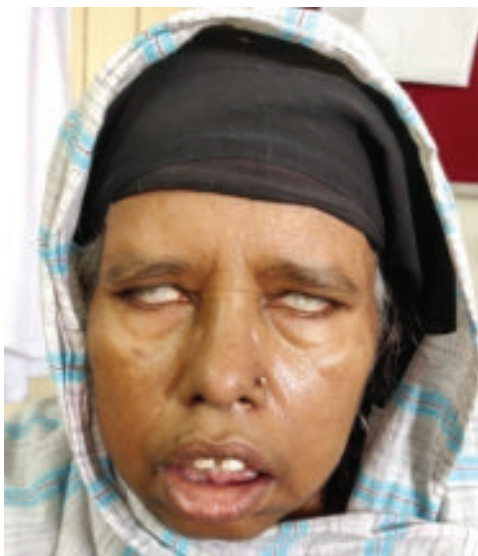

Figure 2 Inability to close both eyes with Bell's phenomenon indicating bilateral lower motor neuron facial nerve palsy

Her laboratory investigations including routine urinalysis, renal function tests, serum electrolytes, calcium, magnesium and electrocardiogram were normal. Glycated hemoglobin (HbA1c) was high (8.4%). Full blood count with erythrocyte sedimentation rate (ESR) showed lymphopenia and high ESR. Her chest x-ray showed bilateral hilar lymphadenopathy (Figure 3).

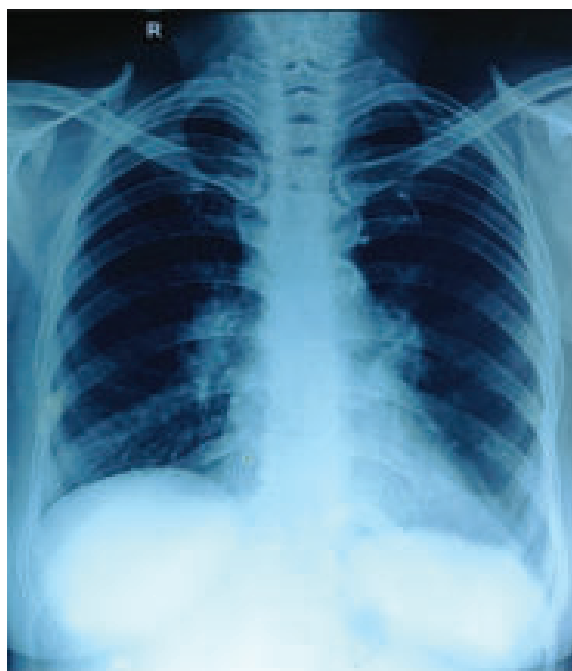

Figure 3 Chest x-ray postero-anterior view showing bilateral hilar lymphadenopathy

Her serum angiotensin-converting enzyme (ACE) level was slightly elevated (66.3 U/L, normal range: 13.3-63.9 U/L). Computed tomography (CT) guided fine needle aspiration from the hilar lymph nodes revealed non-caseating granulomatous inflammation compatible with sarcoidosis (Figure 4). Subsequently, she was diagnosed as a case of incomplete Heerfordt's syndrome because of the absence of anterior uveitis.

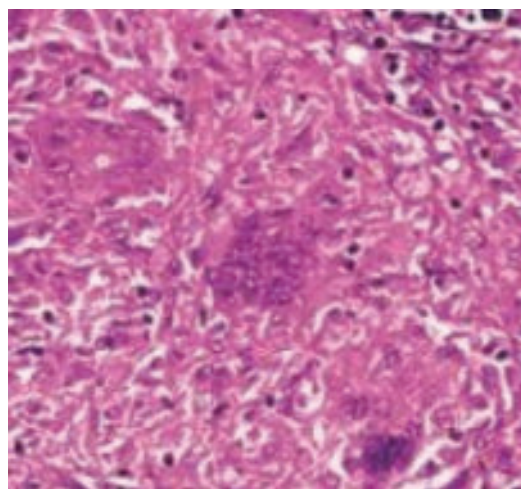


Figure 4 Fine needle aspiration cytology from hilar lymph node showing non-caseating granuloma

Patient was treated with oral steroids, gastro-protection, insulin adjustment for high blood glucose, anti-hypertensive drugs along with proprioceptive neuromuscular fasciculation (PNF) exercise for facial muscles and supportive eye care. On follow-up after 1 month, her serum ACE level was reduced (21.4 U/L) and ESR appeared normal. Although parotid swelling was reduced, she still had residual facial weakness.

DISCUSSION

Heerfordt's syndrome was first described in 1909 by the Danish ophthalmologist, Christian Frederick Heerfordt. The lack of typical presentation of symptoms in cases of Heerfordt's syndrome is a real diagnostic challenge for the treating physician. The incidence of cranial nerve palsy in sarcoidosis is about 5%⁶ with the facial nerve followed by the optic nerve being the common nerves involved.⁷ Facial nerve palsy forms an important defining component of Heerfordt's syndrome. The approximate incidence of facial nerve palsy in this syndrome is 25-50%.⁸ Facial nerve palsy is thought to be the result of direct involvement of the facial nerve branches by the parotid lesion.⁹

The symptoms of our case correspond with the typical diagnosis of incomplete Heerfordt's syndrome. Although elevated serum calcium level was not found, elevated serum ACE level, hilar lymphadenopathy and evidence of non-caseating granuloma on the cytology from hilar lymphnode substantiated the diagnosis. The decline in ACE level after steroid treatment further supported the diagnosis.

Corticosteroids are thought to be the treatment of choice in the management in order to suppress inflammation; though prospective, double-blind clinical trials have not yet been done.¹⁰ Although initial response rates to corticosteroids are high, a relapse of the symptoms may occur during the tapering of the corticosteroid dose. In these cases, immune-suppressants including azathioprine, methotrexate, cyclosporine A and cyclophosphamide are used in combination with the corticosteroid.¹⁰ Heerfordt's syndrome remains underdiagnosed to ambiguous clinical presentation and lack of high degree of suspicion.

Meticulous history taking and clinical examination may point to earlier diagnosis. Since the syndrome presents with facial nerve palsy, a common presenting symptom

in our daily clinical practice, this report aims at taking into account of a strong suspicion for Heerfordt's syndrome which might enable earlier diagnosis, prompt management and lead to a better outcome.

Authors' contribution: SMA managed the case, did literature review and drafted the manuscript. AH did literature search and helped in drafting manuscript. MRA helped in literature search and managing the case. MSHK supervised managing the case and revised the manuscript. MRI diagnosed the case and was in overall supervision. All authors read and approved the final manuscript.

Conflict of interest: Nothing to declare.

Consent: Informed written consent was obtained from the patient for the publication of this case report and any accompanying images.

REFERENCES

1. Fujiwara K, Furuta Y, Fukuda S. Two Cases of Heerfordt's Syndrome: A Rare Manifestation of Sarcoidosis. *Hindawi* 2016; Article ID 3642735.
2. Sugawara Y, Sukayama K, Suda E, Kujihara M, Semba T, Higashimo H, et al. Heerfordt's syndrome initially presenting with subcutaneous mass lesions: Usefulness of gallium-67 scans before and after treatment. *Clin Nucl Med* 2005; 30:732-3.
3. Srirangaramasamy J, Kathirvelu S. A Rare Case of Heerfordt's Syndrome with Bilateral Facial Palsy. *Indian J Otolaryngol Head Neck Surg* 2016; 71(2): 1027-9.
4. Diagnostic standard and guideline for sarcoidosis-2006. *Jpn J of Sarcoidosis and granulomatous disorders [in Japanese]* 2006; 27(1): 89-102.
5. Chappity P, Kumar R, Sahoo AK. Heerfordt's syndrome presenting with recurrent facial nerve palsy: case report and 10 year literature review. *Sultan Qaboos Univ Med J* 2015;15(1):124-8.
6. Burns TM. Neurosarcoidosis. *Arch Neurol* 2003; 60:1166-8.
7. Christofordis GA, Spickler EM, Recio MV, Mehta BM. MR of CNS sarcoidosis: correlation of imaging features to clinical symptoms and response to treatment. *Am J Neuroradiol* 1999; 20: 655-9.
8. Joseph FG, Scolding NJ. Neurosarcoidosis: A study of 30 new cases. *J Neurol Neurosurg Psychiatry* 2009; 80: 297-304.
9. Lower EE, Broderick JP, Brott TG, Boughman RP. Diagnosis and management of neuroradiological sarcoidosis. *Arch Intern Med* 1997; 157(16):1864-8.
10. Segal BM. Neurosarcoidosis: diagnostic approaches and therapeutic strategies. *Curropin Neurol* 2013; 26(3): 307-13.