

# Primary intraosseous meningioma: a case report

Taher MA<sup>a</sup>, Behnom IM<sup>b</sup>, Saha M<sup>b</sup>, Sultana J<sup>c</sup>, Hossain T<sup>d</sup>

### ABSTRACT

*Primary intraosseous meningioma (PIM) is a rare form of meningioma, a benign lesion of the meninges. Imaging evaluation of a patient with frontoparietal scalp swelling revealed an osteoblastic intracalvarial lesion. Following surgical resection, the histological examination revealed an intra-osseous meningioma.*

**Key words:** *primary intraosseous meningioma, computed tomography scan, magnetic resonance imaging, scalp swelling.*

*(BIRDEM Med J 2021; 11(2): 133-136)*

### INTRODUCTION

Meningiomas are extra-axial tumors and represent the most common form of tumor of the meninges. They are non-glial neoplasms, those originate from the meningocytes or arachnoid cap cells of the meninges. These lesions can be located elsewhere, where meninges are found and in some places, where only rest cells are presumed to be located. Intra-osseous meningioma, also referred to as primary intra-osseous meningioma, is a rare subtype of meningioma that accounts for less than 1% of all osseous tumors. They are the most common type of primary extradural meningiomas.<sup>1</sup> Here, we present a case of primary intraosseous meningioma.

### CASE REPORT

A 46-year-old woman presented with a painless scalp swelling of frontoparietal region with no history of

trauma. The swelling was present for last 4 years and had gradually increased in size over the course of about 6 months. Physical examination revealed a swelling of frontoparietal region, about 6 cm in diameter, which was not adhered to overlying skin nor was mobile or tender. The patient had no neurological deficit. The laboratory studies were unremarkable. Radiographs of the skull revealed a well-defined bony lesion in frontoparietal region, involving the diploic space with periosteal new bone formation along the outer table (Figure 1). Non-contrast computed tomography (CT) of head revealed an intradiploic hyperdense mass in superior aspect of frontoparietal region expanding the calvaria, giving sunray spiculation and sclerosis of diploe, inner and outer tables (Figure 2). Magnetic resonance imaging (MRI) showed solitary calvarial mass lesion of aforementioned area that was hypointense on all sequences measured about 8 cm x 3 cm x 2 cm (Figures 3, 5 and 6). Post-Gadolinium images showed enhancement of inner part of the lesion and adjacent meninges (Figure 4). Excision of the intra-osseous part along with removal of involved dura and duroplasty with G-patch and finally cranioplasty with bone cement was done. The specimen was sent for histopathology. Histopathological examination revealed primary intraosseous meningioma. Follow up magnetic resonance imaging showed inflammatory collection at operation site and around G-patch (Figures 7 and 8).

### Author information

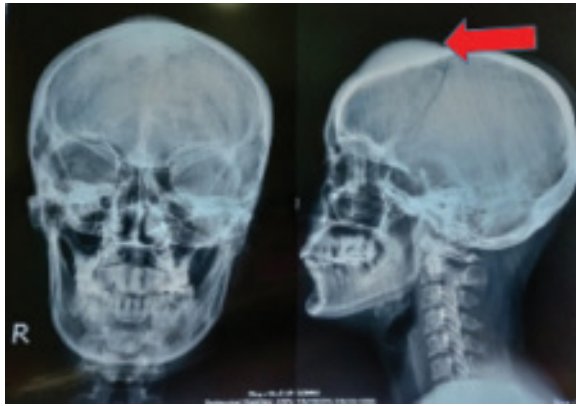
- M A Taher, Professor & Head, Department of Radiology & Imaging, BIRDEM General Hospital, Dhaka, Bangladesh.
- Ishtiaque Mohammad Behnom, Mohua Saha, Resident, Department of Radiology & Imaging, BIRDEM General Hospital, Dhaka, Bangladesh.
- Jafreen Sultana, Associate Professor, Department of Radiology & Imaging, BIRDEM General Hospital, Dhaka, Bangladesh.
- Tasneem Hossain, Resident, Department of Radiation Oncology, National Institute of Cancer Research & Hospital, Mohakhali, Dhaka, Bangladesh.

**Address of correspondence:** M A Taher, Head, Department of Radiology & Imaging, BIRDEM General Hospital, Dhaka, Bangladesh. Email: mataherdr67@gmail.com

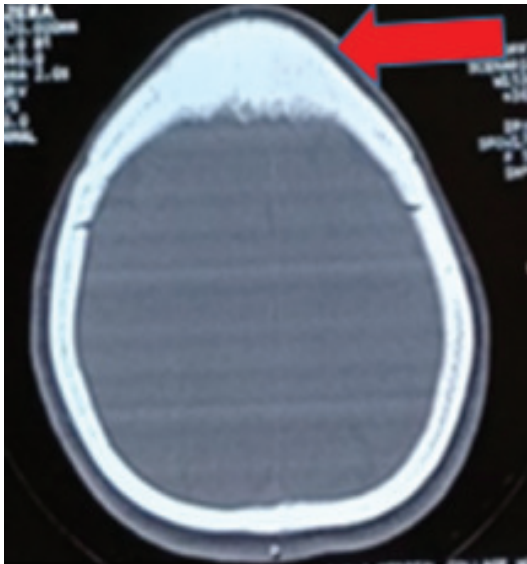
**Received:** November 24, 2020

**Revision received:** February 1, 2021

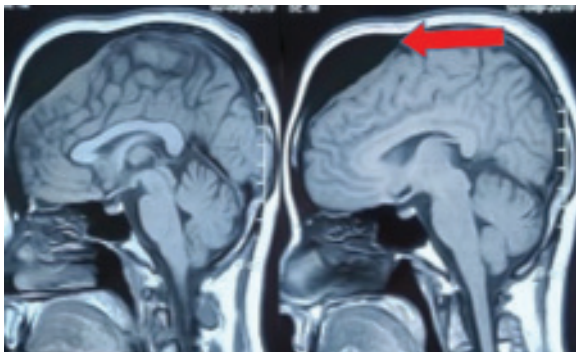
**Accepted:** February 28, 2021



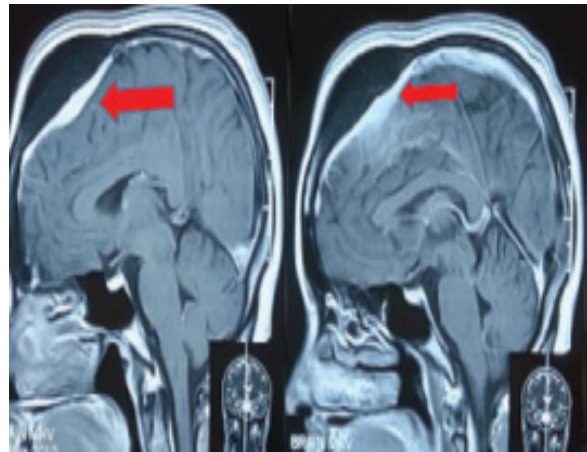
**Figure 1** Frontal and lateral X-ray skull showing frontoparietal osseous lesion



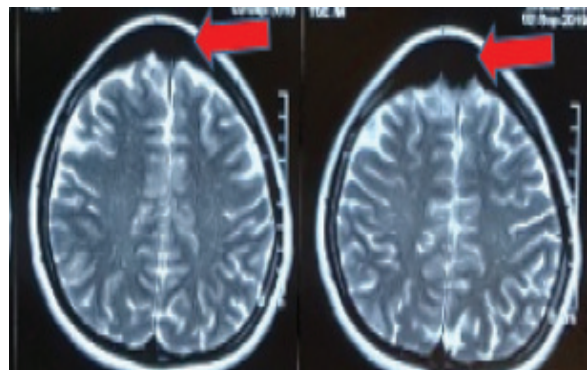
**Figure 2** Non-contrast computed tomography scan showing hyperdense frontal bony lesion



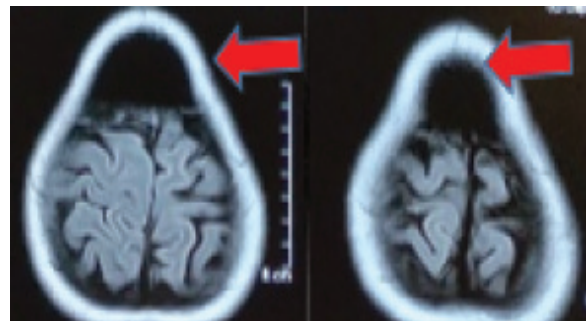
**Figure 3** Magnetic resonance imaging T1W pre-contrast sagittal images showing expansile hypointense lesion in diploic space of fronto-parietal bone



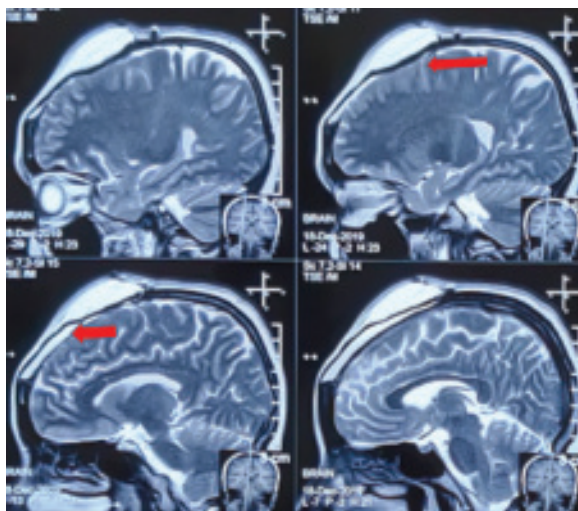
**Figure 4** Magnetic resonance imaging T1W post-contrast sagittal images showing enhancement of inner part of the lesion and adjacent meninges



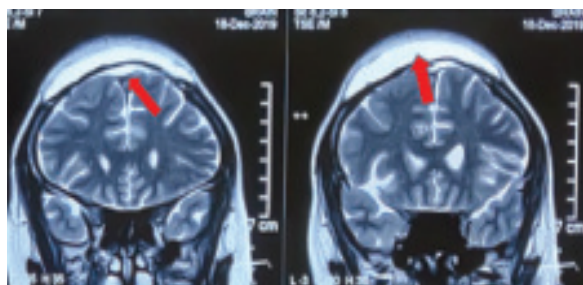
**Figure 5** Magnetic resonance imaging T2W axial images showing expansile hypointense lesion in diploic space of fronto-parietal bone



**Figure 6** Magnetic resonance imaging FLAIR axial images showing expansile hypointense lesion in diploic space of fronto-parietal bone



**Figure 7** Follow up magnetic resonance imaging T2W sagittal images showing inflammatory collection at operation site and around G-patch



**Figure 8** Follow up magnetic resonance imaging T2W coronal images showing inflammatory collection at operation site and around G-patch

## DISCUSSION

The meningiomas arising in locations outside the dural compartment are called ectopic, extradural, calvarial, cutaneous, extracranial, extraneuraxial or intra-osseous meningiomas.<sup>2</sup> Extradural meningiomas constitute 1 to 2% of all meningiomas.<sup>3</sup>

Primary intraosseous meningiomas are a subtype of primary extradural meningiomas, that arise in bone.<sup>4</sup> The vast majority of primary intraosseous meningiomas involve the calvaria.<sup>5</sup> Clinically, as in the present case, the majority of the primary intraosseous meningiomas present as painless expansile masses with normal neurological findings.<sup>6</sup> The majority of primary intraosseous meningiomas are osteoblastic subtype.<sup>6</sup>

On CT scan, most primary intraosseous meningiomas present as expansile, osteoblastic bone lesions, with or without cortical destruction.<sup>2</sup> MRI provides a better anatomic delineation in the evaluation of soft tissue component and extradural extension of the lesion. But, MRI is less sensitive than CT for detection of bone lesions. On MRI, the tumours are hypointense on T1-weighted images and T2-weighted sequences, typically without significant contrast enhancement, as in the case reported.<sup>1</sup> Enhancement of the underlying dura may be noted like our case. This dural enhancement could be secondary to dural irritation or tumour invasion.<sup>7</sup> Complete resection with reconstruction is the potential curative treatment. Radiation therapy is advocated for rapidly progressive disease.<sup>3</sup> Recurrence rates for all locations are estimated to be between 10% to 23%.<sup>2</sup>

A rare case of intra-osseous meningioma of the sphenoid bone of a 42-year-old female patient was reported in 2012.<sup>8</sup> Although rare, primary intraosseous meningiomas should be considered in the differential diagnosis of bone lesions, specially in women<sup>5</sup> when the lesions are osteoblastic and located in the cranial vault. CT and MRI are useful in preoperative radiological assessment of primary intraosseous meningiomas which can be treated successfully by surgical resection.

**Authors' contribution:** MAT diagnosed the case & planned the publication. IMB drafted the manuscript. IMB & MS did literature search. JS revised the manuscript. TH kept record and edited the manuscript. All authors read and approved final manuscript for submission.

**Conflicts of interest:** Nothing to declare.

**Consent:** Informed written consent was taken from the patient regarding publication of this case report and any accompanying images.

**Funding:** None.

## REFERENCES

1. Lang FF, Macdonald OK, Fuller GN, DeMonte F. Primary extradural meningiomas: A report on nine cases and review of the CT-era literature. *J Neurosurg* 2000 Dec 1; 93(6): 940-50.
2. Tokgoz N, Oner YA, Kaymaz M, Ucar M, Yilmaz G, Tali TE. Primary intraosseous meningioma: CT and MRI appearance. *Am J Neuroradiol* 2005 Sep 1; 26(8): 2053-6.

3. Muzumdar DP, Vengsarkar US, Bhatjiwale MG, Goel A. Diffuse calvarial meningioma: a case report. *J Postgrad Med* 2001 Apr 1; 47(2): 116.
4. Politi M, Romeike BF, Papanagiotou P, Nabhan A, Struffert T, Feiden W, et al. Intraosseous hemangioma of the skull with dural tail sign: radiologic features with pathologic correlation. *Am J Neuroradiol* 2005 Sep 1; 26(8): 2049-52.
5. Daffner RH, Yakulis R, Maroon JC. Intraosseous meningioma. *Skeletal Radiol* 1998 Feb 1; 27(2): 108-11.
6. Agrawal V, Ludwig N, Agrawal A, Bulsara KR. Intraosseous intracranial meningioma. *Am J Neuroradiol* 2007 Feb 1; 28(2): 314-5.
7. Arana E, Diaz C, Latorre FF, Menor F, Revert A, Beltran A, et al. Primary intraosseous meningiomas. *Acta Radiologica* 1996 May; 37(3P2): 937-42.
8. Ferdousi MA, Sharif MM, Bahar H, Mohiuddin AS, Hossain AM, Banu SG. A Rare Case of Intra-Osseous Meningioma of the Sphenoid Bone-A Case Report. *Ibrahim Med Coll J* 2012; 6(2): 73-5.