

Recurrent episodes of jaundice in a young man with Dubin-Johnson syndrome

Wadud MA^a, Azim MAU^b, Siddique AA^c, Kabir MA^d

ABSTRACT

Dubin-Johnson syndrome is a rare inherited disorder associated with a defect in the ability of hepatocytes to secrete conjugated bilirubin into bile. Patients usually present with chronic or recurrent attacks of jaundice with conjugated hyperbilirubinemia. A dark pigment accumulates in the liver, which is responsible for its characteristic black color. It is a benign condition with a normal life expectancy and no specific treatment is required. We report a case of Dubin-Johnson syndrome in a 20-year-old man with recurrent episodes of jaundice, whose laboratory data revealed a mild conjugated hyperbilirubinemia, remaining liver function tests were normal and diagnosis was confirmed by the presence of dark brown pigment on microscopy of liver biopsy.

Keywords: Dubin-Johnson syndrome, conjugated hyperbilirubinemia, liver biopsy, dark brown pigment.

(BIRDEM Med J 2021; 11(3): 235-238)

INTRODUCTION

Dubin-Johnson syndrome is a rare autosomal recessive disorder that causes conjugated hyperbilirubinemia. It was first reported by Dubin and Johnson in 1954.¹ Primary defect is a mutation in an apical canalicular membrane protein MRP2 located on chromosomes 10q 24, which is responsible for excretion of bilirubin from hepatocyte into bile across the canalicular membrane.²⁻³ The cytoplasm of hepatocytes contains dark brown pigment granules, appearing grey to black in color grossly. The liver is otherwise normal.⁴ Apart from chronic or recurrent jaundice of fluctuating intensity,

most patients are asymptomatic.⁵ Occasionally, patients complain of weakness, fatigue and vague abdominal pain and hepatomegaly is rarely observed. Liver function tests including enzymes are usually within normal limits although the bilirubin levels usually fluctuate. The diagnosis is based on the presence of intracellular dark brown pigmented granules in the liver on histology. The disease is completely benign and requires no treatment.^{1,6} There are few cases reported from Bangladesh. This case report describes Dubin-Johnson syndrome in a 20-year-old male with recurrent episodes of jaundice for three years.

Author information

- Md. Abdul Wadud, Resident Physician, Shaheed Sheikh Abu Naser Specialized Hospital, Khulna, Bangladesh.
- Muhammed Arshad Ul Azim, Assistant Professor, Department of Nephrology, Shaheed Sheikh Abu Naser Specialized Hospital, Khulna, Bangladesh.
- Ashfaque Ahmed Siddique, Assistant Professor, Sheikh Russel National Gastro Liver Institute and Hospital, Dhaka, Bangladesh.
- Md. Anwarul Kabir, Professor, Department of Gastroenterology, Bangabandhu Sheikh Mujib Medical University, Dhaka, Bangladesh.

Address of correspondence: Md. Abdul Wadud, Resident Physician, Shaheed Sheikh Abu Naser Specialized Hospital, Khulna, Bangladesh. Email: drwadud40@gmail.com

Received: February 9, 2021

Revision received: April 21, 2021

Accepted: June 30, 2021

CASE REPORT

A 20-year-old male student from Khulna presented on March 2016 with a history of recurrent bouts of jaundice for three years. Physical examination findings were unremarkable other than mild jaundice. Significant data from the laboratory investigations were: total serum bilirubin 4.8 mg/dl (direct 3.4 mg/dl). Serum alanine aminotransferase, aspartate aminotransferase, alkaline phosphatase, albumin and prothrombin time were normal. Any abnormalities of liver and biliary tract were not observed by ultrasonography. The patient at that time had a copy of blood tests performed earlier. That also showed increased total serum bilirubin (mostly conjugated), while all other liver function tests were normal. Diagnosis of conjugated hyperbilirubinemia was

made and with a suspicion of Dubin-Johnson syndrome or Rotor's syndrome.

Liver biopsy was performed with a Tru-Cut needle to confirm the diagnosis. On macroscopic examination, marked black discoloration of the hepatic parenchyma was seen (Figures 1, 2). Microscopic preparation showed normal liver architecture and dark-brown pigmented granules within the cytoplasm of hepatocytes with routine haematoxylin and eosin (H&E) staining (Figure 3). The pigmented granules were positive with Masson-Fontana staining (Figure 4) but negative with peroxidic acid-Schiff (PAS), periodic acid-Schiff-diastase (PAS-D), *Masson's Trichrome*, iron and reticulin stain. No evidence of steatosis, granuloma, cirrhosis or atypical cells was seen. Based on the clinical history and histopathological findings of the liver biopsy, a diagnosis of Dubin-Johnson syndrome was made. Since no treatment is required in this condition, no specific treatment was given.



Figure 1 Tru-Cut needle containing black hepatic tissue



Figure 2 Test tube containing black hepatic tissue

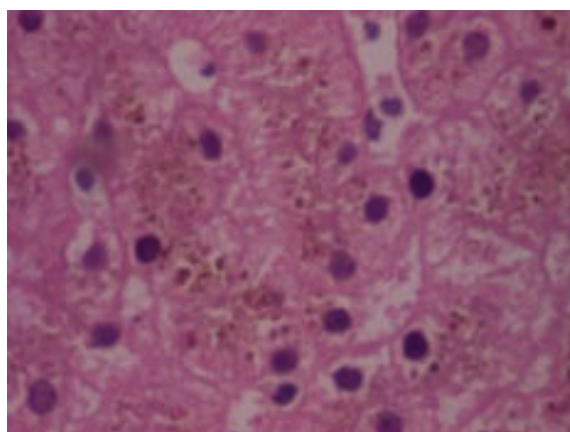


Figure 3 Accumulation of dark brown granular pigment within the cytoplasm of hepatocytes (H&E staining)

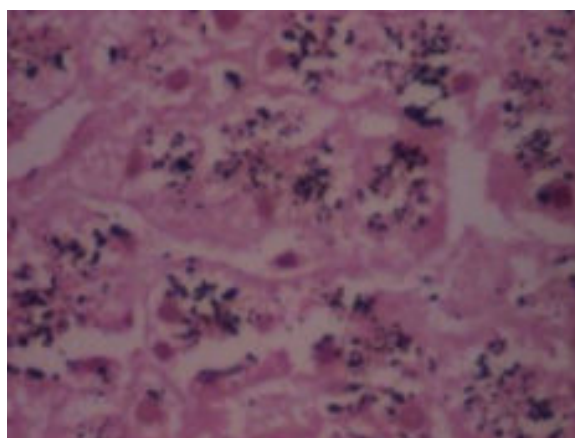


Figure 4 Pigment showed positivity with Masson Fontana stain

DISCUSSION

Several disorders may lead to recurrent jaundice including Gilbert syndrome, Dubin-Johnson syndrome, Wilson disease, cholestasis and hemolysis. The molecular basis of Dubin-Johnson syndrome is the complete absence of a functionally active multi-drug resistance protein called MRP2, also known as human canalicular multi-specific organic anion transporter gene (cMOAT). The gene is localized on chromosome 10q24 and is responsible for the transport of bilirubin glucuronides and related organic anions across the canalicular membrane of the hepatocyte and exports them from hepatocyte into bile. Mutation of MRP2 leads to defective transport of bilirubin glucuronide from the hepatocyte into the bile canaliculi.^{2,3} Deficient excretion of bilirubin glucuronides at the canalicular membrane in the presence of otherwise normal intrahepatic

metabolism results in reflux of conjugated bilirubin back into the circulation and develops conjugated hyperbilirubinaemia.⁸

Dubin-Johnson syndrome is usually present between the ages of 10 and 30 years,⁹ although cases have been reported in neonates.¹⁰ The prevalence of this disease is extremely low but accurate figures are unknown. It has been described worldwide in all races and ethnic backgrounds and in both sexes, although males predominate and present at an earlier age. The highest recognized prevalence is in Iranian and Moroccan Jews.¹¹

Patients typically present with intermittent jaundice in response to triggering factors such as intercurrent illness, infection, stress, pregnancy or drugs that decrease hepatic excretion of organic anions, notably oral contraceptives.^{9,12} A few patients may report weakness and fatigue, especially during an episode of increased jaundice and vague abdominal discomfort. Rarely hepatomegaly is seen. Liver function tests including enzymes are usually within normal limits although raised bilirubin levels are observed.^{1,6}

In patients with repeated bouts of mild jaundice since childhood, if liver function tests only show raised serum bilirubin levels without abnormalities in liver enzymes, the next line of investigation is to determine, whether hyperbilirubinemia is unconjugated or conjugated. In case of unconjugated hyperbilirubinemia, peripheral blood count and reticulocyte count are performed. If these are positive, the patient is investigated for hemolytic disorders; if negative, possibility of Gilbert's syndrome is raised. In case of conjugated hyperbilirubinemia, the possibility of Dubin- Johnson syndrome and Rotor's syndrome is raised.¹³

The diagnosis of Dubin- Johnson syndrome is based on the presence of dark-brownish pigment granules in the hepatocyte cytoplasm^{1,6} and increased levels of coproporphyrin I isomer (more than 80%) in the urine while total urine porphyrin output is normal.¹⁴ Urinary coproporphyrin is a surrogate marker rather than a definitive test. A percutaneous liver biopsy is recommended in all patients to confirm the diagnosis of Dubin- Johnson syndrome and exclude any concomitant liver pathology.¹⁵

Serum total bilirubin level is usually around 2-6 mg/dl and more than half of it consist of conjugated bilirubin

in patients with Dubin- Johnson syndrome.¹⁶ In our patient, serum total bilirubin level was 4.8 mg/dl and mostly conjugated (3.4 mg/dl).

Macroscopically black liver and histopathologically dark-brown pigmented granules within the cytoplasm of hepatocytes are the hallmark for definitive diagnosis of Dubin- Johnson syndrome.^{1,6} It is hypothesised that these pigments accumulate in the liver because of impaired secretion of various metabolites from the hepatocyte into the bile.⁹ These coarse, dark-brown pigmented granules share some physiochemical properties with lipofuscin and melanin and stains black with the *Masson-Fontana* stain.¹⁷ In our patient, macroscopic appearance of liver tissue was black and microscopic preparation showed dark-brown pigmented granules within the cytoplasm of hepatocytes with haematoxylin and eosin stain. *Pigments were confirmed with Masson-Fontana stain. All were consistent with Dubin- Johnson syndrome.*

Conclusion

We reported a case of recurrent jaundice in a young man with Dubin-Johnson Syndrome. It is a rare benign disease requiring only reassurance. No specific treatment is required. Monitoring is not required once the diagnosis is established. The prognosis is excellent, it is associated with a normal life expectancy, and despite a lack of treatment there is no evidence of progressive hepatic damage. Therefore, establishing the correct diagnosis is important to prevent future unnecessary investigations.

Authors' contribution: MAW, MAK planned the study, collection and interpretation of data, MAW, MAUA drafted manuscript, AAS, MAUA critically revised the manuscript, MAK was the overall supervisor. All authors read and approved the final version for submission.

Acknowledgement: We express our heartfelt thanks to Dr. Gaurav Sharma, Senior Consultant Pathologist, Dr. Lal Pathlabs, New Delhi, India, for his kind review of histopathological slides and cooperation in diagnosing this case.

Conflict of interest: Nothing to declare.

REFERENCES

1. Dubin IN, Johnson FB. Chronic idiopathic jaundice with unidentified pigment in the liver cells: a new clinicopathologic entity with report of 12 cases. *Medicine (Baltimore)* 1954;33:155-97.

2. Paulusma CC, Kool M, BosmaPJ, Scheffer G L, BorgFter, SchepR J et al. A mutation in the human canalicular multispecific organic anion transporter gene causes the Dubin-Johnson syndrome. *Hepatology* 1997;25:1539-42.
3. Toh S, Wada M, Uchiumi T, Inokuchi A, Makino Y, Horie Y et al. Genomic structure of the canalicular multispecific organic anion-transporter gene (MRP2/CMOAT) and mutations in the ATP-binding-cassette region in Dubin-Johnson syndrome. *Am J Hum Genet* 1999;64:739-46.
4. Knisely AS, Crawford JM. Inherited and developmental disorders of the liver. In: Odze RD, Goldblum JR, Crawford JM, (edi). *Surgical pathology of the GI tract, liver, biliary tract and pancreas*. Philadelphia: Saunders; 2004:p.979-98.
5. Crawford JM. The liver and biliary tract. In: Kumar V, Abbas AK, Fausto N, (edi). *Robbins and Cotran pathologic basis of disease*. 7th ed. Philadelphia: Saunders; 2004:p.887-8.
6. Chowdhury JR, Wolkoff AW, Chowdhury NR, Arias IM. Hereditary jaundice and disorders of bilirubin metabolism. In: Scriver CR, Beaudet AL, Sly WS, Valle D (eds) *The Metabolic and Molecular Bases of Inherited Disease*. 7th ed Vol: II. New York. McGraw-Hill, Inc, 1995: 2161-2208.
7. Sprinz H, Nelson RS. Persistent non hemolytic hyperbilirubinemia associated with lipochrome-like pigment in liver cells: report of 4 cases. *Ann Intern Med* 1954;41:952-62.
8. Kartenbeck J, Leuschner U, Mayer R, Keppler D. Absence of the canalicular isoform of the MRP gene-encoded conjugate export pump from the hepatocytes in Dubin-Johnson syndrome. *Hepatology* 1996;23:1061-6.
9. Rastogi A, Krishnani N, Pandey R. Dubin-Johnson syndrome: a clinicopathologic study of twenty cases. *Indian J Pathol Microbiol* 2006;49:500-4.
10. Kondo T, Yagi R. Dubin-Johnson syndrome in a neonate. *N Engl J Med* 1975;292:1028-9.
11. Mor-Cohen R, Zivelin A, Fromovich-Amit Y, Kovalski V, Rosenberg N, Seligsohn U. Age estimates of ancestral mutations causing factor VII deficiency and Dubin-Johnson syndrome in Iranian and Moroccan Jews are consistent with ancient Jewish migrations. *Blood Coagul Fibrinolysis* 2007;18:139-44.
12. Shani M, Seligsohn V, Gilon E, Sheba C, Adam A. Dubin-Johnson syndrome in Israel: clinical, laboratory and genetic aspects of 101 cases. *Q J Med* 1970;39:549-67.
13. Chapman RW, Collier ID, Hayes PC. Liver and biliary tract disease. In: Boon NA, Colledge NR, Walker BR, Hunter JAA, (edi). *Davidson's principles and practice of medicine*. 20th ed. Edinburg: Churchill Livingstone; 2006:p.945.
14. Frank M, Doss M, de Carvalho DG. Diagnostic and pathogenetic implications of urinary coproporphyrin excretion in Dubin-Johnson syndrome. *Hepatogastroenterology* 1990;37:147-51.
15. Dubin IN. Chronic idiopathic jaundice: a review of 50 cases. *Am J Med* 1958;24:268-92.
16. The familial conjugated hyperbilirubinemias. *Semin Liver Dis* 1994;14:386-94.
17. Ishak KG, Sharp HL, Schwarzenberg SJ. Metabolic errors and liver disease. In: MacSween RNM, Burt AD, Portmann BC, Ishak KG, Scheuer PJ, Anthony PP, (edi). *Pathology of the liver*. 4th ed. New York: Churchill Livingstone; 2002:p.221.