

Malignant hypercalcemia associated with ovarian dysgerminoma: a case report

Ullah MAIK^a, Khanam F^b, Ghosh P^c, Rouf RSB^d, Amin MF^e

ABSTRACT

Hypercalcemia is a well-recognized and potentially dangerous paraneoplastic manifestation of malignancy; furthermore, it is an important cancer related medical emergency. It has been endured in association with a number of malignancies; however, it is an unusual presentation of ovarian cancer like dysgerminoma. This neoplasm along with refractory hypercalcemia, which usually affects the young women, is a sign of advanced disease and indicates poor prognosis. In this report, we present a case of 31-year-old female, who presented with features of hypercalcemia which was associate with ovarian dysgerminoma.

Key words: Dysgerminoma, hypercalcemia, ovarian cancer.

(*BIRDEM Med J* 2022; 12(2): 158-160)

INTRODUCTION

Hypercalcemia is one of the commonly encountered paraneoplastic phenomenon, occurring in 20-30% of adult patients with cancer.¹ Hypercalcemia has been associated with a wide range of malignancies including squamous cell carcinoma of lung, renal cell carcinoma, multiple myeloma and carcinoma of the breast.² Hypercalcemia associated with ovarian malignancies is rare with a reported prevalence of 0.5% to 8.2%.³ This paraneoplastic syndrome is usually related to synthesis of parathyroid hormone-related peptide. Hypercalcemia associated with dysgerminoma is typically corrected

within one week of resection of tumor.⁴ Here, we present a case of hypercalcemia associated with dysgerminoma. This case is remarkable due to development of hypercalcemia following complete surgical resection of the tumor.

CASE REPORT

The patient is a 31-year-old house wife, who is known case of diabetes mellitus, who was diagnosed with ovarian dysgerminoma in 2019 and underwent total abdominal hysterectomy with bilateral salpingo-oophorectomy in the same year. Biopsy of the mass revealed an ovarian dysgerminoma (Figure 1). Patient received chemotherapy with good response following surgical tumor debulking. There was no family history of endocrine neoplasia or parathyroid disease.

Author Information

- Md. Amirul Islam Kudrat Ullah, Resident Medical Officer, Department of Endocrinology, BIRDEM General Hospital, Dhaka, Bangladesh.
- Fatisha Khanam, Lecturer, Department of Pharmacology, Ibrahim Medical College, Dhaka, Bangladesh.
- Parijat Ghosh, Resident, MD Phase B (Endocrinology), Department of Endocrinology, BIRDEM General Hospital, Dhaka, Bangladesh.
- Rushda Sharmin Binte Rouf, Assistant Professor, Department of Endocrinology, BIRDEM General Hospital, Dhaka, Bangladesh.
- Mohammad Feroz Amin, Professor, Department of Endocrinology, BIRDEM General Hospital, Dhaka, Bangladesh.

Address of correspondence: Md. Amirul Islam Kudrat Ullah, Resident Medical Officer, Department of Endocrinology, BIRDEM General Hospital, Dhaka, Bangladesh. Email: amirul.pavel@gmail.com

Received: November 4, 2021

Revision received: January 31, 2022

Accepted: February 28, 2022

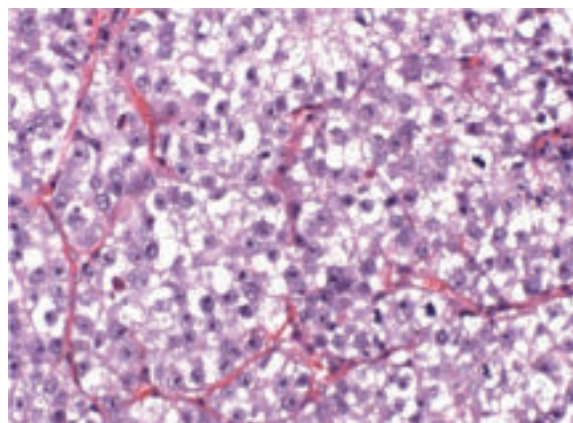


Figure 1 Dysgerminoma with well-defined borders

After two years of diagnosis of ovarian dysgerminoma, she presented with anorexia, intermittent vomiting, abdominal pain, constipation and polyuria for 3 weeks. She also suffered from back pain for same duration.

On examination, she was anemic, dehydrated and had tenderness in lumbar spine. The abnormal blood indices on admission were hemoglobin 8.5 g/dl, serum calcium level markedly raised at 14.5 mg/dl, serum creatinine 3.1 mg/dl, blood urea 88 mg/dl, vitamin D level 32 ng/ml and suppressed intact parathyroid hormone value at 9.10 pg/ml. Her X-ray revealed foci of metastasis in lumbar spine (Figure 2). To correct hypercalcemia, she was treated vigorously with intravenous fluid along with diuretics, steroid, calcitonin and zoledronic acid. After 10 days of extensive medical management, her serum calcium transiently decreased to 9.4 mg/dl. Serum urea and creatinine levels returned to normal after rehydration.

DISCUSSION

Hypercalcemia is an acclaimed paraneoplastic syndrome commonly occurs in adult patients with malignancy. Nevertheless, dysgerminoma associated with hypercalcemia is rare and it is important to make the diagnosis, as hypercalcemia can be life threatening.⁵ There are several theories regarding the etiology of hypercalcemia associated with malignancy, such as bone metastasis, secretion of parathyroid related protein from the tumor and other humoral factors.⁶ Generally, it is thought to be resulted from the secretion of a peptide called parathyroid related protein from the tumor.⁷ Other humoral factors are also responsible for the pathogenesis of cancer associated hypercalcemia such as TNF- α , TNF- β , GCSF, interleukins, lymphotoxin, TGF- β and TGF- α .⁸ Under these circumstances hypercalcemia is extremely resistant to medical management and most effective treatment is surgical resection of the tumor.⁹ In most described cases of hypercalcemia associated with dysgerminoma, calcium level corrected within few days of tumor debulking.¹⁰ This case is unique as hypercalcemia was diagnosed 2 years after resection of tumor. Other causes were excluded by proper history, physical examination and laboratory investigation. Moreover, in case of our patient, parathyroid level was

low normal and vitamin D level was normal. In the absence of other obvious cause, it suggests that hypercalcemia is, may be due to paraneoplastic phenomenon or metastasis to bone. Physicians should be aware of association between dysgerminoma and hypercalcemia. Incomplete resolution of hypercalcemia following the resection of tumor, suggested an undescribed mechanism.

Conclusion

Hypercalcemia is a life-threatening complication in malignancy which is often refractory to medical management. Parathyroid related peptide and bone metastasis may be risk factor for hypercalcemia even after resection of primary tumor. However, the degree of hypercalcemia may predict advanced stage of malignancy and poor survival.

Authors' Contribution: MAIKU managed the case, did literature search and drafted the manuscript. FK did the literature search and helped in drafting manuscript, PG managed the case, RRSB supervised managing the case, MFA was the overall supervisor.

Consent: Informed written consent was taken from the patient for publication of this case report with accompanying images.

Conflicts of interest: Nothing to declare.

REFERENCES

1. Stewart AF. Hypercalcemia associated with cancer. *New England Journal of Medicine* 2005 Jan 27;352(4):373-9.
2. Muggia FM, Heinemann HO. Hypercalcemia associated with neoplastic disease. *Annals of Internal Medicine* 1970 Aug 1;73(2):281-90.
3. Giebel SC, Stanhope CR, Malkasian Jr GD, Schray MF, Heath H, Gaffey TA. Humoral hypercalcemia associated with a dysgerminoma. In *Mayo Clinic Proceedings* 1992 Oct 1;67(10):966-968.
4. Rankin W, Grill V, Martin TJ. Parathyroid hormone related protein and hypercalcemia. *Cancer: Interdisciplinary International Journal of the American Cancer Society*. 1997 Oct 15;80(S8):1564-71.
5. Okoye BO, Harmston C, Buick RG. Dysgerminoma associated with hypercalcemia: a case report. *Journal of Pediatric Surgery* 2001 Jul 1;36(7):1-3.
6. Lakhdir F, Lawson D, Schatz DA. Fatal parathyroid hormone-related protein-induced humoral hypercalcemia

- of malignancy in a 3-month-old infant. *European journal of Pediatrics* 1994 Oct;153(10):718-20.
7. Knecht TP, Behling CA, Burton DW, Glass CK, Deftos LJ. The humoral hypercalcemia of benignancy: a newly appreciated syndrome. *American Journal of Clinical Pathology* 1996 Apr 1;105(4):487-92.
 8. Goni MH, Tolis G. Hypercalcemia of cancer: an update. *Anticancer Research* 1993 Jul 1;13(4):1155-60.
 9. Burtis WJ, Brady TG, Orloff JJ, Ersbak JB, Warrell Jr RP, Olson BR, Wu TL, Mitnick ME, BroadusAE, Stewart AF. Immunochemical characterization of circulating parathyroid hormone-related protein in patients with humoral hypercalcemia of cancer. *New England Journal of Medicine* 1990 Apr 19;322(16):1106-12.
 10. Matthew R, Christopher O, Philippa S. Severe malignancy associated hypercalcemia in dysgerminoma. *Pediatric Blood & Cancer* 2006 Oct 15;47(5):621-3.