

# A male child with Van Wyk-Grumbach syndrome and hypertrophic cardiomyopathy: a rare case with a rare association

Zabeen F<sup>a</sup>, Nazrin T<sup>b</sup>, Begum N<sup>c</sup>

### ABSTRACT

Children with severe long-standing hypothyroidism rarely present with Van Wyk–Grumbach syndrome with delayed bone age and pseudoprecocious puberty. Till date, very few such cases are reported in boys. Boys are characterized by testicular enlargement with minimal penile enlargement. The prepubertal response in this syndrome is always isosexual and is mediated by very high thyroid-stimulating hormone levels acting through the follicle-stimulating hormone receptors. Although, hypothyroidism-induced dilated cardiomyopathy is an uncommon phenomenon, here we present a case of Van Wyk–Grumbach syndrome in a prepubertal boy with hypertrophic cardiomyopathy.

**Key words:** hypothyroidism, Van Wyk–Grumbach syndrome, pseudoprecocious puberty, cardiomyopathy.

*BIRDEM Med J 2022; 12(3): 226-229*

### INTRODUCTION

Hypothyroidism is among the most common endocrine disorders in children.<sup>1</sup> Although sexual development is delayed in the majority of hypothyroid children, hypothyroidism if prolonged and untreated, pediatric patients may rarely exhibit signs of early puberty, the Van Wyk-Grumbach syndrome.<sup>2</sup> They have decreased free thyroxine (T<sub>4</sub>), together with elevated thyroid stimulating hormone (TSH) level as well as prepubertal response mediated through follicle-stimulating hormone (FSH) receptor. Phenotypically, such syndrome with female patients show breast enlargement, early onset of

menstrual bleeding and enlarged multicystic ovaries while in male, the only sign is testicular enlargement without substantial Leydig cell stimulation or testosterone secretion.<sup>3</sup> The commonest cardiac abnormality recognized in patients with longstanding hypothyroidism is impairment of left ventricular (LV) diastolic function.<sup>4</sup> However, hypothyroidism presenting as dilated cardiomyopathy and decreased LV systolic function is a rare feature; hypertrophic cardiomyopathy in such case is very rare association. Van Wyk-Grumbach syndrome has been reported predominantly in girls,<sup>5</sup> while very few cases are reported in boys.<sup>6</sup> We present a Bangladeshi young boy with Van Wyk-Grumbach syndrome and hypertrophic cardiomyopathy.

---

### Author information

- Fahmida Zabeen, Senior Consultant, Department of Paediatrics and Neonatology, Evercare Hospital, Dhaka, Bangladesh.
- Tahera Nazrin, Clinical and Interventional Paediatric Cardiologist, Department of Paediatric Cardiology, Evercare Hospital, Dhaka, Bangladesh.
- Noorjahan Begum, Specialist, Department of Paediatric ICU, Evercare Hospital, Dhaka, Bangladesh.

**Address of correspondence:** Fahmida Zabeen, Senior Consultant, Department of Pediatrics and Neonatology, Evercare Hospital, Dhaka, Bangladesh. Email: fahmida.zabeen@hotmail.com

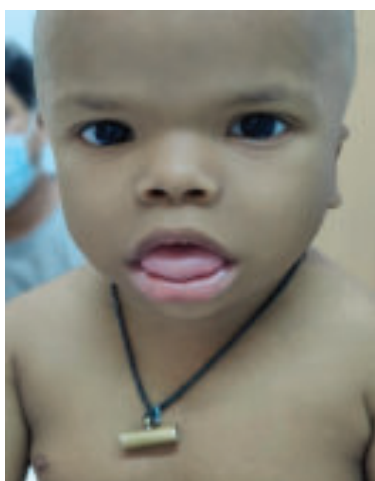
**Received:** July 3, 2022

**Revision received:** July 16, 2022

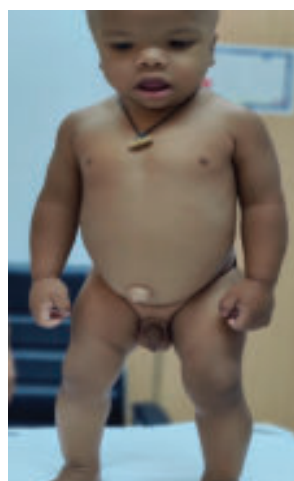**Accepted:** August 23, 2022

### CASE REPORT

A 5-year-2-month-old boy of non-consanguineous parents presented with growth failure and poor intelligence since early infancy. He had persisting constipation, lethargy and snoring during sleep. There was no history of cranial irradiation, trauma and surgery. He had no family history suggestive of thyroid disease. On examination, he was vitally stable, pale looking and had characteristic features of hypothyroidism including course facies, macroglossia, dry and rough skin and protruding abdomen with no organomegaly and had umbilical hernia (Figures 1a, 1b). Thyroid gland was not palpable.



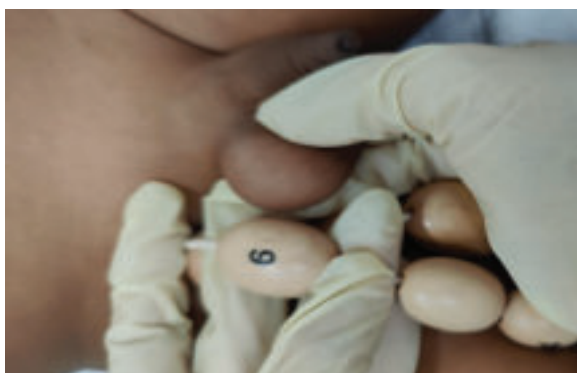**Figure 1 (a)** Coarse facies with macroglossia



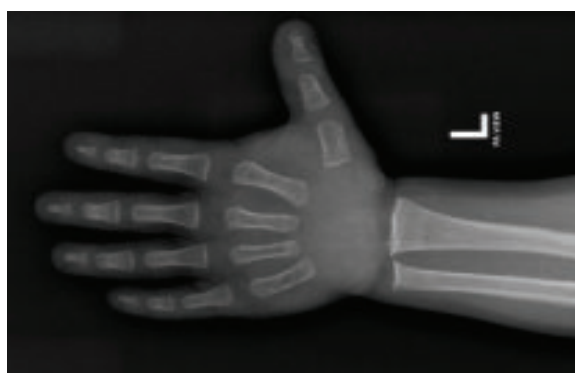
**Figure 1 (b)** Clinical photograph of the patient with features of hypothyroidism

Pubertal status was P<sub>1</sub>PH<sub>1</sub> with bilateral 6 ml testicular volume (Figure 2) by Prader orchidometer and stretched penile length was 4 cm. His growth was severely retarded weighing 11.4 kg (<1 percentile, -4.43 Z) and height was 74.5 cm (<1 percentile, -7.81 Z), US: LS 1.33:1 (expected 1.19:1). His bone age (Figure 3) was below 3 months

according to Greulich and Pyle atlas method. Hormonal investigations (Table I) revealed extremely low free T4: 0.1 ng/dL and markedly elevated TSH (>150 µIU/mL), FSH, luteinizing hormone (LH) and serum testosterone levels were prepubertal. He also had low haemoglobin and raised alanine aminotransferase (ALT).



**Figure 2** Testicular volume 6 ml size

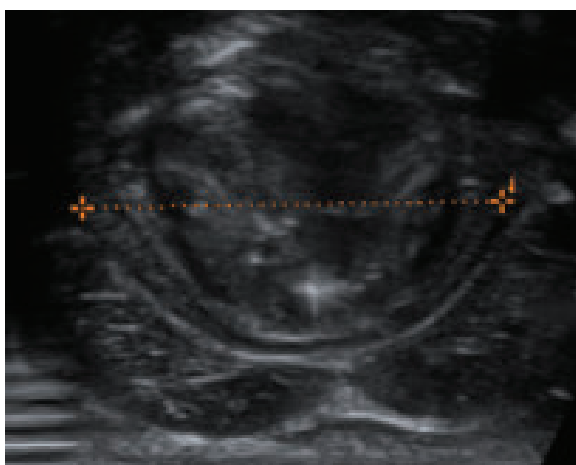


**Figure 3** Bone age <3 months with no carpal bone

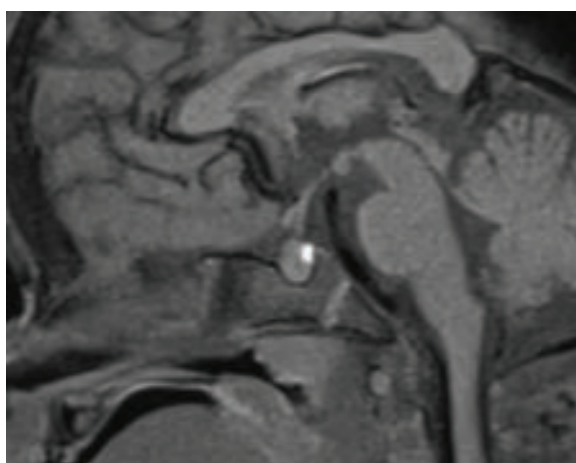
**Table I** Laboratory results of the patient with Van Wyk-Grumbach syndrome

Parameter	Value		Reference range
	Before treatment	After 2 months of levothyroxine treatment	
Haemoglobin (gm/dl)	8.6		11-14
Thyroid-stimulating hormone (µIU/ml)	>150	11.2	0.4-5.3
Free T4 (ng/dl)	0.1	0.9	0.8-1.9
Luteinizing hormone (mIU/ml)	0.2	-	<0.3
Follicle-stimulating hormone (mIU/L)	2	-	<4
Testosterone (total) (ng/ml)	<0.1	-	2-12
Alanine aminotransferase (U/L)	69	28	<45
Random blood glucose (mmol/L)	5.3	-	4.2-7.8

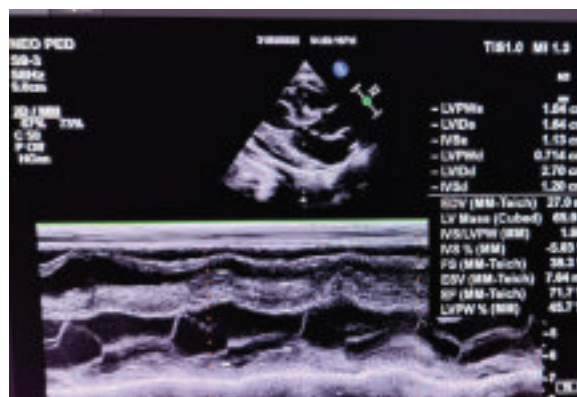
Imaging studies revealed very small thyroid gland in ultrasonography of neck (Figure 4) and pituitary hyperplasia in magnetic resonance imaging (MRI) of brain (Figure 5). 2D Color Doppler Echocardiogram (Figure 6) showed asymmetric hypertrophy of interventricular septum (12 mm, Z score +6.22), hypertrophied left ventricular posterior wall (7 mm, Z score +2.4) with left ventricular mid cavity obstruction (max Pg 35 mm Hg). The clinical and laboratory findings were consistent with the diagnosis of Van Wyk-Grumbach syndrome. He was started on levothyroxine and consultation of cardiologist was taken for cardiomyopathy.



**Figure 4** Very small thyroid gland with right lobe (0.014 cc) and left lobe (0.023 cc)



**Figure 5** MRI of brain showing enlargement of the pituitary gland (0.9 cm X 0.6 cm) and pituitary hyperplasia



**Figure 6** 2D Color Doppler Echocardiogram showing hypertrophy of interventricular septum and left ventricular posterior wall.

## DISCUSSION

Van Wyk-Grumbach syndrome is very rare in boys.<sup>5</sup> The paradoxical precocious puberty with pubertal size testicular volume in this case can be explained by the presence of high level of TSH acting weakly on the FSH receptor causing overproduction of Sertoli cells and testicular enlargement.<sup>7</sup> Though growth acceleration is the norm, here in this syndrome with precocity, short stature and delayed bone age is due to lack of thyroid hormone mediated direct and indirect action on bone maturation.<sup>8</sup> This boy presented with severe growth retardation with height more adversely affected than weight and markedly delayed bone age. Few case reports till date in literature stating hypothyroidism-induced dilated cardiomyopathy with decreased LV systolic function.<sup>4</sup> Nevertheless, our child had hypertrophic cardiomyopathy with normal LV. Moreover, he did not have coarctation of aorta, hypertension or features of storage disease as the cause of hypertrophic cardiomyopathy. We could not do the family screening to rule out its inherited origin. In the present case, pituitary enlargement was revealed by cranial MRI. Pituitary enlargement secondary to long-standing hypothyroidism leading to thyrotroph hyperplasia is a known but uncommon occurrence.<sup>9</sup>

Our reported case had moderate anaemia. In patients with hypothyroidism, it was speculated that, the anemia may be associated with the reduced red cells and decreased metabolic oxygen requirement in tissues.<sup>10</sup>

The raised ALT of our reported case during presentation normalized within 2 months of oral levothyroxine

treatment. Chung et al<sup>11</sup> reported that nonalcoholic fatty liver disease (NAFLD) was more severe and hepatic enzyme was significantly elevated in patients with hypothyroidism compared to those in normal subjects. We could not do detail evaluation for NAFLD. The patient was put on levothyroxine replacement, which was titrated accordingly and was followed closely in Pediatrics and Pediatric Cardiology clinic.

### Conclusion

Early recognition of hypothyroidism is important to prevent this rare but serious complications like Van Wyk-Grumbach syndrome. Sexual precocity with delayed bone age and stunting are important clue for suspicion of this syndrome. Reversal to prepubertal state is typically seen following appropriate treatment. Rare association like hypertrophic cardiomyopathy needs appropriate evaluation and management.

**Authors' contribution:** FZ: Conceptualization, literature search and writing manuscript. TN: Review and editing. NB: Review and editing.

**Consent:** Informed written consent of parents was taken for publication of this case report and accompanying images.

**Conflicts of interest:** Nothing to declare

### REFERENCES

1. VanWyk JJ, Grumbach MM. Syndrome of precocious menstruation and galactorrhea in juvenile hypothyroidism: an example of hormonal overlap in pituitary feedback. *J Pediatr* 1960; 57 (3): 416-35.
2. Zdraveska N, Kocova M. Hashimoto thyroiditis in childhood—Review of the epidemiology, genetic susceptibility and clinical aspects of the disease. *Macedonian J Med Sci* 2012; 5(3): 336-45.
3. Indumathi CK, Bantwal G, Patil M. Primary hypothyroidism with precocious puberty and bilateral cystic ovaries. *Indian J Pediatr* 2007; 74 (8):781-3.
4. Bezdah L, Slimène H, Kammoun M, Haddad A, Belhani A. Hypothyroid dilated cardiomyopathy. *Ann Cardiol Angeiol (Paris)* 2004;53:217-20.
5. Baranowski E, Högler W. An unusual presentation of acquired hypothyroidism: The Van Wyk Grumbach syndrome. *Eur J Endocrinol* 2012; 166: 537-42.
6. Esen I, Demirel F. Hypothyroidism associated testicular enlargement: Is it a form of precocious puberty or not? A case report. *Turk J Pediatr* 2011; 53: 210-2.
7. Rastogi A, Bhadada SK, Bhansali A. An unusual presentation of a usual disorder: Van Wyk Grumbach syndrome. *Indian J Endocrinol Metab* 2011; 15 (Suppl 2): S141-S143.
8. Kroeze WK, Sheffler DJ, Roth BL. G protein coupled receptors at a glance. *J Cell Sci* 2003;116: 4867-9.
9. Eom KS, See-Sung C, Kim JD, Kim JM, Kim TY. Primary hypothyroidism mimicking a pituitary macroadenoma: regression after thyroid hormone replacement therapy. *Pediatric Radiology* 2009; 39(2):164-7.
10. Chu JY, Monteleone JA, Peden VH, Graviss ER, Vernava AM. Anemia in children and adolescents with hypothyroidism. *Clin Pediatr (Phila)* 1981; 20: 696-9.
11. Chung GE, Kim D, Kim W, Kim W, Yim JY, Park MJ, et al. Non alcoholic fatty liver disease across the spectrum of hypothyroidism. *J Hepatol* 2012; 57: 150-6.