

Medical quiz: images

Munshi A^a, Islam MR^b

BIRDEM Med J 2022; 12(3): 230

A 55-year-old non-diabetic, normotensive patient presented with sudden, severe, dull aching headache associated with right sided partial ptosis and horizontal diplopia. His headache was more pronounced on right side of head. It was not associated with dimness of vision, chemosis of eye, vomiting, speech difficulties, weakness or numbness of limbs, bowel or bladder dysfunction or fever. On examination, he was anxious

and ill looking. His blood pressure was 90/60 mm of Hg with tachycardia and small volume pulse. He had right sided 3rd and 6th nerve palsy with mild asymmetry of pupil size. Examination of other systems revealed no abnormalities. His serum sodium level was 116 mmol/l. Magnetic resonance imaging (MRI) of the brain (Figure 1 and 2) was done.

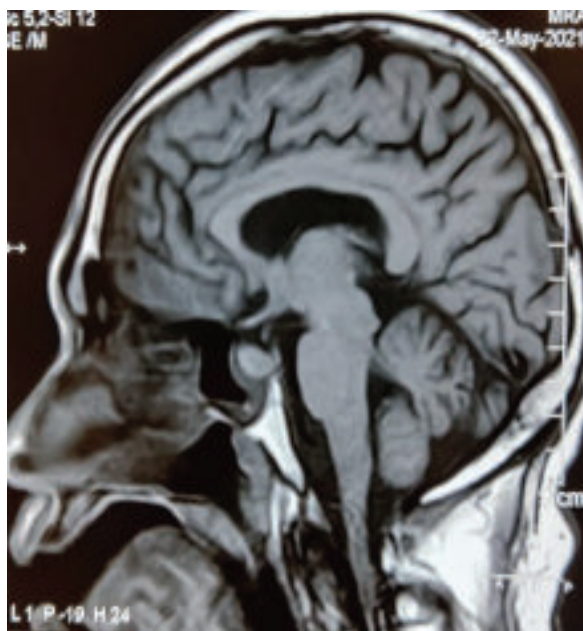

Figure 1

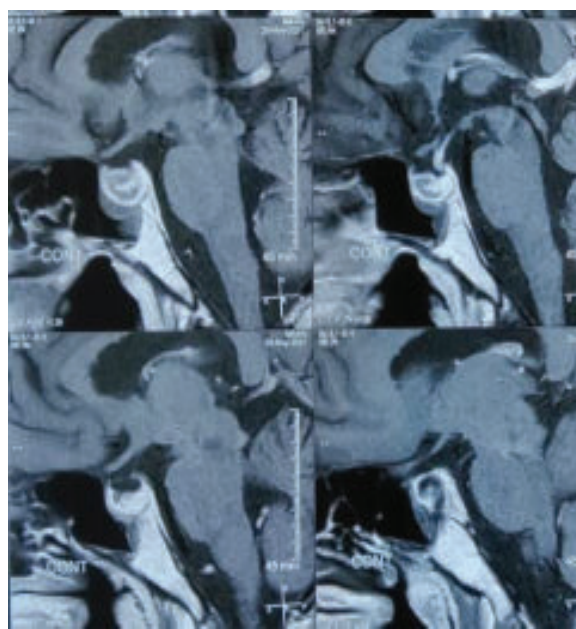


Figure 2

Author information

- Anik Munshi, Resident Medical Officer, Department of Neurology, BIRDEM General Hospital, Dhaka, Bangladesh.
- Md. Rashedul Islam, Assistant Professor, Department of Neurology, BIRDEM General Hospital, Dhaka, Bangladesh.

Address of correspondence: Md. Rashedul Islam, Assistant Professor, Department of Neurology, BIRDEM General Hospital, Dhaka, Bangladesh. Email: rashed2k2001@yahoo.com

Received: August 11, 2022

Revision received: August 16, 2022

Accepted: August 23, 2022

Questions

1. What are the abnormal MRI findings?
2. What is the radiological diagnosis?
3. Suggest 4 investigations for him.
4. Suggest 2 treatment options for this patient.