

Length and Depth of the Central Sulcus: A Postmortem Study

Kanij Fatema¹, Shamim Ara², Mushfika Rahman³, Halima Afroz³,
Anjuman Ara Sultana⁵, Dipali Rani Pal⁶

Abstract

Context: The central sulcus, which is located between the primary motor and primary somatic sensory cortex is an important structure and landmark of the cerebral hemisphere. Morphology of the central sulcus varies with age, sex, manual skill, handedness and in many diseases. This study is carried out to establish a normal standard in different age groups in length and depth of the central sulcus.

Materials and Methods: A cross-sectional, analytical type of study was conducted in the department of Anatomy, Dhaka Medical College, on one hundred and forty (140) on human cerebral hemispheres. The samples were divided into four different age groups i.e. Group A (20-29 years), Group B (30-39 years), Group C (40-49 years) and Group D (50-59 years). All the samples were studied morphologically.

Results: The mean length of central sulcus was 102.89 ± 3.55 mm to 96.83 ± 3.92 mm in male and 98.00 ± 5.17 mm to 96.29 ± 2.56 mm in female. Depth of the central sulcus was 20.02 ± 2.41 mm to 21.50 ± 2.21 mm in male and 20.50 ± 2.57 mm to 21.36 ± 1.87 mm in female. The difference in mean length of the right central sulcus between male and female was statistically significant in group A ($p < 0.05$) and B ($p < 0.05$). The difference in mean depth of the central sulcus between male and female was not statistically significant in any age groups. No significant difference was found between right and left hemisphere for both length and depth of the central sulcus. The difference in mean length and depth of the central sulcus between different age groups for both left and right hemisphere was not statistically significant in any age group.

Conclusion: The length and depth of the central sulcus showed gradual decreasing values with advancing age.

Key words: Central sulcus, length, depth.

Introduction:

Context: In human highest level of nervous function is localized in cerebral cortex. The cerebral cortex contains the primary sensory and motor areas as well as multiple association areas. These specific

areas of the cerebral cortex are concerned with specific parts of the body with specific types of input and with specific types of activities. The cerebral cortex is an extremely large memory storehouse. Without the cerebral cortex, the functions of the lower brain centers are often imprecise. The vast storehouse of cortical information usually converts these functions to determinative and precise operations¹. Surfaces of cerebral hemisphere are moulded into a number of gyri separated by sulci. Sulci and gyri provide a natural topographic partition of the cortical anatomy. The junctional zones between adjacent functional fields frequently run along the bed of major or minor cortical sulci. Tremendous variability in size, shape and configuration of cortical gyri and sulci has been well

1. Assistant Professor, Department of Anatomy, Jahurul Islam Medical College, Bajitpur, Kishoreganj.
2. Professor & Head, Department of Anatomy, Dhaka Medical College, Dhaka.
3. Assistant Professor, Department of Anatomy, Dr. Sirajul Islam Medical College, Dhaka.
4. Assistant Professor, Department of Anatomy, Green Life Medical College, Dhaka.
5. Lecturer, Department of Anatomy, Shaheed Suhrawardy Medical College, Dhaka
6. Associate Professor & Head, Department of Anatomy, Jahurul Islam Medical College, Bajitpur, Kishoreganj.

Correspondence: Dr. Kanij Fatema

demonstrated in different study². The central sulcus is an important structure and landmark of the cerebral hemisphere. Precentral gyrus forms the anterior bank of the central sulcus, corresponds to the primary motor cortex and the postcentral gyrus forms the posterior bank of the central sulcus, corresponds to the primary somatosensory area³. The central sulcus is divided into upper, middle and lower third by two genu. Upper third inclines downwards and slightly backward, the middle third bends suddenly forward and downwards and the inferior third proceeds very nearly vertically downwards⁴. Sulcal depth decreases with age. The average sulcal depth decreases at a rate of about 0.4 mm/decade⁵. Depth of central sulcus varies with manual skill and handedness. Right handers have a significantly deeper central sulcus on left hemisphere². Sulcal depth decreases with disease progression from controls to mild cognitive impairment and mild cognitive impairment to Alzheimer's disease⁶. Reduction in sulcal depth was found in CADASIL (autosomal dominant arteriopathy with subcortical infarcts and leukoencephalopathy) which is independent of age⁷. Some degenerative diseases have prominent involvement of cerebral cortex such as Alzheimer's disease which is the most common cause of dementia in the elderly⁸ and 7th leading cause of death in USA⁹. Sulci and gyri are the natural routes to deep brain structures in certain neurosurgical procedures. Precise knowledge about morphometry of sulci is essential for surgical planning of deep brain structures and has a great importance in diagnosis and management of diseases of cerebral cortex.

Materials and methods:

Materials: The present study was performed on postmortem cerebral hemispheres of 70 (seventy) Bangladeshi people of different age groups. Total 140 cerebral hemispheres were taken from these cadavers. Among them lowest age was 22 years in both sexes and highest age was 58 years in male and 48 years in female.

The samples were collected from the unclaimed dead bodies that were under examination in the Department of Forensic Medicine, Dhaka Medical

College, Dhaka from February 2010 to December 2010.

Preservation of brains:

After collection of whole brain, 100 ml of 40% formaldehyde solution was injected by using a 50 cc syringe into the brain through the surfaces (superolateral and inferior surfaces). Then it was preserved in 40% formaldehyde solution (Origin - Germany) for 15 days.

Procedure of collection of cerebral hemisphere from preserved brain

After fixation of the whole of the human brain, cerebral hemispheres were collected by the following steps. The brainstem was sectioned at the level of the cerebral peduncle and cerebral hemispheres were separated by a midline sagittal section. Then meninges and blood vessels of cerebral hemisphere were carefully removed.

Methods:

Grouping of the samples:

The samples were divided into four different age groups i.e. Group A (20-29 years), Group B (30-39 years), Group C (40-49 years) and Group D (50-59 years). All the samples were studied morphologically.

For convenience of description, in relation to age, the collected samples were divided into four groups (according to Magnotta et al¹⁰).

Table - I
Grouping of the samples of the present study (n = 70).

Group	Age in years	Number of samples	
		Male	Female
A	20-29	09	09
B	30-39	18	10
C	40-49	11	07
D	50-59	06	00

Measurement of length of central sulcus:

Length of central sulcus was measured from its superior end to inferior end by placing a metallic

wire along the course of central sulcus (Fig.-2) and then the wire was placed on metallic scale graduated in cm. Then the length in cm was converted into mm multiplying by 10.




Fig.-1: Sulcal depth was calculated as the distance between superficial and deep ends of the sulcus¹¹.

Measurement of depth of central sulcus:

Depth of central sulcus was obtained by measuring distance between superficial end and deep end of the central sulcus(Fig.-1). It was measured with the help of a wooden stick and a digital slide calipers in mm (Fig.-3). The central sulcus is divided into upper, middle and lower third by two genua. Measurements were taken at the middle of the upper, middle and lower third of the central sulcus and the average result was noted down.

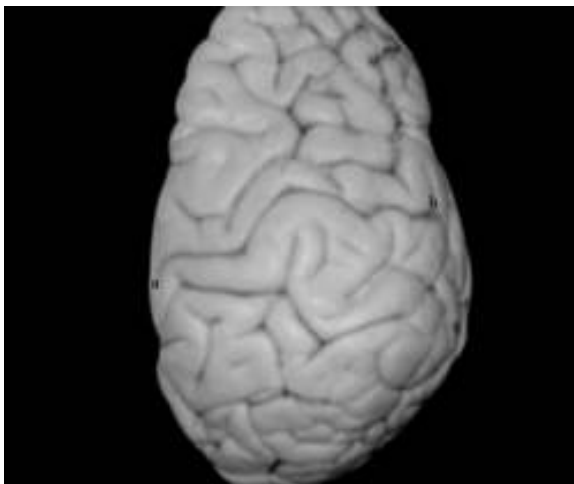


Fig.-2: Photograph of measurement of length of the central sulcus by placing a metallic wire (a – superior end of central sulcus, b – inferior end of central sulcus).

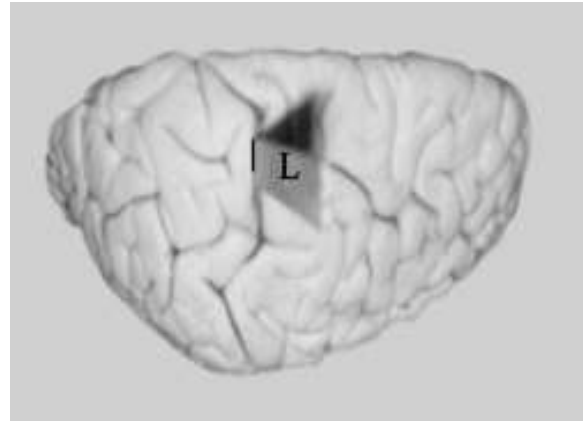


Fig.- 3 Photograph of measurement of the depth of the central sulcus by using a wooden stick (L - indicates wooden stick).

Ethical clearance

The study was approved by Ethical Review Committee of Dhaka Medical College, Dhaka

Results:

Results are shown in the Table–II, Table–III, Fig.-4, and Fig.- 5.

Length of left and right central sulci: The results are expressed in Table-II, Table–III and

Fig.-4. The difference in mean length of the right central sulcus between male and female was statistically significant in group A ($p < 0.05$), B ($p < 0.05$). The highest mean \pm SD was found in group A and the lowest one in group D. The difference in mean length between left and right central sulci was not statistically significant in any age group. The difference in mean length of central sulcus for both left and right hemisphere in different age groups was not statistically significant.

Depth of left and right central sulci: The results are expressed in Table-IV, Table –V. The difference in mean depth of the central sulcus between male and female was not statistically significant in any age groups. The highest mean was found in group A and the lowest one in group D. The difference in mean depth between left and right central sulci was not statistically significant in any age group. Significant difference was not observed in mean depth between different age groups.

Table –II
Length of left and right central sulci in male and female in different age groups

Groups	Length of central sulcus in mm			
	Left	p value	Right	p value
Group A				
Male (9)	101.56 ± 3.17 (97.00-108.00)	>0.05 ^{ns}	102.89 ± 3.55 (99.00-110.00)	<0.05*
Female (9)	98.00 ± 5.17 (86.00-105.00)		97.56 ± 4.25 (88.00-103.00)	
Group B				
Male (18)	99.89 ± 4.56 (90.00-106.00)	>0.10 ^{ns}	101.89 ± 4.81 (90.00-109.00)	<0.05*
Female (10)	97.10 ± 3.60 (92.00-103.00)		97.30 ± 4.40 (92.00-104.00)	
Group C				
Male (11)	99.00 ± 4.98 (88.00-106.00)	>0.10 ^{ns}	99.18 ± 5.62 (89.00-106.00)	>0.10 ^{ns}
Female (7)	96.29 ± 2.56 (93.00-100.00)		96.43 ± 2.57 (92.00-100.00)	
Group D				
Male (6)	96.83 ± 3.92 (90.00-102.00)		97.67 ± 3.33 (94.00-103.00)	

Data was expressed as Mean±SD. Figures in parentheses indicate range. Comparison between sex by unpaired Student's t test.

ns = not significant, * = significant at d"0.05.

Group A: Age 20-29 years

Group B: Age 30-39 years

Group C: Age 40-49 years

Group D: Age 50-59 years

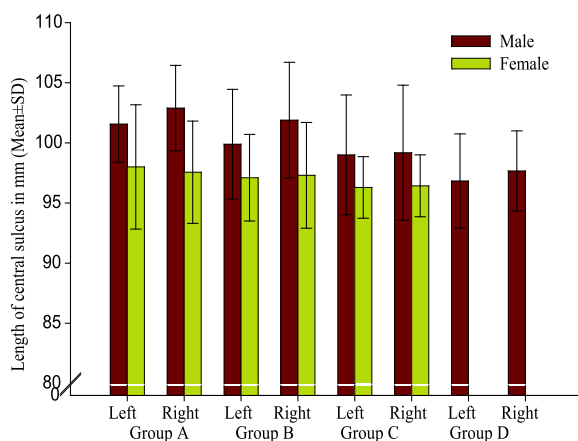


Fig.-4 Length of left and right central sulci in male and female in different age groups

Table –III
Depth of left and right central sulci in male and female in different age groups

Groups	Depth of central sulcus in mm			
	Left	p value	Right	p value
Group A				
Male (9)	21.35 ± 2.23 (18.02-25.10)	>0.50 ^{ns}	21.50 ± 2.21 (18.24-25.24)	>0.50 ^{ns}
Female (9)	21.32 ± 1.62 (18.50-24.14)		21.36 ± 1.87 (18.82-24.50)	
Group B				
Male (18)	21.07 ± 1.74 (18.02-24.12)	>0.50 ^{ns}	21.25 ± 2.10 (17.54-24.20)	>0.50 ^{ns}
Female (10)	21.01 ± 2.23 (17.58-25.20)		21.21 ± 1.94 (18.32-24.38)	
Group C				
Male (11)	20.75 ± 1.79 (17.20-22.64)	>0.50 ^{ns}	20.92 ± 1.59 (18.84-23.26)	>0.50 ^{ns}
Female (7)	20.67 ± 2.75 (16.84-24.30)		20.50 ± 2.57 (16.24-23.68)	
Group D				
Male (6)	20.16 ± 2.71 (16.24-23.84)		20.02 ± 2.41 (16.94-23.64)	

Data was expressed as Mean±SD. Figures in parentheses indicate range. Comparison between sex done by unpaired Student's t test.

ns = not significant.

Group A: Age 20-29 years

Group B: Age 30-39 years

Group C: Age 40-49 years

Group D: Age 50-59 years

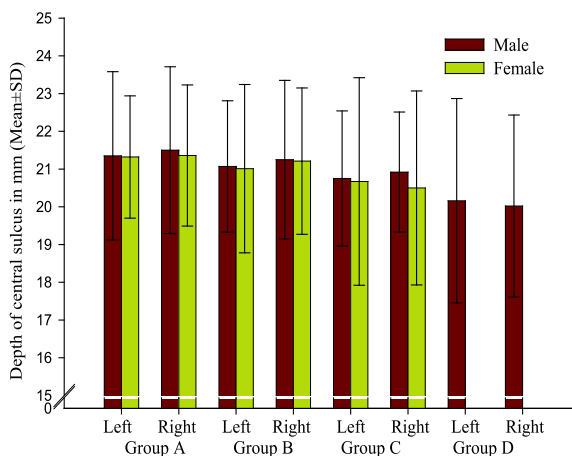


Fig.- 5 Depth of left and right central sulci of male and female in different age groups

Discussion:

Length of the central sulcus:

The mean±SD length of the central sulci of the left and right cerebral hemispheres were 101.56±3.17 mm and 102.89±3.55 mm in group A, 99.89±4.56 mm and 101.89±4.81 mm in group B, 99.00±4.98 mm and 99.18±5.62 mm in group C and 96.83±3.92 mm and 97.67±3.33 mm in group D respectively in male. The mean±SD length of the central sulci of the left and right cerebral hemisphere were 98.00±5.17 mm and 97.56±4.25 mm in group A, 97.10±3.60 mm and 97.30±4.40 mm in group B, 96.29±2.56 mm and 96.43±2.57 mm in group C respectively in female.

Crossman¹¹ stated that central sulcus runs sinuously downwards and forwards for 8-10 cm to end a little above the posterior ramus of the lateral sulcus. Brown¹² stated that the central sulcus is more than 80 mm long. Sun et al¹³ stated that average length of the central sulcus was 93.28 mm and 84.59 mm for left and right side respectively and average length of the central sulcus was significantly larger in males than in females in left hemisphere. Kline et al¹⁴ noted that range of length of central sulcus was 70 to 125 mm in autopsied brain and average length was 94 mm. The findings of the present study was higher than the findings of Brown¹² but has got similarity with the findings of Crossman¹¹, Sun et al¹³, Kline et al¹⁴. This similarity could not be explained because the researcher's did not mention the race, ethnics, nationality and age of the study population.

The present study recorded that the length of the central sulcus gradually declined with age and there is no available literature for comparison with age. The present study also revealed that average length of the central sulcus was larger in males than in females in different age groups and this finding agreed with the finding of Sun et al¹³.

The mean±SD depth of left and right central sulci were 21.35±2.23 mm and 21.50±2.21 mm in group A, 21.07±1.74 mm and 21.25±2.10 mm in group B, 20.75±1.79 mm and 20.92±1.59 mm in group C and 20.16±2.71 mm and 20.02±2.41 mm in group D respectively in male. The mean±SD depth of left and right central were 21.32±1.62 mm and

21.36±1.87 mm in group A, 21.01±2.23 mm and 21.21±1.94 mm in group B, 20.67±2.75 mm and 20.50±2.57 mm in group C respectively in female.

An MRI study done by Davatzikos et al¹⁵ on 22 men of average age 65.6±2.8 years and 20 women of average age 66.6±2.8 years and found that average depth of central sulcus was 20.6 and 21.07 mm in men and 20.04 and 20.94 mm in female for left and right respectively. Kochunov et al⁵ stated that sulcal depth decreased with age which was similar to the findings of the present study. An MRI study done on 27 men and 28 women over a wide age range (21-89) by Cykowsky et al¹⁶ revealed that mean depth of central sulcus was 16.6±1.3 mm for left and 16.4±1.2 mm for right hemisphere. The findings of Cykowsky et al¹⁶ were lower than the present study. This difference may be due to difference in method of study.

Conclusion:

In the present study length of the central sulcus was longer in male than in female and gradually decreased with advancing age. No significant difference was found in depth of the central sulcus between male and female and depth of the central sulcus decreased with advancing age.

References:

1. Guyton AC, Hall JE. eds. Textbook of medical physiology. 11th ed. New Delhi: Elsevier 2006: 589-91, 685-88, 715-23.
2. Zilles K, Schleicher A, Langemann C, Amunts K, Monosun P, Gallagher NP, et al. Quantitative analysis of sulci in the human cerebral cortex: development, regional heterogeneity, gender difference, asymmetry, intersubject variability and cortical architecture. *Human Brain Mapping* 1997; 5: 218-21.
3. Parent A ed. Regional anatomy of the brain. In: Carpenter's human neuroanatomy. 9th ed. Baltimore: Williams and Wilkins 1996: 31.
4. Cunningham DJ. 1892 cited by Cykowski DM, Coulon O, Kochunov PV, Amunts K, Lanchaster JL, Angela RL, et al. The central sulcus: an observer-independent characterization of sulcal landmarks and depth asymmetry. *Cer. Cortex* 2007; 224: 1-11.

5. Kochunov P, Mangin JF, Thomas C, Lancaster J, Thompson P, Riviere D, et al. Age-related morphology trends of cortical sulci. *Human Brain Mapping* 2005; 26: 210-20.
6. Im K, Lee JM, Seo WS, Kim SH, Kim SI, Na DL. The Sulcal morphology changes and their relationship with cortical thickness and gyral white matter volume in mild cognitive impairment and Alzheimer's disease. *NeuroImage* 2008; 103-13.
7. Jouvent E, Mangin JF, Porcher R, Viswanathan A, Sullivan MO, Guichard JP, et al. Cortical changes in cerebral small vessel diseases: a 3D MRI study of cortical morphology in CADASIL. *Brain* 2008; 131: 2201-08.
8. Frosch MP, Anthony CD, Girolami. UD eds. The central nervous system. In: Kumar V, Abbas AK, Fausto N. eds. *Robbins & Cortan pathologic basis of disease*. 7th ed. Newdelhi: Elsevier 2004: 1386.
9. Swierzewski SJ. Alzheimer's disease overview, Brain anatomy collected from <http://www.neurologychannel.com/alzheimers/index.shtml> 2007.
10. Magnotta VA, Andearson NC, Schultz SK, Harris G, Cizadlo Ted, Heckel D, et al. Quantitative in vivo measurement of gyrification in the human brain: changes associated with aging. *Cerebral Cortex* 1999; 9: 151-60.
11. Crossman AR. ed. Cerebral hemisphere. In: Standring S, Ellis H, Heally JC, Johnson D, Williams A, Collins P, et al. eds. *Gray's Anatomy: The anatomical basis of clinical practice*. 39th ed. Edinburgh: Elsevier Churchill Livingstone 2005: 387-88.
12. Brown M.W. Central nervous system. In Berkovitz B.K. V, Moxaham BJ. *A textbook of head and neck anatomy*. Barcelona: Year book medical publishers 1988: 538.
13. Sun B, Ge H, Tang Y, Fan L, Lin X, Yu T, et al. Sexual dimorphism asymmetry of central sulcus. *FASEB J*. 2009; 23: 474-72.
14. Kline AD, Smith DA, Hurdal MK. Comparison of human cortical surface reconstruction from magnetic resonance imaging data collected from <http://www.math.fsu.edu/mhurdul/posters/hbm05surfcomp.2010>.
15. Davatzikos C, Bryan RN. Morphometric analysis of cortical sulci using parametric ribbons: a study of the central sulcus. *J Comput Assist Tomogr* 2002; 26(2): 298-307.
16. Cykowski DM, Coulon O, Kochunov PV, Amunts K, Lanchaster JL, Angela RL, et al. The central sulcus: an observer-independent characterization of sulcal landmarks and depth asymmetry. *Cerebral Cortex* 2007; 224: 1-11.