

Variations in the Location of Basilar Artery on Ventral Surface of Pons

Anjuman Ara Sultana¹, Shamim Ara², Mushfika Rahman³, Halima Afroz⁴, Rahanur Akter⁵, Farhana Akter⁶, Kanij Fatema⁷

Abstract

Context: Basilar artery is formed by the union of right & left vertebral arteries at the lower border of pons / mid medullary level which courses upward along 'Basilar groove' on the anterior surface of pons & supplies the anatomical structures within the posterior cranial fossa of brain. The Circle of Willis is the principal arterial anastomotic trunk of brain formed by anastomosis between the branches of internal carotid arteries and terminal branch of basilar artery. It is responsible for collateral circulation of brain, specially of old people - who have reduced blood supply to brain due to senile arteriosclerosis. Cerebrovascular diseases due to basilar artery is more common in men than women. Anatomy of basilar artery and its branches are very complex and variable. So, detailed morphological knowledge is essential for proper diagnosis and treatment of neurological disorder. To identify whether there is any variations in the location of basilar artery in relation to basilar groove on the ventral surface of pons .

Materials and Methods: A cross-sectional descriptive type of study was carried out in the Department of Anatomy, Dhaka Medical College, Dhaka, from January 2010 to December 2010. Seventy(70) postmortem basilar arteries were collected from unclaimed dead bodies that were under examination in the morgue of Department of Forensic medicine, Dhaka Medical College Dhaka. The study was approved by the Ethical Review Committee (ERC) of Dhaka Medical College. The position of basilar artery in all the samples were either in the midline, right to midline or left to midline. Formalin fixed brain was washed with plain tap water to remove excess formalin and was kept on metallic tray. Location of basilar artery was examined carefully by hand magnifying glass and noted.

Results: In the present study, location of basilar artery was found at midline in 70% brain, right to midline in 17%, left to midline in 13%.

Conclusion: Further studies in large scale for preparing a database of anatomy of basilar artery are recommended.

Key Words: Location, basilar artery, pons.

Introduction

Basilar artery is one of the main arteries that supplies the posterior portion of brain, the area

1. Assistant Professor. Department of Anatomy, Shaheed Suhrawardy Medical College.
2. Professor & Head, Department of Anatomy, Dhaka Medical College, Dhaka-1000.
3. Associate Professor, Department of Anatomy, Dr. Sirajul Islam Medical College, Dhaka.
4. Associate Professor. Department of Anatomy, Green Life Medical College, Dhaka-1205.
5. Lecturer, Department of Anatomy, Shaheed Suhrawardy Medical College.
6. Assistant Professor, Department of Anatomy, Dhaka National Medical College, Dhaka.
7. Assistant Professor, Department of Anatomy, Jahurul Islam Medical College.

Correspondence : Dr. Anjuman Ara Sultana

supplied by basilar artery is also called posterior cerebral circulation^{1,2}. Basilar artery is the most important artery in the posterior circulation³. Basilar artery is formed by the union of right and left vertebral arteries at the lower border of pons or mid medullary level^{1,4 & 5}. Then it courses upward along 'basilar groove' on the anterior surface of the pons, and it ends at the upper border of pons by bifurcating into two posterior cerebral arteries⁶. The posterior cerebral artery, branch of basilar artery completes an arterial polygon called the 'circle of Willis', which is the principal arterial anastomotic trunk of brain¹. Normally little blood flows around this circle, if one major vessel occludes the communicating arteries may allow

critically important anastomotic flow and prevent neurological damage⁷. The most frequent and severe atherosclerotic (degenerative proliferative) change occur in upper and lower part of basilar artery and the first part of the posterior cerebral artery. Severe narrowing of vessels sufficient to cause vascular insufficiency occurred in 2% of case as age 30-40 years and in as many as 6-8% in patient from age 60-70 years¹. Anatomical variation occasionally occurs in basilar artery and its branch. Most frequent anatomical variation of basilar artery is short segments of duplication or island formation. The superior cerebral artery may be multiple⁸. The proximal and mid basilar arteries are the most common sites of stenosis and most often cause of infarction in pons⁹. Aneurysm often develops at the site of branching of basilar artery and near the arterial circle and they can rupture or leak causing subarachnoid hemorrhage¹⁰. Cerebrovascular disease was found 22% in the year 2004¹¹ in Mymensingh Medical College Hospital. Stroke due to basilar artery comprises approximately 10% to 15% of all stroke, more common in man than woman. Structures commonly affected by basilar artery infarction are brain stem (60%), cerebellum (50%). Basilar artery related clinical condition such as posterior circulation stroke, migraine, aneurysm, atherosclerotic changes are very common throughout the world. Anatomy of the basilar artery and its branches in Bangladeshi people are necessary for neurosurgeon, neurologist for proper diagnosis and treatment of cerebrovascular disease, aneurysm, tumour, epilepsy, migraine and other form of vascular anomalies.

Materials & Methods

Materials

The present study was performed on 70 post mortem basilar arteries collected from unclaimed dead bodies between 16-60 years of age that were under examination in the morgue of Department of Forensic Medicine, Dhaka Medical College, Dhaka, Dhaka from January 2010 to. December 2010. The study was approved by the Ethical Review Committee (ERC) of Dhaka Medical College. After legal formalities and requisite permission from the Department of Forensic Medicine. The whole brains were collected within 24-36 hours of death. Soon

after collection, each sample was gently washed with tap water on a dissection tray. Blood and blood clots were removed. After collection of whole brain, 100ml of 40% formaldehyde solution was injected by using a 50cc syringe into the brain through the surfaces (superolateral and inferior surfaces). Then it was preserved in 40% formaldehyde solution for 15 days. After 15 days the present study was made with these fixed specimens.

Methods

Place and duration of study:

This study was carried out in the Department of Anatomy, Dhaka Medical College, Dhaka, Bangladesh, from January 2010 to December 2010. During collection of the samples appropriate age and the cause of death were noted from morgue's record book and the samples were tagged bearing code numbers for subsequent identification.

Observation of location of basilar artery on ventral surface of pons

Formalin fixed brain was washed with plain tap water to remove excess formalin and was kept on metallic tray. Location of basilar artery on the ventral surface of pons was examined carefully by hand magnifying glass and noted.

Ethical Clearance

This study was approved by this Ethical Review Committee of Dhaka Medical College, Dhaka.

Results

Results are shown in the Table –I, Fig-1

Table-I
Location of basilar artery on sulcus basilaris.

At midline	Right to midline No. (%)	Left to midline No. (%)
49 (70%)	12 (17%)	9 (13%)

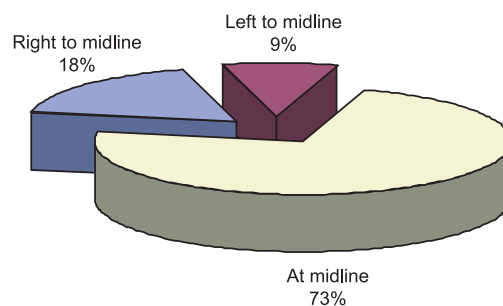


Fig.-1: Location of basilar artery on sulcus basilaris

Discussion

In the present study, location of basilar artery at sulcus basilaris was found at midline 70%, right to midline 17%, left to midline 13%. Rogers¹², Kiernan¹³, Parena¹⁴, Nolte⁷, Pai et al.⁶, Snell⁵, Crossman⁴ reported basilar artery located in mid line of pons, which was similar to the present study. All these studies are similar regarding the location of basilar artery on ventral surface of pons. But more specific locations of basilar artery, such as right or left to midline could not be compared, as other studies were not available regarding these locations.

Conclusion

In present study, commonest location of basilar artery at sulcus basilaris was found at midline 70% (49), right to midline 17% (12), left to midline 13% (9). Further studies to find out the cause and functional / clinical correlations of this variation are recommended.

References

1. Chusid JG. Disorder due to vascular disease of the central nervous system. Correlative neuroanatomy & functional neurology. USA. Lange Medical Publications 1985: 338-46
2. Bartomirt and Bogguslasky. Vascular disorder of the posterior circulation- an anatomico-clinical overview. *Acenr.* 2004; 4(2): 7-9.
3. Flores SC. and Muengtaweepongsa S. Basilar artery- Thromboses. 2009; available from: <http://emedicine.medscape.com/articel/1161044-overview>.
4. Crossman AR. ed. Neuroanatomy. In: Standring S, Ellis H, Heally JC, Johnson D, Williams A, Collins P, et al. eds. Gray's Anatomy: The anatomical basis of clinical practice. 39th ed. Edinburgh: Elsevier Churchill Livingstone 2005: 298-301.
5. Snell RS. The blood supply of the brain and spinal cord. in: Clinical Neuroanatomy for medical student. 8th ed. Philadelphia: Lippincott Williams and Wilkins 2008: 469-97.
6. Pai BS, Varma RG, Kulkarni RN, Nirmala S, L. Microsurgical anatomy of posterior circulation. *Neurol India* 2007; 55(1): 361-41.
7. Nolte J. Blood supply of the brain. In: The human Brain. 5th ed. St. Louis: Mosby 2002: 119-46.
8. Berkovitz BKB, Moxham BJ. A textbook of head and neck anatomy. 1st ed. Barcelona: Wolfe Publishing Ltd. 1988: 577-80.
9. Woolfenden A, Tong D, Norbash A, Ali A, et al. Basilar artery stenosis- clinical and neuroradiographic feature. *Journal of stroke and cerebrovascular disease* 2009; 9(2): 57-63.
10. Tulleken C A F. and Luiten L F B. The basilar artery bifurcation: Microscopical anatomy. *Acta Neurochir.* 2005;85:50-55.
11. Ahmed S, Hossain S, Rahman MK. Disease Pattern at Neurology Outpatient Department of Mymensingh Medical College Hospital, Mymensingh-One Year Study in the Year 2002. *Bangladesh Journal of Neuroscience* 2006; 22(2): 89-92.
12. Rogers AW, Jacob S. The blood supply of head and neck. A textbook of anatomy. 1st ed. Edinburgh: Churchill Livingstone 1992. 597-99.
13. Kiernan JA. Blood supply of the central nervous system. In: Barr's the human nervous system: an anatomical viewpoint. 7th ed. Philadelphia: Lippincott-Raven 1998: 801-11.
14. Parena. Blood supply of the central nervous system. *Carpenter's human neuro anatomy.* 9th edition USA: Williams & Wilkins 1996: 113-17.