

Length and Width of The Foramen Magnum of Dry Ossified Human Occipital Bone

Kanetarin Kashem¹, Shamim Ara², Zakia Akhter³, Samira Hossain⁴

Abstract:

Context : Some important vital neuroanatomical structures such as cervical part of spinal cord, vertebral arteries, nerves and meninges passes through the foramen magnum. Morphometric data of foramen magnum is essential for anthropologists and neurosurgeons for various surgical diagnosis and treatment.

Materials and Methods : A cross-sectional analytic type of study was conducted in the Department of Anatomy, Dhaka Medical College, Dhaka from January 2011 to December 2011. The length and width of foramen magnum were measured with the help of digital slide calipers.

Results : The mean \pm SD length of foramen magnum was greater in male than mean \pm SD length of foramen magnum in female ($p < 0.001$). The mean \pm SD width of foramen magnum was greater in male than mean \pm SD width of foramen magnum in female ($p < 0.001$).

Key words: Length and width of foramen magnum, occipital bone.

Introduction:

The vertebrate skull is the most modified part of axial skeleton¹. The foramen magnum is the largest foramen of skull. This is a wide communication between the posterior cranial fossa and vertebral canal. The great vital important neuroanatomical structures such as the medulla oblongata, meninges, accessory spinal nerve, dural sinuses, vertebral arteries, anterior and posterior spinal arteries pass through it.

Since all the bone elements are well palpated and visible during various radiological examinations, they are important landmarks for neurosurgeons, radiologists, other physicians and anthropologists.

This foramen magnum is also related to a number of pathological conditions including chiari malformations, various tumors and occipital dysplasia's². Meningioma represent 14.3% to 19% of all intra cranial tumors. Among all meningioma tumors 1.8 to 3.2% arise at foramen magnum³. The foramen magnum meningioma are complicated tumors and require special consideration. Surgical treatment of meningioma needs perfect anatomical knowledge of foramen magnum. Occipital bone is used in bone grafting for atlanto axial fusion, for this operation a small craniectomy is performed near foramen magnum⁴.

So studies on the morphological features of the foramen magnum, with its length and width have particularly facilitates the surgeons to improve the surgical conditions such as tumor resection, achondroplasia and cerebral herniation, which make such procedures more successful⁵.

The present study was undertaken to find out morphometric variation of the length and width of foramen magnum of occipital bone.

-
1. Assistant Professor, Department of Anatomy, Dhaka Central International Medical College, Dhaka.
 2. Professor and Head, Department of Anatomy, Dhaka Medical College, Dhaka.
 3. Associate Professor and Head, Department of Anatomy, Dhaka Central International Medical College, Dhaka.
 4. Associate Professor, Department of Anatomy, Dhaka Central International Medical College, Dhaka.

Correspondence: Dr. Kanetarin Kashem

Materials and Methods:

One hundred and fifty six dry ossified human occipital bones of both sexes (82 male, 74 female) were collected from the Anatomy Department of Dhaka Medical College and other government and non- government medical colleges in Dhaka city. Sex determination of the collected occipital bones were done by discriminant function analysis according to Gapert⁶.

To measure the length midpoint of anterior margin basion and midpoint of posterior margin opisthion of the foramen magnum were determined by a metallic scale. Then the two points were marked by a pencil. The reading was recorded with the help of digital slide calipers in mm. (Fig 1).

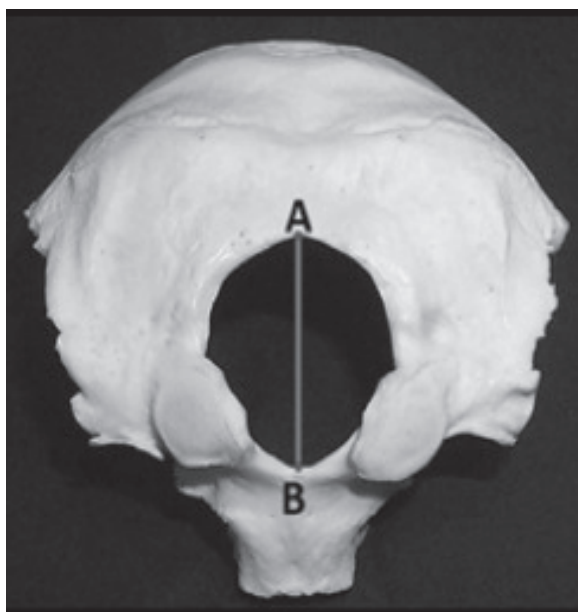


Fig.-1: Photograph showing AB line which represents the length of foramen magnum. (A is opisthion and B is basion)

To measure the width, midpoint of left margin and midpoint of right margin of the foramen magnum were determined by a metallic scale. Then the two points were marked by a pencil. The reading was recorded with the help of digital slide calipers in mm. (Fig 2). All the statistical analysis was done by using the SPSS software package for windows version 17.0.

Ethical Clearance:

This study was approved by the Ethical Review Committee of Dhaka Medical College, Dhaka.

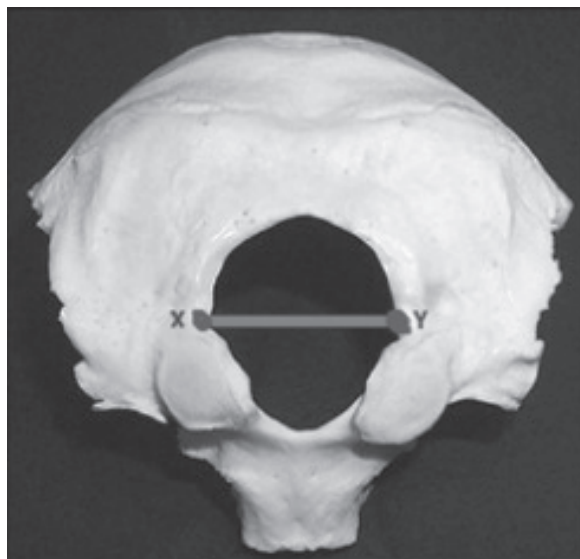


Fig.--2 : Photograph showing XY line which represents the width of foramen magnum (X is the point of greatest lateral curvature of left margin and Y is the point of greatest lateral curvature of right margin)

Results :

The results are shown in table I and figure 3

Table I
Length and width of foramen magnum in male and female.

Sex	Length (mm) Mean±SD	Width (mm) Mean±SD
Male (n=82)	36.34±1.06 (34.76 38.94)	30.18±1.53 (27.24 33.32)
Female (n=74)	33.07±2.00 (26.78 39.58)	28.69±1.97 (23.15 32.57)
<i>P value</i>	<0.001***	<0.001***

Figures in parentheses indicate range. Comparison between sex was done by unpaired Student's 't' test, *** = significant

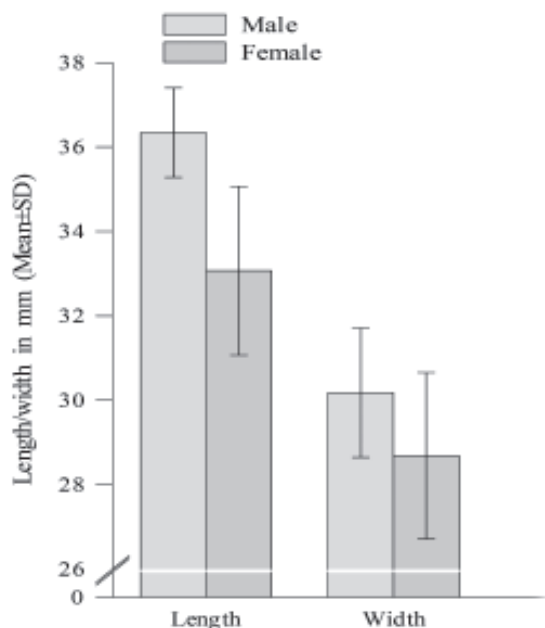


Fig.-3: Length and width of foramen magnum in male and female.

Discussion:

The mean length of foramen magnum in male was similar ($p > 0.10$) with the findings of Ukoha et al⁷ on Nigerian population, Olivier⁸ on French population, Erdil et al⁹ on Turkish population, Gapart⁶ on British population. However Murshed⁸ carried out a study on Turkish population. The findings of the study conducted by Murshed was greater ($p < 0.001$) than the findings of the present study in male. In case of female the mean length of the present study was similar ($p > 0.10$) with the findings of Erdil et al⁹ on Turkish population, Gapart⁶ on British population, Ukoha et al⁷ on Nigerian population. But the mean length was greater ($p < 0.001$) than the findings reported by Olivier⁸ on French population. In present study the mean \pm SD width of foramen magnum was greater ($p < 0.001$) in male than that of female. The mean width of foramen magnum both in male and female (36.34 ± 1.06 mm) was similar ($p > 0.10$) with the findings of Ukoha et al⁷ on Nigerian population,

Olivier⁸ on French population, Erdil et al⁹ on Turkish population, Gapart⁶ on British population.

But the findings of the study carried out by Murshed on Turkish population was significantly higher ($p < 0.001$) than the findings of both male and female value of the present study.

Conclusion:

In the present study the length and width of foramen magnum were found greater ($p < 0.01$) in male than that of female and were statistically significant. Further radiographic and computed tomographic study and measurement of different parameters of living occipital bone and comparison between the radiographic findings with the morphometric study of human dry ossified occipital bone are recommended.

References:

1. Standring S. Gray's Anatomy: The Anatomical Basis Of Clinical Practice. 40th ed. London. Churchill livingstone. 2008:710-12.
2. Burdan F, Szumio J, Walocha J, Klepacz L, Madej B, Dworzański W, et al. Morphology of the foramen magnum in young Eastern European adults. *Folia Morphologica*. 2012; 71(4):205–16.
3. Bruneau M, George B. Foramen magnum meningiomas: detailed surgical approaches and technical aspects at lariboisiere hospital and review of the literature. *Neurosurgical Review*. 2008; 31(1):19-33.
4. Sheehan JM, Jane JA. Occipital bone graft for atlantoaxial fusion. *Acta neurochirurgica*. 2000;142(6):661-66.
5. Aragao J A, Pereira R O, Moraes R Z, and Reis F P. Morphological types of Foramen Magnun. *Annual Research & Review in Biology*. 2014;4(9):1372-78.
6. Gapert R, Black S, Last J. Sex determination from the foramen magnum: discriminant function analysis an eighteenth and nineteenth century British sample.

- International Journal of Legal Medicine. 2009; 123: 25-31.
7. Ukoha U, Egwu O A, Okafor I J, Anyabolu AE, Ndukwe GU, Okpala I. Sexual dimorphism in the foramen magnum of Nigerian adult. International Journal of Biological and Medical Research. 2011;2(4):878-81.
 8. Olivier G. Biometry of the human occipital bone. Journal of Anatomy. 1975;120(3): 507-18.
 9. Erdil H F, Sabanciogullari V, Cimen M, Isik O. Morphometric analysis of the foramen magnum by computed tomography. Erciyes Medical Journal. 2010;32 (3):167-70.
 10. Murshed A K, Cicekcibasi A E, Tuncer I. Morphometric evaluation of the foramen magnum and variations in its shape: A study on computerized Tomographic images of normal adults. Turkish Journal of Medical Sciences. 2003; 33: 301-06.